

Fractional CO₂ laser treatment for vulvovaginal atrophy symptoms and vaginal rejuvenation in perimenopausal women

César Arroyo

HM Montepríncipe University
Hospital Laser Unit, Madrid, Spain

Background: This study investigated a novel fractional carbon dioxide (CO₂) laser for treatment of symptoms associated with vulvovaginal atrophy (VVA) in perimenopausal women.

Methods: The study included 21 perimenopausal women (mean age 45±7 years) treated three times by CO₂ laser resurfacing and coagulation of the vaginal canal tissue and mucosal tissue of the introitus. Vaginal health index (VHI) scores were computed by the investigator at baseline and follow-ups. Subjects reported on sexual function, satisfaction, and improvement with treatment. A visual analog scale was used to measure discomfort with treatment.

Results: Vaginal health and subject assessment of vaginal symptoms improved with successive treatments. At 12 weeks following the third treatment, 82% of the patients showed a statistically significant improvement in VHI ($P<0.05$). Additionally, 81% of subjects reported improvement in sexual gratification, 94% reported improvement in vaginal rejuvenation, and 100% reported satisfaction with treatment. VHI improvement remained significant at 6–8 months after treatments ($P<0.01$). Most patients (97%) reported no to mild discomfort with treatment. Responses were mild and transient following treatment, with itching being the most commonly reported (20%) side effect.

Conclusion: In this study, fractional CO₂ laser treatment was associated with improvement of vaginal health and amelioration of symptoms of VVA, resulting in improved sexual function in perimenopausal women. Treatment time was quick, and there was minimal discomfort associated with treatment. Investigation of clinical outcome in a larger study population is warranted.

Keywords: genitourinary syndrome of menopause, vaginal rejuvenation, stress urinary incontinence, collagen remodeling, sexual dysfunction, vulvovaginal atrophy

Introduction

Although the prevalence varies in early premenopausal to late postmenopausal women, vulvovaginal atrophy (VVA) is considered to be a common and underreported condition, with nearly 50% of postmenopausal women reporting symptoms.¹ Self-reported genital symptoms include dryness, irritation, soreness, and associated dyspareunia.^{1–3} According to the Vulvovaginal Atrophy Terminology Consensus Conference Panel, genitourinary syndrome of menopause (GSM) is a more medically accurate term for VVA and includes genital symptoms, as well as sexual symptoms of lack of lubrication, discomfort or pain, and impaired function and urinary symptoms of urgency, dysuria, and recurrent urinary tract infections.⁴ Clinical findings include the presence of pale and dry vulvovaginal mucosa with petechiae.

Thinning of the epithelial lining and loss of lubrication during intercourse contribute to dyspareunia and can have a detrimental effect on sexual gratification. As sexual

Correspondence: César Arroyo
HM Montepríncipe University Hospital
Laser Unit, C/Senda del Infante 28, 28035
Madrid, Spain
Email carroyoromo@gmail.com

health is an important aspect of overall health that changes over a woman's lifetime, problems in sexual health may adversely affect quality of life.⁵ Many women with sexual health concerns are not aware that the changes in genitourinary anatomy and physiology that occur with age can impact sexual functioning. Findings from the Real Women's Views on Treatment Options for Menopausal Vaginal Changes survey reported that these symptoms affected sexual satisfaction in 59% of women responding to the survey; in nearly one-fourth (23%) of respondents, these symptoms affected general temperament and general life enjoyment.⁶

Current therapeutic approaches include topical treatments and hormones. The North American Menopause Society (NAMS) updated its position statement in 2013 on the management of symptomatic GSM in postmenopausal women to conclude that non-hormonal therapies provide relief for mild symptoms, while estrogen therapy is the most effective treatment for moderate to severe symptoms.⁷ However, they further stated that endometrial safety has not been studied in long-term clinical studies, and there are insufficient data to confirm the safety of local estrogen in women with breast cancer. Therefore, NAMS noted that

Choice of therapy depends on the severity of symptoms, the effectiveness and safety of therapy for the individual patient, and patient preference.⁷

While non-hormonal vaginal moisturizers and lubricants can be safely used for GSM symptoms, they need to be used regularly for optimal effect.¹ Vaginal estrogen appears to relieve symptoms more effectively than non-hormonal gels. Systemic estrogen therapy is sometimes used; however, 10%–20% of women may have residual GSM symptoms even while taking systemic estrogen.⁸ Breast cancer treatment increases the prevalence of GSM symptoms, which negatively correlate with quality of life.⁹ Local estrogen treatment for this group of women remains controversial. Moreover, many women prefer not to use hormonal therapy due to side effects, such as worsening of the symptoms of urinary incontinence.¹⁰

Laser treatment is a novel non-hormonal treatment approach for GSM. The concept behind laser procedures to treat vulvovaginal conditions is to use a wavelength having high water absorption, such as the carbon dioxide (CO₂) laser (10,600 nm), to ablate and coagulate vaginal and vulvar tissues.¹¹ The Er:YAG laser also stimulates non-ablative photothermal effects by thermal diffusion to the vaginal walls.¹² A wound response is initiated due to the heating and results in tissue remodeling with neof ormation of collagen and elastic

fibers in atrophic skin.^{11,12} The muscle tone of the vagina is then restored by tightening the supportive structures of the vulvovaginal complex.¹³ CO₂ laser treatment has previously demonstrated significant improvement in GSM symptoms in postmenopausal women.^{11,14–16} Fractional CO₂ laser application has also been shown to restore the vaginal mucosa structure in postmenopausal, non-estrogenized women.¹⁷

In the published trials to date, only postmenopausal women have been studied,^{11–17} primarily with short-term follow-up of 12 weeks after treatment.^{11,13–15} As symptoms of VVA can occur at any time in a woman's life cycle, this study investigated the effects of fractional CO₂ laser in perimenopausal women treated by resurfacing and coagulation of the vaginal canal tissues and mucosal tissues of the introitus. Clinical outcome was evaluated at 12 weeks and longer term at 6 months after the final treatment.

Methods

Study design

This prospective study was conducted at HM Montepíncipe University Hospital in Madrid, Spain. Study participants included perimenopausal women presenting to the clinic with irregular menstrual patterns and symptoms of VVA (vaginal dryness, irritation, soreness, or dyspareunia associated with this condition). Study exclusion were discontinuation of menstruation for 12 consecutive months; pregnancy; previous vaginal reconstructive surgery or treatment for vaginal tightening within the past 12 months; acute or recurrent urinary tract infections; active genital infections; undiagnosed vaginal bleeding; and suffering from hormonal imbalance or any serious disease or chronic condition that could interfere with study compliance. The study protocol was approved by the Hospital Ethics Committee, and informed written consent was obtained from study subjects.

Study protocol

Perimenopausal women were treated extravaginally and internally with a fractional CO₂ laser (CO₂RE Intima; Syneron Candela, Wayland, MA, USA). Treatment of the vaginal canal was performed using the following settings: square pattern and Deep Mode with the internal handpiece, fractional density of 4%–5%, and energy level of 40–55 mJ. The speculum cage was introduced into the introitus, and the handpiece was inserted to the interior edge of the treatment site (up to 11 cm in the vaginal canal). Several drops of baby oil were used for more comfortable insertion into the introitus. The handpiece was positioned with contact to the vaginal wall and pulses were applied at each 1 cm marking

and then retracted, until a 4–5 cm depth. The handpiece was rotated 45°–90° and reinserted until 4–8 pulses were applied at each depth.

External treatments were performed with a separate handpiece, using Deep Mode and the hexagon or square pattern. Single passes, without overlapping, were administered at the energy level of 40 mJ and 3%–4% fractional density. Subjects received three treatments at 3- to 4-week intervals. The procedure was performed in the outpatient clinic and did not require analgesia/anesthesia. Patients were recommended to avoid coital sexual activity and tampon use for at least 7 days after treatment.

The primary objective in the study was to evaluate change in vaginal health index (VHI) at 12 weeks after the final treatment. Secondary objectives included change in VHI at 24 weeks after the final treatment and subject assessments of changes in VVA symptoms and sexual gratification.

Data assessments

The VHI, a quantitative assessment of vaginal health, was performed by the investigator to assess changes in vaginal elasticity, fluid volume, vaginal pH level, and epithelial integrity and moisture after treatment and at follow-ups after the final treatment (6, 12, and 24 weeks) compared to baseline. A visual analog scale was used to measure discomfort associated with treatment. A 5-point Likert scale questionnaire was completed by subjects to report on sexual function, satisfaction, and improvement following treatment. Differences between baseline and follow-up VHI scores were analyzed with Wilcoxon signed-rank test for paired data. Statistical significance was set at $P < 0.05$.

Results

The study included 21 perimenopausal women (mean age 45 ± 7 years) treated both internally and externally at three sessions (1 of the 21 subjects was treated just once) with fractional CO₂ laser. Patients were assessed following each treatment and at the 12-week follow-up after the final treatment. Sixteen patients returned for a long-term follow-up visit at 6–8 months (24-week follow-up) after the final treatment.

Investigator qualitative VHI assessments

At baseline, the mean VHI score in the perimenopausal study population was 17.7 ± 1.6 (range 15–20). Vaginal health improved significantly ($P < 0.01$, Wilcoxon signed-rank test for single group median) with successive treatments with a mean improvement of 2.2 and 2.1 points in the VHI at the 12-week and 24-week follow-ups after treatment,

respectively (Figure 1). At 12 weeks following the third treatment, 82% of the patients showed a statistically significant increase in the VHI score ($P < 0.05$, Wilcoxon signed-rank test for paired data) with a mean score of 20.0 ± 2.1 (range 17–24). Six patients had a VHI score > 20 . Improvement remained statistically significant ($P < 0.01$) compared to baseline at the 24-week follow-up with a mean VHI score of 19.7 ± 1.4 (range 18–23).

Subjective assessments

Subject assessment of vaginal and sexual symptoms also improved with successive treatments (Figure 2). At 12 weeks following the third treatment, 81% of subjects reported an improvement in sexual gratification (more friction with a greater number and improved orgasms), and 94% reported an improvement in vaginal rejuvenation (increased vaginal tightening and improvement in dryness and atrophy). All subjects (100%) reported satisfaction with treatment and 94% would recommend the procedure. At 24 weeks after treatment, subjective improvement in vaginal rejuvenation and overall satisfaction remained high at 88%, while sexual gratification decreased to findings similar to those at the 6-week follow-up assessments (Figure 2).

Safety findings

Treatments did not require analgesia/anesthesia. Mean treatment time, including examination of the area and prep (cleaning the treatment area with a disinfecting solution), was 19 ± 3 minutes. Most patients (97%) reported that both internal and external treatment phases were accompanied with none to mild pain (mean discomfort of 1.6 ± 1.4 and 2.49 ± 1.36 for the internal and external treatments, respectively). Immediate treatment responses were mild and transient, resolving within 1–2 days and included burning sensation (20%),

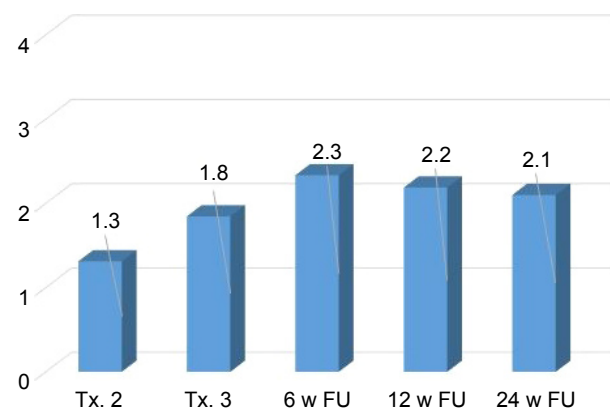


Figure 1 Mean increase in investigator assessment of vaginal health index score by study visit.

Abbreviations: Tx, treatment; w, week; FU, follow-up.

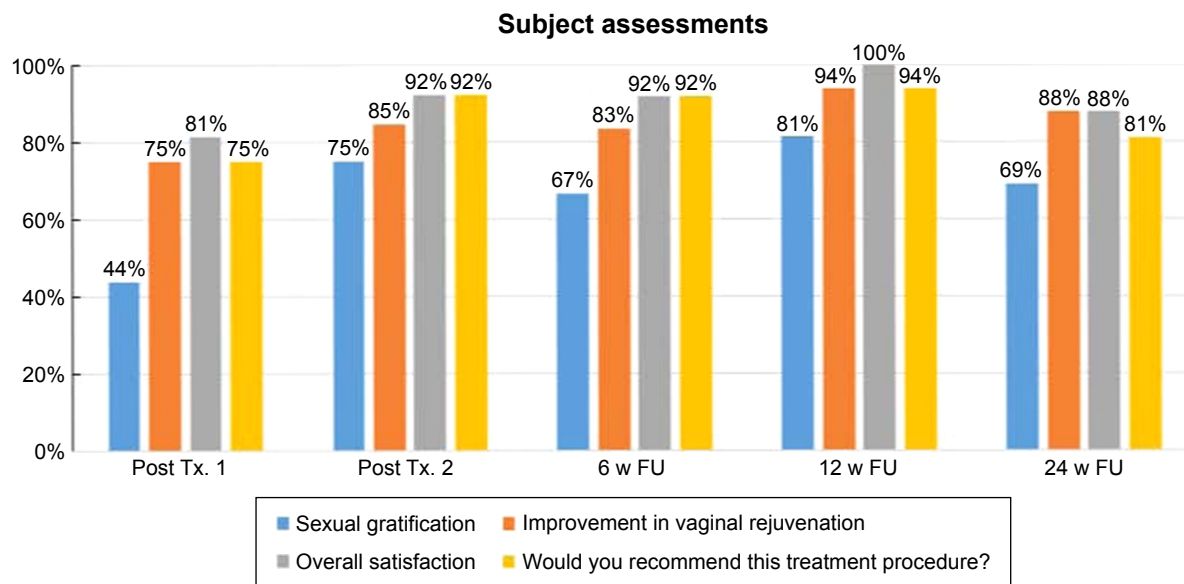


Figure 2 Subjective assessments of vaginal symptom questionnaire by study visit.
Abbreviations: Tx, treatment; w, week; FU, follow-up.

itching (20%), bruising (4%), swelling (4%), twinging sensation (4%), numbness (4%), and purpura (2%). There were no treatment complications, and adverse effects were limited to a 50-year-old patient with a mild urinary infection following her first treatment that resolved completely after a weekly course of oral antibiotics. The patient did not experience a recurrence of the infection or any other adverse symptoms following the two additional treatments.

Discussion

CO₂ lasers have long been considered as a precise and predictable treatment modality to rejuvenate photoaged skin by ablation of abnormal tissues with subsequent regeneration and remodeling of collagen and through heat-induced collagen contraction.^{18,19} Histologic changes induced by CO₂ laser pulses in human skin have been studied and compared with tissue contraction of wound healing caused by resurfacing with erbium lasers.^{19,20} Single-pass CO₂ laser treatment versus multiple-pass Er:YAG laser resurfacing produced equivalent thermal injury on immediate postoperative biopsies and subsequent degree of fibroplasia at 3 or 6 months.²⁰ Collagen tightening induced by three passes of CO₂ laser persisted at 6 months after the procedure.¹⁹ Fractional techniques result in new collagen formation and skin tightening with the added benefit of short-term postoperative erythema and a favorable benefit-risk ratio.²¹ Fractional CO₂ laser resurfacing has also been used to improve genital skin condition and mucosal tissues in females with lichen sclerosis.^{22,23}

The regenerative effects of collagen remodeling have been applied to treatment of genitourinary changes, such as

thinning in the epithelial lining of the vagina and atrophy, which occur due to a fall in estrogen levels. Heat-induced thermal remodeling with new collagen deposition improves the tissue quality of the vaginal canal, while ablation to the external labia produces tissue regeneration. CO₂ laser is capable of restoring the pH of the vaginal mucosa by liberating glycogen and acidic mucins from the epithelium.¹⁷ Symptoms of dryness and itching, dysuria, and recurrent infections can be alleviated by increasing the glycogen that rebalances lactobacilli, which inhibit the growth and virulence of pathogenic bacteria.¹⁷

CO₂ laser treatment has previously demonstrated significant improvement in GSM symptoms in postmenopausal women.^{11,14-16} However, the effects of laser treatment in perimenopausal women, experiencing childbirth and age-related vaginal and sexual symptoms of VVA, have not been previously reported. Similar to other studies in postmenopausal women,^{11,14} data from our study indicated a significant increase in VHI scores in perimenopausal women who underwent three sessions of fractional CO₂ laser vaginal treatment. Improvement in VHI scores approached significance ($P=0.053$) after two treatments. Relevant VVA symptoms also improved after two treatments, with the majority of patients reporting improvement in sexual gratification and tightening effects (vaginal rejuvenation). Findings were highly significant ($P<0.01$) following three treatments. Although clinical improvement in facial wrinkling and photodamage have been observed at 12 months postoperatively following CO₂ laser resurfacing,¹⁸ support for long-term effect beyond 3 months is lacking for vaginal CO₂ laser treatment. The perimenopausal

population studied here, though limited in sample size, does support that there is still significant improvement in vaginal health and VVA symptoms up to 8 months following three treatments. Future maintenance treatments may be warranted in this study population, and the effect of collagen remodeling on emerging climacteric symptoms in these women is unknown. The role of CO₂ laser treatment, as a non-hormonal treatment option, during this transition stage to potentially prevent or reduce GSM symptoms during menopause should be explored.

Conclusion

In this study population, fractional CO₂ laser treatment was associated with improvement of vaginal health and amelioration of symptoms of VVA, resulting in improved satisfaction with sexual intimacy in perimenopausal women. Improvement was maintained at the 24-week follow-up. Treatment time was quick, and there was minimal discomfort associated with treatment. Investigation of long-term clinical outcome, up to 12 months post-treatment, in a postmenopausal population is currently ongoing at a multi-center study in the USA.

Acknowledgment

Study equipment was provided by Syneron Candela.

Disclosure

The author reports no conflicts of interest in this work.

References

- Mac Bride MB, Rhodes DJ, Shuster LT. Vulvovaginal atrophy. *Mayo Clin Proc.* 2010;85(1):87–94.
- Palma F, Volpe A, Villa P, Cagnacci A; Writing group of AGATA study. Vaginal atrophy of women in postmenopause. Results from a multi-centric observational study: The AGATA study. *Maturitas.* 2016;83:40–44.
- Barbero M, Micheletti L, Borgno G, Cavanna L, Preti M, Ghiringhello B. Vulvar dystrophies in young and premenopausal women. *J Reprod Med.* 1988;33(6):555–558.
- Portman DJ, Gass ML; Vulvovaginal Atrophy Terminology Consensus Conference Panel. Genitourinary syndrome of menopause: new terminology for vulvovaginal atrophy from the International Society for the Study of Women's Sexual Health and the North American Menopause Society. *Maturitas.* 2014;79(3):349–354.
- Ivankovich MB, Fenton KA, Douglas JM Jr. Considerations for national public health leadership in advancing sexual health. *Public Health Rep.* 2013;128 (Suppl 1):102–110.
- Kingsberg SA, Wysocki S, Magnus L, Krychman ML. Vulvar and vaginal atrophy in postmenopausal women: findings from the REVIVE (REal Women's Views of Treatment Options for Menopausal Vaginal ChangeEs) survey. *J Sex Med.* 2013;10(7):1790–1799.
- Management of symptomatic vulvovaginal atrophy: 2013 position statement of The North American Menopause Society. *Menopause.* 2013;20(9):888–902.
- Notelovitz M. Urogenital aging: solutions in clinical practice. *Int J Gynaecol Obstet.* 1997;59 (Suppl 1):S35–S39.
- Gupta P, Sturdee DW, Palin SL, et al. Menopausal symptoms in women treated for breast cancer: the prevalence and severity of symptoms and their perceived effects on quality of life. *Climacteric.* 2006;9(1):49–58.
- Steinauer JE, Waetjen LE, Vittinghoff E, et al. Postmenopausal hormone therapy: does it cause incontinence? *Obstet Gynecol.* 2005;106(5 Pt 1):940–945.
- Perino A, Calligaro A, Forlani F, et al. Vulvo-vaginal atrophy: a new treatment modality using thermo-ablative fractional CO₂ laser. *Maturitas.* 2015;80(3):296–301.
- Gambacciani M, Levancini M, Cervigni M. Vaginal erbium laser: the second-generation thermotherapy for the genitourinary syndrome of menopause. *Climacteric.* 2015;18(5):757–763.
- Lee MS. Treatment of vaginal relaxation syndrome with an erbium: YAG laser using 90° and 360° scanning scopes: a pilot study & short-term results. *Laser Ther.* 2014;23(2):129–138.
- Sokol ER, Karram MM. An assessment of the safety and efficacy of a fractional CO₂ laser system for the treatment of vulvovaginal atrophy. *Menopause.* 2016;23(10):1102–1107.
- Salvatore S, Nappi RE, Parma M, et al. Sexual function after fractional microablative CO₂ laser in women with vulvovaginal atrophy. *Climacteric.* 2015;18(2):219–225.
- Salvatore S, Leone Roberti Maggiore U, Athanasiou S, et al. Histological study on the effects of microablative fractional CO₂ laser on atrophic vaginal tissue: an ex vivo study. *Menopause.* 2015;22(8):845–849.
- Zerbinati N, Serati M, Origoni M, et al. Microscopic and ultrastructural modifications of postmenopausal atrophic vaginal mucosa after fractional carbon dioxide laser treatment. *Lasers Med Sci.* 2015;30(1):429–436.
- Fitzpatrick RE, Goldman MP, Satur NM, Tope WD. Pulsed carbon dioxide laser resurfacing of photo-aged facial skin. *Arch Dermatol.* 1996;132(4):395–402.
- Fitzpatrick RE, Rostan EF, Marchell N. Collagen tightening induced by carbon dioxide laser versus erbium: YAG laser. *Lasers Surg Med.* 2000;27(5):395–403.
- Ross EV, Miller C, Meehan K, et al. One-pass CO₂ versus multiple-pass Er:YAG laser resurfacing in the treatment of rhytides: a comparison side-by-side study of pulsed CO₂ and Er:YAG lasers. *Dermatol Surg.* 2001;27(8):709–715.
- Manstein D, Herron GS, Sink RK, Tanner H, Anderson RR. Fractional photothermolysis: a new concept for cutaneous remodeling using microscopic patterns of thermal injury. *Lasers Surg Med.* 2004;34(5):426–438.
- Peterson CM, Lane JE, Ratz JL. Successful carbon dioxide laser therapy for refractory anogenital lichen sclerosis. *Dermatol Surg.* 2004;30(8):1148–1151.
- Lee A, Lim A, Fischer G. Fractional carbon dioxide laser in recalcitrant vulval lichen sclerosis. *Australas J Dermatol.* 2016;57(1):39–43.

International Journal of Women's Health

Publish your work in this journal

The International Journal of Women's Health is an international, peer-reviewed open-access journal publishing original research, reports, editorials, reviews and commentaries on all aspects of women's healthcare including gynecology, obstetrics, and breast cancer. The manuscript management system is completely online and includes

Submit your manuscript here: <http://www.dovepress.com/international-journal-of-womens-health-journal>

Dovepress

a very quick and fair peer-review system, which is all easy to use. Visit <http://www.dovepress.com/testimonials.php> to read real quotes from published authors.