

Acute inflammation at a mandibular solitary horizontal incompletely impacted molar

Minoru Yamaoka
Yusuke Ono
Masahide Ishizuka
Yoko Hasumi-Nakayama
Ryosuke Doto
Kouichi Yasuda
Takashi Uematsu
Kiyofumi Furusawa

Oral and Maxillofacial Surgery,
Matsumoto Dental University School
of Dentistry, Shiojiri, Nagano, Japan

Abstract: Acute inflammation is frequently seen in the elderly around incompletely impacted molars located apart from molars or premolars. To identify the factors causing acute inflammation in the solitary molars without second molars or without second and first molars, ages of patients and rates of acute inflammation in 75 horizontal incompletely impacted mandibular molars in contact or not in contact with molars in subjects 41 years old or older were studied using orthopantomographs. Acute inflammation was seen in nine third molars out of 48 third molars in contact with second molars (18.8%), whereas acute inflammation was seen in 11 molars out of 19 solitary molars without second molars or without first and second molars (57.9%) ($p < 0.01$). The mean age of 48 subjects with third molars in contact with the second molar was 50.42 ± 7.62 years, and the mean age of 19 subjects with isolated molars was 65.16 ± 10.41 years ($p < 0.0001$). These indicate that a solitary horizontal incompletely impacted molar leads more frequently to acute inflammation along with aging due to possible bone resorption resulting from teeth loss.

Keywords: mandible, third molar, impaction, elderly, acute inflammation, solitary molar

Introduction

Acute inflammation around the horizontal impacted third molar is frequently seen in not only the third molar in contact with the second molar but also that not in contact with the second molar or that without the second molar in the elderly (Figure 1). A partially impacted tooth affects soft tissue infection,^{1,2} and it is estimated that acute inflammation is affected by local factors, especially the position and angulation of the mandibular third molar,^{1,3,4} which results in complications.⁵ The area surrounding the crown of a horizontal impacted molar, where periodontium is not present, may easily develop acute inflammation as the name pericoronitis implies. Third molars may continue to have a negative impact on periodontal health well into middle-age and beyond in adults.⁶ Accordingly, an understanding of the expression of acute inflammation is important to prevent possible extension to severe complications in the elderly. However, there is a lack of information about isolated impacted molars because of the inability to distinguish the third molar in reports of molar loss.

A completely impacted third molar is not usually removed unless there are signs and symptoms around the region. However, the crown of the tooth could be exposed with bone resorption due to periodontitis or removal of adjacent tooth and, especially in aging, opportunities of infection around the exposed crown of a horizontal impacted third molar may increase complications and patient quality of life concerns. Recognition of the horizontal impacted third molar status is important for assessment of the quality of life in elderly. Subjects with an impacted third molar with or without a decayed second molar may benefit from information on the increased risk for acute inflammation. Nevertheless, little is known regarding the status of the horizontal incompletely impacted solitary molar.

Correspondence: Minoru Yamaoka
Matsumoto Dental University School
of Dentistry, Shiojiri, Nagano
399-0781 Japan
Fax +81 263 51 2076
Email yamaoka@po.mdu.ac.jp

Our study sought to find predictive ability of acute inflammation in age and adjacent tooth loss occurring bone resorption. Differences between impacted third molars in contact with second molars and solitary incompletely impacted molars in the absence of second molars, or second and first molars, were studied as a basis to identify the factors causing acute inflammation in horizontal impacted molars, since horizontal impaction of first or second molars is extremely rare, and a risk of inflammation is known in patients with horizontal incompletely impacted third molars.⁵ We report the rates of acute inflammation around horizontal incompletely impacted molars isolated from the first molar or premolar, the patient ages, and discuss the prognostic value of factors influencing acute inflammation.

Methods

Orthopantomographs were examined from 47 teeth from 43 men and 28 teeth from 26 women who had horizontal incompletely impacted mandibular third molars in contact or not in contact with the second molars (Figure 2) or molars isolated from the second or/and first molars (Figure 1) with or without acute inflammation at the initial examination for diagnosis and treatment between April 1984 and March 1997 at Matsumoto Dental University Hospital, Oral and Maxillofacial Surgery Department (Table 1). Their chief complaints were exposure of tooth-like material, sense of discomfort, pain, or swelling. Acute inflammation was diagnosed from redness, swelling, tenderness, and/or discharge of pus with spontaneous pain around the tooth, trismus, and dysphagia. Presence of a horizontal incompletely impacted

molar was confirmed with orthopantomographs taken with a Panoramax Auto 20 mA, 80–84 kVp (Asahi, Kyoto, Japan) and the films were processed in an automatic developing machine (Konica SRX-501; Konica, Tokyo, Japan). Incompletely impacted third molars were horizontal to the second molar in angulation and were not fully covered with bone. Horizontal angulation was measured using horizontal lines drawn at various heights at which the occlusal plane of the second molar⁷ or the first molar when the second molar was lost, or the premolars when the second and first molars were lost. The inclination of the occlusal plane of the third molar was read from the line on a compass. Teeth with inclinations of 70° or greater were selected as horizontal angulation following Shiller.⁷ Measurements of radiograms were performed twice by the same experienced oral surgeon. The second time was performed after a period of months without seeing primary data. Mean values in measurements were calculated. Teeth with inclination of 69° or smaller on either measurement within two measurements were excluded from the study. Teeth were separated in three groups; a group of third molars in contact with the second molar in the presence of first and second molars; a group of teeth not contact with the second molar; and a group of molars without second molars or without first and second molars. Analysis was performed by comparing these groups. Patients with periapical lesions of the second and third molars, root fragments of these teeth, a radiographically true cyst or tumor in the molars, mesioangular impaction, a vertical impaction, or distoangular impaction and history of fracture were excluded from analysis.

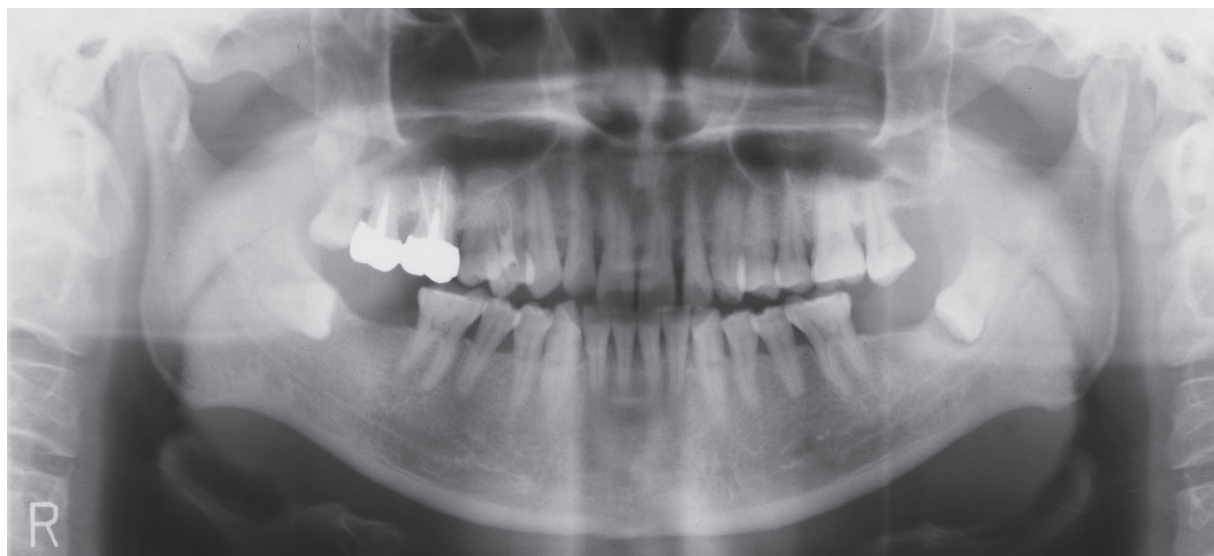


Figure 1 Isolated left incompletely impacted molar without the second molar with acute inflammation in a 52-year-old man.

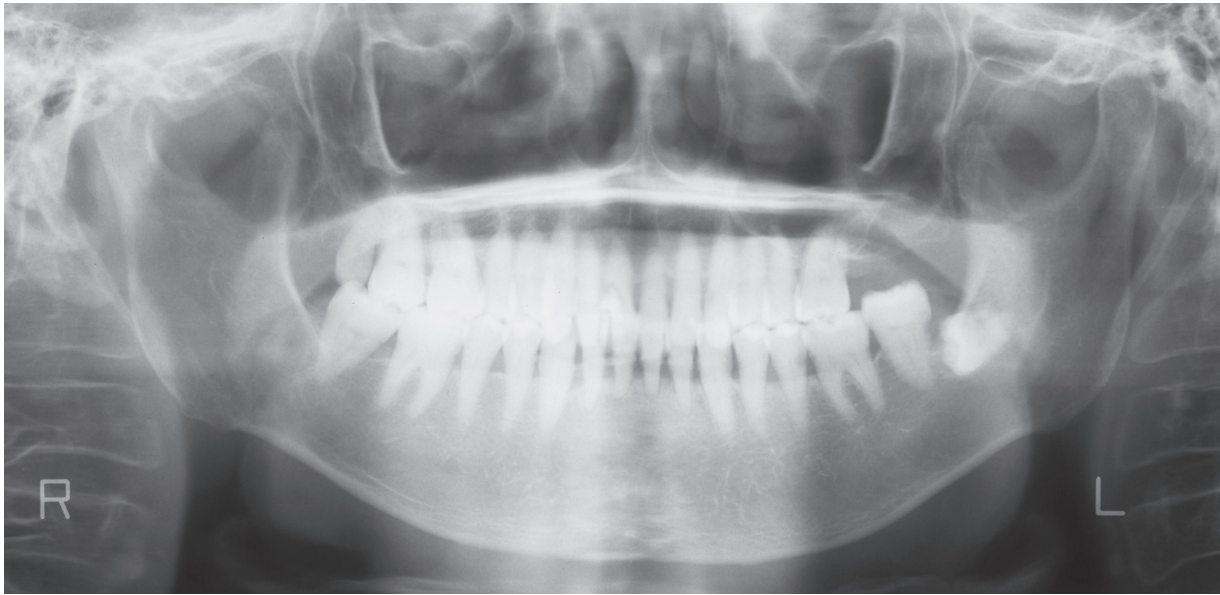


Figure 2 Left incompletely impacted third molar not in contact with the second molar without acute inflammation in a 73-year-old woman.

Statistical analysis

Rates of teeth with acute inflammation and ages of patients were calculated and analyzed statistically using Fischer's t-test or χ^2 analysis, and Student's t-test among these groups.

Results

We studied 47 teeth from men and 28 teeth from women. The mean age of men was 55.89 ± 11.06 years (range: 41–81 years), and that of women was 51.29 ± 9.76 years (range: 41–73 years). No significant difference was seen between men and women. Eight teeth (five teeth in men and three teeth in women) that were horizontal impacted third molars not in contact with the second molar in the presence of first and second molars were excluded from the present study in order to compare the solitary molars with the third molars in contact with the second molars (Table 1). The results revealed that the mean age of 42 men was 57.10 ± 10.98 years (range: 41–81 years) and that of 25 women was 50.40 ± 9.11 years (range: 41–73 years). Differences between men and women were significant ($p < 0.05$). None of patients showed bilaterally acute inflammation.

Rates of teeth with acute inflammation in men and women were as follows: 17 teeth, including eight teeth with acute inflammation in teeth in contact with second molars, and nine solitary teeth with loss of the second molar or the second and first molars out of 42 teeth in men, in whom 'no contact with molar' was excluded, accounted for 40.5%. Three teeth including one tooth with acute inflammation in teeth in contact with the second molars, and two teeth in loss of the second molar or the second and first molars out of 25 teeth in women,

in whom 'no contact with molar' was excluded, accounted for 12%. Differences between men and women were significant ($p < 0.05$).

On the other hand, the mean age of 48 subjects (28 teeth from men and 20 teeth from women) with third molars in contact with second molars was 50.42 ± 7.62 years (range: 41–72 years), and 19 subjects (14 teeth from men and five teeth from women) without second molars or second and first molars was 65.16 ± 10.41 years (range: 50–81 years). Significant differences were seen between them ($p < 0.0001$). Nine third molars showed acute inflammation out of 48 third molars in contact with second molars in men and women (18.8%), whereas 11 molars showed acute inflammation out of 19 molars with loss of the second molar or the second and first molars in both men and women (57.9%). The difference between third molars in contact with second molars and molars without second molar or second and first molars was significant ($p < 0.01$). Moreover, the mean age of nine subjects with third molars in contact with second molars with acute inflammation was 53.44 ± 9.26 years (range: 43–67 years), whereas the mean age of 11 solitary molars with acute inflammation was 67.45 ± 11.65 years (range: 50–81 years). A significant difference was seen between them ($p < 0.01$).

Discussion

The present study showed a higher frequency of acute inflammation in molars with loss of second molars or second and first molars than third molars in contact with second molars in the elderly at the first examination. The horizontal

Table 1 Acute inflammation (AI) in horizontal incompletely impacted molars

Age (y)	Gender	Contact with molar		No contact with molar		Solitary molar		Total	
		with AI	without AI	with AI	without AI	with AI	without AI	with AI	without AI
41–50	Men	3	12	1	2	1	1	5	15
	Women	1	15	0	1	0	0	1	16
51–60	Men	3	5	0	2	1	2	4	9
	Women	0	3	0	1	1	0	1	4
61–70	Men	2	2	0	0	2	1	4	3
	Women	0	1	0	0	0	2	0	3
71≤	Men	0	1	0	0	5	1	5	2
	Women	0	0	0	1	1	1	1	2
Total	Men	8	20	1	4	9	5	18	29
	Women	1	19	0	3	2	3	3	25

incompletely impacted molars were probably third molars because the space represents the width of the crown of lost teeth. These were shown to be characteristic in the elderly as the age of the population with loss of the second molars or second and first molars was significantly higher than that with third molars in contact with second molars, and the age of men was also significantly higher than that of women, whereas pericoronitis is frequently seen between 16 and 30 years of age,³ and more in females.⁸ Our data shows that solitary horizontal incompletely impacted molar had an age-dependent increase in the risk of acute inflammation. The plausible explanation is that causes of the high frequency of acute inflammation in the elderly might be an easy eruption of the crown,⁹ which has no periodontium, resulting from a natural bone resorption with increasing age or due to loss of the second and first molars, increases the risk of acute inflammation, probably through denser bone tissue than younger patients, and acute inflammation might develop or be prolonged because of a higher tolerance for pain with cognitive impairment. This may support our previous report that noncontact with an adjacent tooth might be associated with purulent inflammation in patients 45 years of age or older with completely impacted third molars.¹⁰ Thus, among patients with a mandibular horizontal incompletely impacted third molar, those without adjacent tooth have a higher risk of acute inflammation than those with adjacent tooth. This study shows that loss of adjacent tooth is predictor of acute inflammation among the elderly with mandibular horizontal incompletely impacted third molar. This relationship may be dependent of aging. In fact, alveolar bone resorption takes place with increasing age,^{11–18} resulting in low prevalence of completely impacted third molars in the edentulous jaw.¹⁹ An incompletely impacted

third molar might be removed because of possibility of acute inflammation when the second molar was removed. Factors determining the alveolar bone resorption are gender^{11,15,18,20} other than age, and bone resorption is significant in women over 60 years old.¹⁸ Time after extraction is also a factor,¹² and there is more alveolar ridge resorption after tooth loss in women than men.²⁰ Especially, earlier stages of edentulism²¹ result in a high degree of mandibular residual ridge resorption in more than half the edentulous patients.²² Such bone resorption has been usually measured with a panoramic radiograph. Recently, mandibular cortical width values were demonstrated to be stable in men over 60 years old.¹⁸ These indicate that bone resorption after tooth removal should be inferred in not only vertical length but also horizontal width of alveolar bone to determine if a completely impacted third molar will be exposed with removal of the second molar.

Given the observation that rates of acute inflammation in third molars was higher in men than women, although the mean age of men was significantly higher than women, we should also consider whether gender differences affect local factors in molars with and without second or second and first molars. This might be supported by the traditional attitude in the provinces that men are less likely to visit the dentist than women, as shown in the elderly in the north of England.²³ This seems to be a cultural difference, not only in England but also in Japan with implications in terms of health care provision, and suggests a cultural gender difference, as it is noted that women associate the impact of oral health with their feelings of attractiveness,²⁴ as shown by the observation that denture wearers were more likely to be female among an elderly institutionalized population.²⁵ On the other hand, although the occurrence

of acute inflammation has not been shown to be related to oral hygiene practices,¹ local factors such as food impaction in pockets around the crown or the inability to perform adequate cleaning due to the difficulty of brushing solitary incompletely impacted molars located away from the first molar or the premolars may result in insufficient tooth hygiene and a high prevalence of acute inflammation. Points between different locations may be selectively controlled by local immunity associated with innate and adaptive immune responses to initiate a range of host defense mechanisms, since Muthukuru and colleagues²⁶ showed that gingiva is infiltrated by large numbers of Toll-like receptor 2+ (TLR2[+]), and TLR4(+) cells increase in chronic periodontitis, and Erciyas and colleagues²⁷ showed that local immune response was poor in patients with chronic periodontitis. Further study is needed to assess whether the adjacent tooth protects the third molar by local immunity.

A study of the third molar in elderly has been restricted because of loss of teeth, and the third molar has been investigated in the presence of first and second molars to ensure that it is the third molar. This does not always indicate problems in the elderly, and loss of these teeth based on tooth caries or periodontitis results in limited knowledge of the third molars. Although loss of the second molar or the second and first molars should be interpreted with caution, fortunately, horizontal impaction allowed identification of the third molar because impacted horizontally and solitary second or first molars are extremely rare. This study was limited by small samples. Review of follow-up data is also needed in many cases.

In conclusion, patients may have quality of life deterioration when a horizontal incompletely impacted third molar is present under loss of the adjacent tooth since acute inflammation in molars without second molars or second and first molars increases along with aging and with possible bone resorption. These suggest an increased risk of acute inflammation in patients who have had an adjacent tooth removed. Removal of the horizontal impacted third molar is recommended when the second molar is removed. This information could be useful for the diagnosis and treatment of not only solitary horizontal incompletely impacted molars but also horizontal incompletely impacted third molar in contact with decayed second molars.

Acknowledgments

We wish to thank Mrs. Shiho Kobayashi for her secretarial assistance. The authors report no conflicts of interest in this work.

References

1. Leone SA, Edenfield MJ, Cohen ME. Correlation of acute pericoronitis and the position of the mandibular third molar. *Oral Surg Oral Med Oral Pathol.* 1986;62(3):245–250.
2. Peterson LJ, Ellis E, Hupp JR, Tucker MR. Contemporary oral and maxillofacial surgery. St. Louis, MO: Mosby; 1988. p. 227–228.
3. Kay LW. Investigations into the nature of pericoronitis. *Br J Oral Surg.* 1966;3(3):188–205.
4. Yamalik K, Bozkaya S. The predictivity of mandibular third molar position as a risk indicator for pericoronitis. *Clin Oral Investig.* 2008;12(1):9–14.
5. Polat HB, Ozan F, Kara I, Ozdemir H, Ay S. Prevalence of commonly found pathoses associated with mandibular impacted third molars based on panoramic radiographs in Turkish population. *Oral Surg Oral Med Oral Pathol Oral Radiol Endod.* 2008;105(6):e41–e47.
6. Elter JR, Offenbacher S, White RP, Beck JD. Third molars associated with periodontal pathology in older Americans. *J Oral Maxillofac Surg.* 2005;63(2):179–184.
7. Shiller WR. Position change in mesioangular impacted third molars during a year. *J Am Dent Assoc.* 1979;99(3):460–464.
8. Batainneh AB, Al QM. The predisposing factors of pericoronitis of mandibular third molars in a Jordanian population. *Quintessence Int.* 2003;34(3):227–231.
9. Yamaoka M, Furusawa K, Yamamoto M. Influence of adjacent teeth on impacted third molars in the upper and lower jaws. *Aust Dent J.* 1995;40(4):233–235.
10. Yamaoka M, Tambo A, Furusawa K. Incidence of inflammation in completely impacted lower third molars. *Aust Dent J.* 1997;42(3):153–155.
11. Humphries S, Devlin H, Worthington H. Aradiographic investigation into bone resorption of mandibular alveolar bone in elderly edentulous adults. *J Dent.* 1989;17(2):94–96.
12. Bairam LR, Miller WA. Mandible bone resorption as determined from panoramic radiographs in edentulous male individuals ages 25–80 years. *Gerodontology.* 1994;11(2):80–85.
13. Xie Q, Wolf J, Soikkonen K, Ainamo A. Height of mandibular basal bone in dentate and edentulous subjects. *Acta Odontol Scand.* 1996;54(6):379–383.
14. Bajjoon M, Natto S, Bergstrom J. Occurrence of vertical bone defects in dentally aware individuals. *Acta Odontol Scand.* 2003;61(1):47–51.
15. Bollen AM, Taguchi A, Hujoel PP, Hollender LG. Number of teeth and residual alveolar ridge height in subjects with a history of self-reported osteoporotic fractures. *Osteoporos Int.* 2004;15(12):970–974.
16. Müller HP, Ulbrich M. Alveolar bone levels in adults as assessed on panoramic radiographs. (1) Prevalence, extent, and severity of even and angular bone loss. *Clin Oral Investig.* 2005;9(2):98–104.
17. Kasaj A, Vasiliu Ch, Willershausen B. Assessment of alveolar bone loss and angular bony defects on panoramic radiographs. *Eur J Med Res.* 2008;13(1):26–30.
18. Yüzügüllü B, Gulsahi A, Imirzalioglu P. Radiomorphometric indices and their relation to alveolar bone loss in completely edentulous Turkish patients: a retrospective study. *J Prosthet Dent.* 2009;101(3):160–165.
19. Yamaoka M, Furusawa K, Fujimoto K, Uematsu T. Completely impacted teeth in dentate and edentulous jaws. *Aust Dent J.* 1996;41(3):169–172.
20. Sağlam AA. The vertical heights of maxillary and mandibular bones in panoramic radiographs of dentate and edentulous subjects. *Quintessence Int.* 2002;33(6):433–438.
21. Karaagaçlıoğlu L, Ozkan P. Changes in mandibular ridge height in relation to aging and length of edentulism period. *Int J Prosthodont.* 1994;7(4):368–371.
22. Zmysłowska E, Ledzion S, Jedrzejewski K. Factors affecting mandibular residual ridge resorption in edentulous patients: a preliminary report. *Folia Morphol (Warsz).* 2007;66(4):346–352.
23. Steele JG, Walls AW, Ayatollahi SM, Murray JJ. Dental attitudes and behaviour among a sample of dentate older adults from three English communities. *Br Dent J.* 1996;180(4):131–136.

24. Trulsson U, Engstrand P, Berggren U, Nannmark U, Branemark PI. Edentulousness and oral rehabilitation, experiences from the patient perspective. *Eur J Oral Sci.* 2002;110(6):417-424.
25. Ferreira RC, de Magalhaes CS, Moreira AN. Tooth loss, denture wearing and associated factors among an elderly institutionalized Brazilian population. *Gerodontology.* 2008;25(3):168-178.
26. Muthukuru M, Jotwani R, Cutler CW. Oral mucosal endotoxin tolerance induction in chronic periodontitis. *Infect Immune.* 2005;73(2):687-694.
27. Erciyas K, Orbak R, Kavrut F, Demir T, Kaya H. The changes in T lymphocyte subsets following periodontal treatment in patients with chronic periodontitis. *J Periodontal Res.* 2006;41(3):165-170.