

# Atypical musculoskeletal manifestations of gout in hyperuricemia patients

Muhammad Sakti  
Muhammad Andry Usman  
Jansen Lee  
Michael Benjamin  
Qariah Maulidiah

Department of Orthopaedic and  
Traumatology, Hasanuddin University  
Teaching Hospital, Makassar, Indonesia

**Abstract:** Deposition of tophus is a common feature in chronic gout; however, signs and symptoms are not always well-pronounced in cases of uncommon sites. We report a case series of three patients, one with an acute locked knee suspected to be meniscus tear or intra-articular loose body, a second case with a lump on the dorsal hand suspected to be a benign lesion, and a third case with a finger flexion deformity with carpal tunnel syndrome; all three cases were later on found out to be tophaceous gout. White chalky monosodium urate crystal deposition was found to be the culprit of the symptoms of the patients.

**Keywords:** gout, tophus, uric acid, knee, extensor tendon, flexor tendon, carpal tunnel syndrome

## Introduction

The incidence of gout has increased over the past decades and continues to increase.<sup>1</sup> The risk factors include genetic factors, alcohol consumption, high-purine diet, metabolic syndrome, medications such as diuretics, and kidney disease.<sup>2,3</sup> The culinary trend in the population especially in South Sulawesi, Indonesia, such as meat and offal, contributes to high incidence of gout with various unique manifestations.

## Case I

A 51-year-old right-handed male presented in our outpatient clinic with inability to extend his right long finger since 1 month ago. He also noticed a slowly enlarging mass over the volar aspect of his right distal forearm within the past year. Ever since then, patient also felt numbness at his thumb, index, and long finger, which worsened when his long finger was extended. His long finger was held fixed in the flexed position in an attempt to relieve the pain and numbness sensation. There was no history of fever, night sweats, weight loss, decrease in appetite, malaise, or fatigue. There was no history of trauma or pain at other joints of the body or morning stiffness. Patient was not exposed to any vibratory tools. Patient has a history of hyperuricemia since 10 years ago and was not treated regularly.

On physical examination, paresthesia was found along the distribution of median nerve with decreased grip strength and flattening of the thenar eminence. Tinel sign was positive. At the forearm region, a solid mass of approximately 3 cm x 2 cm was palpated at the volar aspect proximal to the flexor retinaculum. It was non-tender, non-compressible, and mobile with no local increase in skin temperature or color changes. Movement of wrist was normal with restriction of long finger extension.

Correspondence: Jansen Lee  
Department of Orthopaedic and  
Traumatology, Hasanuddin University  
Teaching Hospital, Jalan Perintis  
Kemerdekaan Km.11 – Tamalanrea,  
Makassar, South Sulawesi 90245,  
Indonesia  
Tel +62 812 634 3585  
Email lee.jansen.88@gmail.com

Laboratory findings revealed elevated serum uric acid (9.2 mg/dL) and decreased estimated glomerular filtration rate (eGFR, 70 mL/min/1.73 m<sup>2</sup>; mildly decreased renal function according to the Chronic Kidney Disease Epidemiology Collaboration calculation). Radiological findings showed no significant changes. MRI revealed a fusiform mass, which was heterogeneous isointense on sagittal T1-image and heterogeneous hyperintense on axial fat suppression image within the flexor digitorum superficialis (FDS).

We opted to perform surgical exploration to remove the mass using a longitudinal incision along the wrist flexion crease extending proximally. Superficial dissection revealed a white chalky mass, which had infiltrated the FDS tendon. Median nerve was significantly compressed by the tophus. The mass did not adhere to the surrounding structures. Excision of the nodular tophus was performed yet not thoroughly due to extensive intratendinous infiltration. We also performed carpal tunnel decompression.

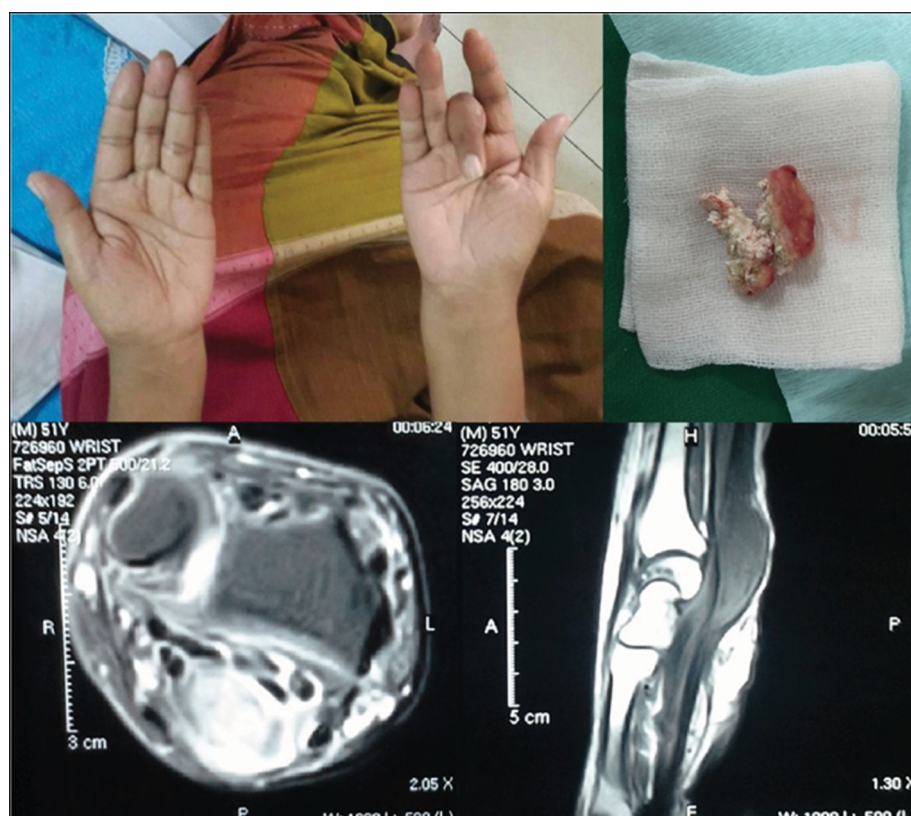
Patient was then given allopurinol. One month after surgery, the wound healed with significant improvement of symptoms and increased range of motion of the long finger. There was no recurrence or new lesion elsewhere (Figure 1).

## Case 2

A 44-year old male presented with a visible mass over the dorsal aspect of his right dominant hand. The mass was enlarging gradually for the past 3 months and was painless. No mass was found elsewhere. The patient sought treatment due to his inability to fully flex his right long finger. There was no significant previous history of trauma or similar condition found in the family.

On physical examination, we found a visible mass over the dorsal aspect of right hand (over the third metacarpal), which was visibly moving as the long finger was flexed and extended. There was limited flexion as the mass reached the metacarpophalangeal joint region. There were no skin color changes or local change in skin temperature. The mass itself was felt solid-hard with irregular surface and clear border, sized 4 cm × 3 cm and fixed to the extensor digitorum tendon of the long finger. There was no tenderness.

Laboratory results were insignificant except for the serum uric acid (8.4 mg/dL) and decreased eGFR (81 mL/min/1.73 m<sup>2</sup>; mildly decreased renal function according to the Chronic Kidney Disease Epidemiology Collaboration calculation). Radiograph examination of the hand region showed a soft



**Figure 1** Clinical picture of right hand with the long finger fixed in the flexion position and flattening of the thenar eminence.

**Notes:** Excised mass is shown. MRI revealing heterogeneous fusiform mass within flexor digitorum superficialis.

tissue mass over the dorsal aspect of the right hand with no calcification.

We decided to perform an open exploration to restore the motion of the long finger. The incision was made longitudinally along the dorsal aspect of right hand. Dissection of the tendon sheath of the long finger extensor digitorum revealed a white chalky mass adhering and infiltrating the tendon. We could not completely excise the mass, but we managed to reduce the mass volume so that it does not disrupt the movement of the long finger anymore.

Post-operatively, active motion of the finger was encouraged and a prescription of allopurinol was given. On 2 months follow-up, the wound healed uneventfully and the lesion did not recur elsewhere. The range of motion of the right long finger was excellent (Figure 2).

### Case 3

A 41-year-old male presented in our outpatient clinic with mild discomfort of the left knee since 1 year ago, which gradually worsened in the past 1 month due to recurrent locking sensation. There was no previous history of trauma. Patient was known to have a medical history of asymptomatic hyperuricemia (highest serum uric acid level was 10.2 mg/dL, untreated) and diabetes mellitus (routinely treated with oral antihyperglycemic drugs). Patient was also noted to have decreased eGFR (68 mL/min/1.73 m<sup>2</sup>; mildly decreased

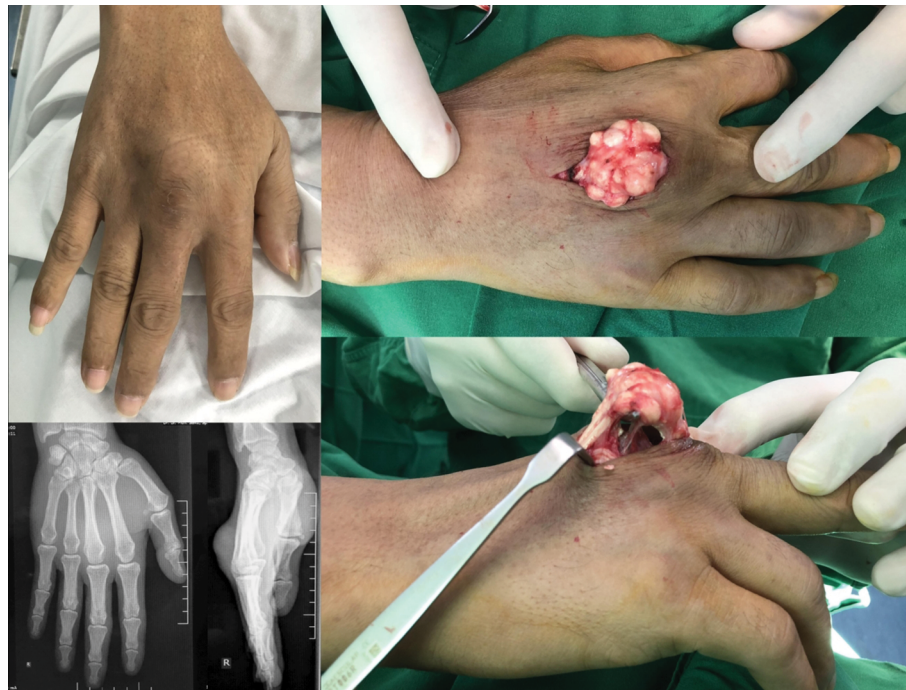renal function according to the Chronic Kidney Disease Epidemiology Collaboration calculation).

On examination, he walked with an antalgic gait and presented with a mildly swollen left knee. We found that the knee was locked in 10 degrees flexion. Further evaluation for meniscus integrity revealed a possibility for medial meniscus tear. Clinical tests for torn ligaments were negative. Conventional radiography examination of the knee showed negative pathology except mild joint space narrowing.

Arthroscopic diagnostic and debridement were then performed on the left knee. In the intra-arthroscopic procedure, a white chalky appearance was found covering over the whole surface of articular cartilage, including patella. Interestingly, the whole meniscus was covered by tophus with visible tophaceous loose bodies. Debridement and removal of loose bodies were performed. Post-operatively, he responded well to analgesics and urate-lowering agent. He was able to regain a full range of motion at 4 weeks post-operatively (Figure 3).

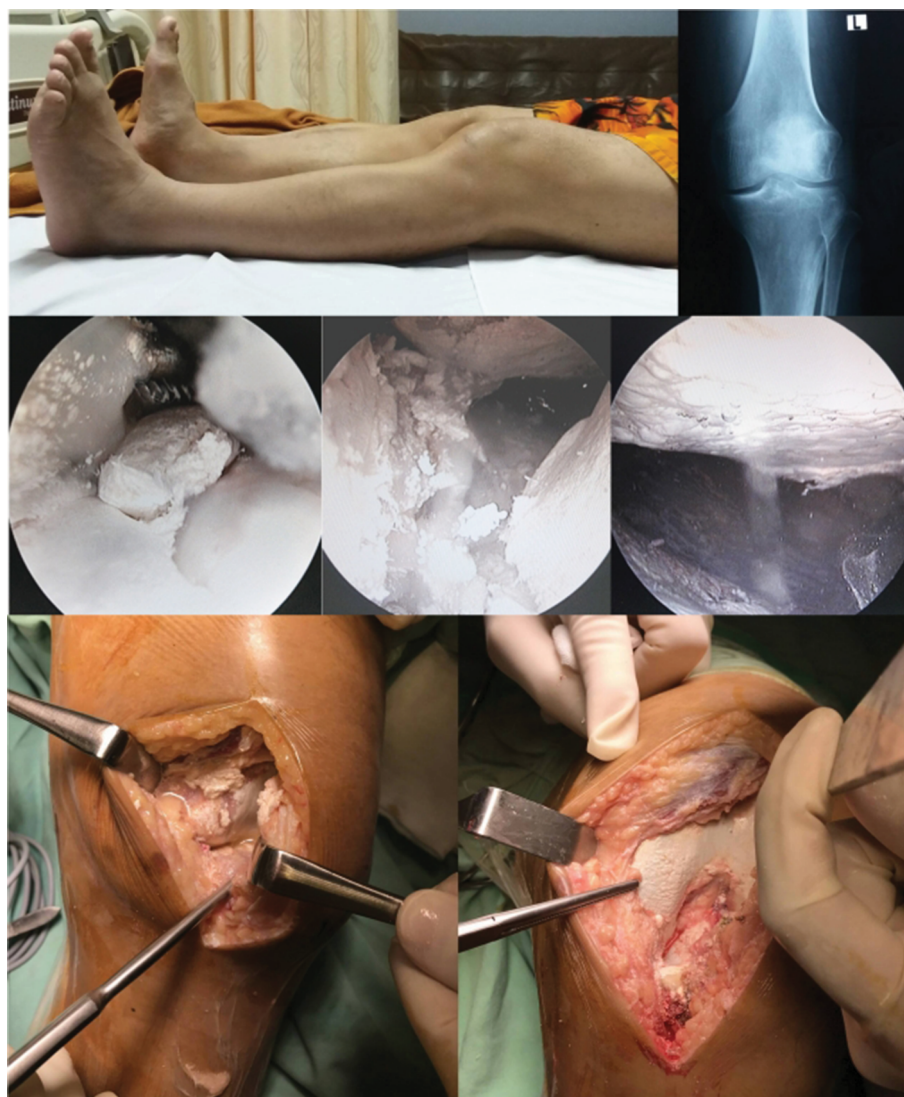### Discussion

Serum uric acid concentration represents the balance between the breakdown of purine and excretion of uric acid. The solubility threshold is approximately 7 mg/dL, and the likelihood of crystal tissue deposition will increase if interstitial fluid is oversaturated.<sup>4,5</sup> Despite this, many people with hyperuricemia do not develop gout or even form uric acid crystals.<sup>6</sup>



**Figure 2** Clinical picture of mass at the dorsal aspect of right hand with soft tissue mass with no apparent findings at the radiograph.  
**Note:** Intraoperative finding revealed a white chalky mass adhering and infiltrating the tendon.





**Figure 3** Clinical picture of knee in fixed 10 degree flexion and normal radiography.

**Notes:** Intra-arthroscopic findings revealed a white chalky lesion with tophaceous loose bodies. Open debridement revealed extensive involvement of all joint surface.

Evidence shows that decreased collagen and proteoglycan content in the joint along with increased cartilage degradation products in the joint fluid lowers the urate solubility and promoted the formation of monosodium urate (MSU) crystals. The inflammatory reaction and inflammatory cytokine release found in gout cases are triggered by the phagocytosis of MSU crystals although the urate crystal itself can act directly and indirectly in stimulating an inflammatory response that causes tissue destruction.<sup>7,8</sup>

The clinical spectrum of the disease, so-called great mimicker, varies from asymptomatic to chronic pain with four distinct stages, including asymptomatic hyperuricemia, acute gouty arthritis, intercritical gout, and chronic tophaceous gout. The classic manifestation is the acute gouty attack, which involves inflammatory reaction with redness, hotness,

intense tenderness, swelling, and loss of function of affected joints and fever, headache, and malaise as the constitutional symptoms.<sup>9,10</sup> There is limited evidence about the subclinical musculoskeletal involvement in asymptomatic individuals with hyperuricemia, but in those with apparent involvement, the commonest site is the lower extremity especially the first metatarsophalangeal joint (podagra) with other various areas of involvement including the fingers, scrotum, external ears, articular cartilage, and tendon.<sup>11-13</sup>

In the cases presented here, no significant past gouty attack, family history, or past medical history of hypertension and diuretics consumption was found, and therefore these initial atypical findings could not have led the clinician to arrive at the initial diagnosis of tophaceous gout. Patients

with increased serum uric acid as seen in our case have an increased risk of progression toward renal failure with a rate of 7% for each 1 mg/dL increment. Conversely, however, decreased renal function as estimated by decreased GFR also has an adverse effect predisposing patient to a 2–3-fold increased risk of gout for each 30 mL/min/1.73 m<sup>2</sup>. In our cases, only mild decrease in GFR was found.<sup>14,15</sup>

Some rare manifestations of gouty tophus include its findings in the carpal tunnel and tendons of the upper limb as opposed to the more common involvement of Achilles and patellar tendon.<sup>16–19</sup>

In our case, the carpal tunnel was initially thought to be idiopathic in nature as seen in nearly 50% of the cases while the actual prevalence of tophaceous gout as a causative factor in carpal tunnel remains undetected due to subclinical manifestations, some studies predicted it to be around 0.6%–2%.<sup>17,20,21</sup>

Several proposed mechanisms of how gout can cause carpal tunnel syndrome have been published. Some proposed that the direct increase in volume was triggered by gouty tenosynovitis, nodular tophi, gouty deposits on the nerve, or even decrease in carpal tunnel volume from the bulging tophaceous deposits on the bony floor.<sup>21–24</sup>

In the last case presented, we have also found an intra-articular gouty tophi with atypical presentations (knee locking and fixed flexion deformity). These findings are considered to be extremely rare, and as such, it may sometimes be mistaken for an intra-articular tumor. Arthroscopic examination in our case revealed that both medial and lateral menisci were fully covered by MSU with tophus foreign bodies. This atypical presentation misled to the diagnosis of internal derangement of the knee. Other previous reports of a case of painful and locked knee due to gouty tophi reveal spontaneous disease resolution using a trial of prolonged allopurinol and narcotics treatment instead of surgery, which is more commonly reserved for cases with severe deformity, loss of function, and persistent pain.<sup>25–28</sup>

Gouty arthritis has been one of the most comprehensively studied conditions, and its attack has been known to be multifactorial in origin. Triggering factors such as osteoarthritis have been well-known but other factors may include local anatomical temperature, minor physical trauma, and biomechanical stress, which collectively create the “perfect” condition for crystal deposition. The deposition of crystals as seen in our cases may be triggered by these aforementioned factors. Increased friction of tendons within the carpal tunnel or at the extensor tendons region in patients with a predisposition (increased serum uric acid) for tophaceous gouty attack will eventually present with an atypical manifestation.<sup>29</sup>

We have treated our patient surgically even though pre-operative medicative treatment cannot be provided as the diagnosis did not come early. Medicative treatment with lifelong lowering of uricemia such as allopurinol was initiated post-operatively under specific targets, which allows the pathogenic crystals to dissolve and further suppress the disease manifestations. The recommended serum uric acid level is below 6 mg/dL in all gouty patients or 5 mg/dL in severe gout patients to allow more rapid dissolution of the crystals.<sup>8</sup> This staged treatment is in accordance with the “dirty dish” hypothesis, proposed by Perez-Ruiz et al,<sup>30</sup> which likened the prevention of new crystal formation to cleaning a dirty dish: as more is required to get it clean than to keep it clean.

Another potent agent that may be utilized includes rasburicase. This agent acts as a recombinant form of an enzyme, urate oxidase, and may be considered in cases where allopurinol could not be used due to allergy or failure.<sup>31</sup> As for the treatment regime, although initial treatment is commonly initiated with a single agent, some authors advocate the use of multiple agents to achieve the target level of serum uric acid. One of the combinations proposed include the use of lesinurad (selective uric acid resorption inhibitor) and febuxostat (xanthine oxidase inhibitor), which has been proven to lower the serum uric acid level in 100% of the cases studied without any clinically relevant changes in the pharmacokinetics of either drugs.<sup>32</sup>

## Conclusion

This case series demonstrates that gout does not always cause severe joint pain from inflammatory arthritis, and atypical presentations of gouty tophi could mislead the diagnosis of mechanical symptoms such as tophus deposition of flexor tendon causing carpal tunnel syndrome, extensor tendon involvement mimicking tumor and preventing normal tendon excursion, and locking sensation initially suspected to be a meniscus tear or loose bodies of the knee. Late arrival at the correct diagnosis and comprehensive treatment could eventually lead to severe impairment as seen in this case series.

## Ethical approval

These cases are reviewed retrospectively in this study. Therefore, institutional approval was not required to publish the case details. All procedures performed involving human participants were in accordance with the ethical standards of the Hasanuddin University Teaching Hospital research committee.

## Informed consent

Written informed consents were obtained from all patients for publication of this case series regarding case details and accompanying images.

## Disclosure

None of the authors received payments or other benefits or a commitment or agreement to provide such benefits from a commercial entity. No commercial entity paid or directed, or agreed to pay or direct, any benefits to any research fund, foundation, educational institution, or other charitable or nonprofit organizations with which the authors are affiliated or associated with. The authors report no conflicts of interest in this work.

## References

1. Arromdee E, Michet CJ, Crowson CS, O'Fallon WM, Gabriel SE. Epidemiology of gout: is the incidence rising? *J Rheumatol*. 2002;29(11):2403–2406.
2. Roddy E, Zhang W, Doherty M. The changing epidemiology of gout. *Nat Clin Pract Rheumatol*. 2007;3(8):443–449.
3. Mohd A, Gupta E, Loh Y, et al. Clinical characteristics of gout: a hospital case series. *Malays Fam Physician*. 2011;6(2–3):72–73.
4. Pineda C, Amezcua-Guerra LM, Solano C, et al. Joint and tendon subclinical involvement suggestive of gouty arthritis in asymptomatic hyperuricemia: an ultrasound controlled study. *Arthritis Res Ther*. 2011;13(1):R4.
5. Kumar R, Sahni VK, Jauhar S. Finger flexion contracture: first manifestation of gout. *J Orthop Case Rep*. 2015;5(2):66–68.
6. Ragab G, Elshahaly M, Bardin T. Gout: an old disease in new perspective – a review. *J Adv Res*. 2017;8(5):495–511.
7. Mittl GS, Zuckerman JD. The unique macroscopic appearance of gouty arthritis of the knee. *Bull Hosp Jt Dis*. 2015;73(3):210–212.
8. McQueen FM, Chhana A, Dalbeth N. Mechanisms of joint damage in gout: evidence from cellular and imaging studies. *Nat Rev Rheumatol*. 2012;8(3):173–181.
9. Perez-Ruiz F, Castillo E, Chinchilla SP, Herrero-Beites AM. Clinical manifestations and diagnosis of gout. *Rheum Dis Clin North Am*. 2014;40(2):193–206.
10. Hasham S, Burke FD. Diagnosis and treatment of swellings in the hand. *Postgrad Med J*. 2007;83(979):296–300.
11. Roddy E. Revisiting the pathogenesis of podagra: why does gout target the foot? *J Foot Ankle Res*. 2011;4(1):13.
12. Hussin P, Mawardi M, Nizlan NM. The 'Chalky Culprit' of acute locked knee. *G Chir*. 2014;35(9–10):239–240.
13. Rouault T, Caldwell DS, Holmes EW. Aspiration of the asymptomatic metatarsophalangeal joint in gout patients and hyperuricemic controls. *Arthritis Rheum*. 1982;25(2):209–212.
14. Tsai CW, Lin SY, Kuo CC, Huang CC. Serum uric acid and progression of kidney disease: a longitudinal analysis and mini-review. *PLoS One*. 2017;12(1):e0170393.
15. Krishnan E. Reduced glomerular function and prevalence of gout: NHANES 2009–10. *PLoS One*. 2012;7(11):e50046.
16. Kim HS. Carpal tunnel syndrome caused by tophaceous gout. *Korean J Intern Med*. 2014;29(4):544–545.
17. Rich JT, Bush DC, Lincoski CJ, Harrington TM. Carpal tunnel syndrome due to tophaceous gout. *Orthopedics*. 2004;27(8):862–863.
18. Carroll M. Ultrasound evaluation of the Achilles tendon in tophaceous gout: a case-control study. *Arthritis Rheumatol*. 2016;68(Suppl 10):Abstract 3127.
19. Rodas G, Pedret C, Català J, Soler R, Orozco L, Cusi M. Intratendinous gouty tophus mimics patellar tendonitis in an athlete. *J Clin Ultrasound*. 2013;41(3):178–182.
20. Chen CK, Chung CB, Yeh L, et al. Carpal tunnel syndrome caused by tophaceous gout: CT and MR imaging features in 20 patients. *Am J Roentgenol*. 2000;175(3):655–659.
21. Joseph MaK KC, Ip FK, Wong TC, Wan SH, Chan SY. Carpal tunnel syndrome caused by gout: clinical presentations, surgical findings, and outcomes after surgery. *J Orthop Trauma Rehabil*. 2015;19(1):15–20.
22. Lin YC, Chen CH, Fu YC, et al. Carpal tunnel syndrome and finger movement dysfunction caused by tophaceous gout: a case report. *Kaohsiung J Med Sci*. 2009;25(1):34–39.
23. Raffael L, Rajesh S. Median nerve compression by Gouty tophi: a case report. *Int Med J Malays*. 2015;14(1):87–91.
24. Ge Y, Li F, Chen J, Tian J. Severe carpal tunnel syndrome caused by Gouty tophi diagnosed by dual energy computed tomography: case report. *Arch Rheumatol*. 2016;31(3):284–286.
25. Amber H, Singh VA, Azura M. Gouty tophi mimicking synovial sarcoma of the knee joint. *Turk J Rheumatol*. 2012;27(3):208–211.
26. Kijkunasathian C, Woratanarat P, Saengpetch N. Gouty tophi caused limited knee range of motion: a case report. *J Med Assoc Thai*. 2009;92(Suppl 6):S264–S267.
27. Chatterjee S, Ilaslan H. Painful knee locking caused by Gouty tophi successfully treated with allopurinol. *Nat Rev Rheumatol*. 2008;4(12):675–679.
28. Gililland JM, Webber NP, Jones KB, Randall L, Aoki SK. Intratendinous tophaceous gout imitating patellar Tendonitis in an athletic man. *Orthopedics*. 2011;34(3):223.
29. Roddy E. Revisiting the pathogenesis of podagra: why does gout target the foot? *J Foot Ankle Res*. 2011;4(1):13.
30. Perez-Ruiz F, Herrero-Beites AM, Carmona L. A two-stage approach to the treatment of hyperuricemia in gout: the "dirty dish" hypothesis. *Arthritis Rheum*. 2011;63(12):4002–4006.
31. Cammalleri L, Malaguarnera M. Rasburicase represents a new tool for hyperuricemia in tumor lysis syndrome and in gout. *Int J Med Sci*. 2007;4(2):83–93.
32. Fleischmann R, Kerr B, Yeh LT, et al. Pharmacodynamic, pharmacokinetic and tolerability evaluation of concomitant administration of lesinurad and febuxostat in gout patients with hyperuricaemia. *Rheumatology*. 2014;53(12):2167–2174.

### Open Access Rheumatology: Research and Reviews

### Publish your work in this journal

Open Access Rheumatology: Research and Reviews is an international, peer-reviewed, open access journal publishing original research, reports, editorials, reviews and commentaries on all aspects of clinical and experimental rheumatology in the clinic and laboratory including the following topics: Pathology, pathophysiology of rheumatological diseases; Investigation, treatment and

management of rheumatological diseases; Clinical trials and novel pharmacological approaches for the treatment of rheumatological disorders. The manuscript management system is completely online and includes a very quick and fair peer-review system, which is all easy to use. Visit <http://www.dovepress.com/testimonials.php> to read real quotes from published authors.

Submit your manuscript here: <https://www.dovepress.com/open-access-rheumatology-research-and-reviews-journal>

Dovepress