

Cognitive impairment after liver transplantation: residual hepatic encephalopathy or posttransplant encephalopathy?

This article was published in the following Dove Press journal:
Hepatic Medicine: Evidence and Research

Linda Skibsted Kornerup¹
Henning Pflugrad²
Karin Weissenborn²
Hendrik Vilstrup¹
Gitte Dam¹

¹Department of Hepatology and Gastroenterology, Aarhus University Hospital, Aarhus N, Denmark;

²Department of Neurology, Hannover Medical School, Hannover, Germany

Abstract: Liver transplantation (LT) represents the definitive treatment for end-stage liver disease. Cognitive impairment following LT is frequent, referred to as postliver transplant encephalopathy (PLTE). LT removes the underlying chronic liver disease, and until recently hepatic encephalopathy (HE) was assumed to be fully reversible after LT. However, increasing evidence indicates that some degree of cognitive impairment may be present after LT. To which extent PLTE reflects cognitive impairment caused by residual HE (RHE) or the combined effect of other factors affecting brain function before, during, and after LT is not clarified. None of the available psychometric and neurophysiological tests used for detecting HE is shown to be able to distinguish between etiologies. The available, mostly retrospective, clinical studies indicate a high prevalence of abnormal psychometric tests after LT, and not all seem to recover completely. The patients with earlier HE show the most marked improvements, suggesting that the clinical picture of the early PLTE, in fact, represents RHE. Other early post-LT etiologies for PLTE comprise cerebral ischemia, critical illness encephalopathy, and immunosuppressive therapy. Late-onset etiologies comprise diabetes and hypertension, among others. PLTE regardless of etiology is a worrying issue and needs more attention in the form of mechanistic research, development of diagnostic/discriminative tools, and standardized prospective clinical studies.

Keywords: liver transplantation, hepatic encephalopathy, cirrhosis, cognitive impairment

Introduction

Liver transplantation (LT) represents the definitive treatment for end-stage liver disease irrespective of etiology.^{1–3} Many patients experience hepatic encephalopathy (HE) while waiting for LT or at the time of LT.^{4–7} Likewise, the HE burden is a decisive factor when patients are considered as candidates for the LT waiting list, although HE is not part of the Model for End-Stage Liver Disease (MELD) score often used for prioritization of liver grafts.⁸

After LT, cognitive impairment is frequently reported with encephalopathy as the predominant presentation.^{9–12} LT removes the underlying chronic liver disease that by definition causes HE and thereby effectively removes the suspected main pathogenic factor of HE, the hyperammonemia. The understanding of the nature of the cognitive impairment present after LT is insufficient, and no clear consensus of the nomenclature exists. In this article, the cognitive impairment after LT is referred to as postliver transplant encephalopathy (PLTE).

Correspondence: Linda Skibsted Kornerup
Department of Hepatology and Gastroenterology, Aarhus University Hospital, 99 Palle Juul-Jensens Boulevard, Aarhus N, 8200, Denmark
Email lindajen@rm.dk

Whether PLTE reflects residual cognitive impairment caused by and remaining after HE or the combined effect of other factors affecting the brain function before, during, and after LT is largely unknown.

Until recently, HE was widely assumed to be fully reversible. However, increasing evidence indicates that some degree of cognitive impairment may persist in patients after LT, but also in un-transplanted patients after HE resolution.^{13–16} Such cognitive impairment following LT attributable to earlier HE will in this article be referred to as residual HE (RHE). RHE may, in fact, reflect lasting cognitive impairments, but clarification is difficult due to the lack of validated testing methods, and because the pathophysiology of HE is complex and not completely understood. Several studies investigated the reversibility of HE after LT. A recent study by Campagna et al supports the hypothesis that some cognitive remnants of HE, ie, RHE, may persist after LT. They prospectively studied 65 patients before and 9–12 months after LT.¹⁷ Before LT, global cognitive function was worse for patients with previous HE than for patients without previous HE. Both patients with and without previous HE showed a clear improvement of global cognitive function after LT. Notably, although the degree of improvement was higher for patients with previous HE, their cognitive function did not completely recover to the level of patients without previous HE.

HE is aggravated in the presence of systemic and cerebral inflammation and by eg, diabetes, drugs, and alcohol.^{18–22} It has been proposed that hyperammonemia increases the brain's susceptibility to aggravating factors.²³ Furthermore, aggravating factors may cause cognitive impairment independent of that caused by hyperammonemia and thus may persist in spite of normalized ammonia levels after LT. Furthermore, the immunosuppressive therapy after transplantation has an undeniable negative impact upon brain function, particularly related to the use of calcineurin inhibitors.^{24,25}

Lewis et al showed that in long-term survivors of LT cognitive impairment was frequent and that health-related quality of life was significantly worse than in the healthy control group.²⁶ Pflugrad et al could detail this finding.²⁷ They studied the effect of pre-LT HE and neurological complications post-LT on employment status and health-related quality of life. Independent predictors of post-LT employment status were pre-LT employment status and post-LT health-related quality of life, while pre-LT HE and post-LT neurological complications surprisingly were

not. However, patients not employed pre-LT had a higher frequency of pre-LT HE, and patients not employed post-LT performed worse in the psychometric tests than patients employed post-LT.

In conclusion, it is not at present possible clearly to distinguish the impact of pretransplant HE on post-transplant cognitive impairment from that of other possible contributing factors. Importantly, cognitive impairment following LT has a heavy socioeconomic impact on the patients' health-related quality of life and working ability.

Hepatic encephalopathy (HE)

Around 50% of patients with cirrhosis will experience at least one episode of overt hepatic encephalopathy (OHE), and the 1-year mortality after the first bout is reported as high as about 50%.^{28–30} Even more will experience minimal HE (MHE), that is HE without clinical signs, but with measurable cognitive impairment. Furthermore, MHE carries a high risk for progression into OHE, recurrent or even persistent HE.³¹ HE is one important factor with major impact on the health-related quality of life (of patients and caregivers), cognitive function, as well as working ability.

The clinical presentation of HE is graded by the West Haven classification ranging from unimpaired (grade 0) to frank coma (grade IV).³¹ However, a large fraction of the clinically unimpaired patients (grade 0) shows cognitive deficits in neuropsychological and/or neurophysiological tests, which define MHE.^{32,33} A large array of tests are proposed and in use and to some extent validated to detect MHE with the basic limitation that no gold standard for the condition exists.³¹ These tests include psychometric tests and neurophysiological tests. Of the psychometric tests, the PSE (portosystemic encephalopathy) syndrome test – also known as the PHES (psychometric hepatic encephalopathy score) – is widely used. It comprises five paper-and-pencil tests and evaluates cognitive function regarding domains of attention, executive functions, psychomotor processing speed, and visuomotor coordination.³⁴ Computerized psychometric tests include the continuous reaction time test,³⁵ the inhibitory control test,³⁶ the Stroop test,³⁷ and the SCAN test.³⁸ The neurophysiological tests include the critical flicker frequency (CFF) test^{39,40} and the electroencephalogram (EEG). The EEG is independent of cognitive stimulation and patient cooperation and demonstrates a characteristic, but not specific, shift in electric activity in patients with HE.^{41,42} In clinical routine, liver centers can use the tests they are

familiar with, given that normative reference data are available. However, none of the tests is specific for HE, and the correlation between them is poor, likely due to the multidimensional dysfunctionality in HE.³¹ Thus, already the diagnosis of MHE presents unsolved difficulties, and when it comes to the diagnosis of RHE it must be kept in mind that the features of RHE are not well characterized. It can be expected, however, that RHE covers all or parts of the cognitive domains affected by MHE or OHE.

The available studies on cognitive function after LT are based on several of the tests used for diagnosing and monitoring MHE, sometimes combined with brain scans, mostly MRI. Some patients with cirrhosis perform worse than healthy controls in psychometric and neurophysiological tests, and whether these patients experience full cognitive recovery following successful LT is debated. The study by Campagna et al reported worse global cognitive function before LT for patients with previous HE compared with patients without previous HE.¹⁷ Both patients with and without previous HE showed a clear improvement of global cognitive function after LT. But their attention and executive function showed no improvement. Of interest, the EEG normalized in 98% of patients, underscoring the different capacities of psychometric and neurophysiological tests. Tryc et al studied changes in cognitive function before and 6 and 12 months after LT in 50 patients with cirrhosis.⁴³ What they took to be RHE was almost resolved within 6 months after LT. Again, the patients with previous HE showed the greatest improvement in psychometric tests and tests of global cognitive function. As an important observation, the patients with no previous HE showed a decline in cognitive function 12 months or later after LT, especially in visuospatial and visuoconstructive function. This seems to demonstrate that PLTE may occur independently of RHE and likely represents a distinct pathological cognitive entity. Mechtcheriakov et al prospectively followed 14 patients with cirrhosis before and 11–33 months after LT.⁴⁴ They similarly reported that about half of their patients improved their visuomotor and visuoconstructive functions, while the other half showed no improvement or even worsening in neuropsychiatric tests after LT. Mattarozzi et al studied the effect of LT on MHE 6–18 months after LT⁴⁵ and again at 7–10 years later.⁴⁶ They concluded that cognitive function improved in patients with previous MHE and that these improvements remained stable at the long-term follow-up. RHE seems to improve gradually 1–2 years following LT.^{17,43–46}

Neuroimaging with MRI in patients with HE depicts characteristic abnormalities with high signal intensity in the basal ganglia in T₁-weighted images⁴⁷ and along the corticospinal tract on T₂-weighted images.⁴⁸ The latter is considered to represent mild astrocytic swelling and low-grade cerebral edema and correlates with functional abnormalities of the corticospinal tract, while the hyperintensity in the basal ganglia has been shown to be due to a manganese deposition in the brain with preference in the basal ganglia that represents liver cirrhosis but has no correlation to HE.^{48–50} Such MRI alterations are reversible within 6–12 months after LT. Garcia-Martinez et al⁵¹ studied whole brain volume by MRI 6–12 months after (but not before) LT and found that lower post-transplant whole brain volumes were associated with increasing age, previous HE, time since first episode of HE, and alcohol etiology. The importance is uncertain, but lower whole brain volume was associated with poorer function on motor tests, although the post-transplant cognitive function on average was in the normal range.

Taken together, such studies convincingly indicate that some cognitive components of HE can persist after LT – in lack of better terminology coined RHE. The studies also suggest that RHE is most evident in the early phase after LT and in some cases may disappear in the long run, but the mechanistic background is not yet clarified. Thus, as for PLTE (cf. below), it seems to be meaningful to distinguish between early RHE within the first 12 months after LT and late or persistent RHE more than 12 months after LT.

Non-RHE PLTE

Numerous factors must be taken into account when evaluating post-LT cognitive function, and a number of these are better characterized and described than RHE (Figure 1). Thus, non-RHE PLTE is a less controversial issue than is RHE. Pre-LT factors include comorbidities (to the liver disease) and individual cognitive reserves represented by education or crystalline intelligence. Peri-LT factors include repeated and prolonged surgery, electrolyte dysbalance, or ischemia, while post-LT factors include immunosuppression, infections/sepsis, stroke, increasing age, cardiovascular risk factors/-disease, critical illness encephalopathy, etc.⁵² The recovery from cognitive impairment is a slow process and so it is important to differentiate between early and late PLTE which may even be a late-onset event years after LT. Neurotoxicity and PLTE are known side effects to immunosuppression with calcineurin inhibitors experienced by 30%

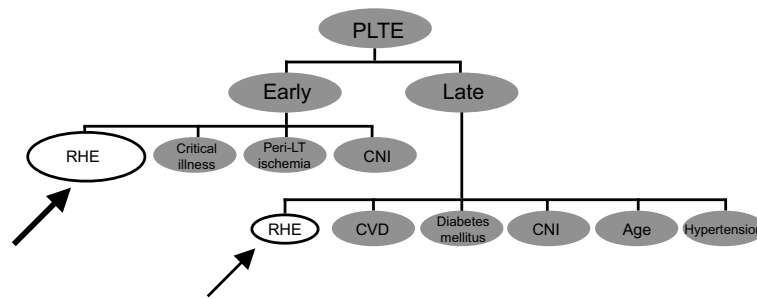


Figure 1 Risk factors for PLTE. Early PLTE: <12 months after LT. Late PLTE: >12 months after LT.

Abbreviations: PLTE, postliver transplantation encephalopathy; RHE, residual hepatic encephalopathy; LT, liver transplantation; CNI, calcineurin inhibitor; CVD, cardiovascular disease.

of patients within the first weeks after transplantation.^{24,25} Long-term side effects of calcineurin inhibitors have also been suspected with premature atherosclerosis and microangiopathy as proposed mechanisms.⁵³ Pflugrad et al⁵⁴ studied the long-term effect of calcineurin inhibitors on cognitive function for 10 years following LT. Calcineurin inhibitor use was a clear negative prognostic factor for post-transplant cognitive function. The treatment was also associated with increased white matter hyperintensity on MRI especially in the parietal and temporal regions. There was no association between MRI pathology and previous HE. Nonetheless, calcineurin inhibitor treatment was associated with impaired cognitive function in the cognitive domains of visuospatial/visuoconstructional ability, which is often impaired in HE as well.

Another important contributing factor to PLTE is the development of cerebrovascular disease.

Increasing age of the recipients and high incidence of cardiovascular risk factors, but also calcineurin inhibitor treatment, are positive predictors. Schoening et al showed that the risk of cerebrovascular events was around 3.5 times higher in the first decade after LT and 2 times higher in the second decade after LT compared with the standard population.⁵⁵

Several factors cause similar cognitive impairment, which further highlights the difficulty in isolating the contributing factors in PLTE.

Conclusion

Cognitive impairment, PLTE, is a frequent complication following LT. It is associated with the severity of underlying liver disease particularly as manifested by a history of MHE or OHE, pretransplant extrahepatic comorbidities, peritranplant factors such as prolonged and repeated surgery or ischemia, and post-transplant immunosuppressive therapy

and its complications. The majority of the patients have experienced HE, and the available knowledge indicates that some RHE may persist after LT. The impairment seems to improve with time, but it remains unsolved whether it is completely reversible. The existence of RHE may challenge the general understanding of the clinical course of HE. Currently, distinguishing between RHE and PLTE as the reason for cognitive impairment after LT is complicated as the pathophysiologies of both entities are not fully understood, and many factors contribute to the cognitive impairment after LT. PLTE, regardless of etiology, is a cause of worry and needs more attention in the form of mechanistic research, standardized prospective clinical studies, and development of diagnostic/discriminative tools. Such tests are not available, but ideally, they should offer the possibility for organizing tailored treatments for each afflicted post-transplant person's problems.

Abbreviation list

LT, Liver transplantation; HE, hepatic encephalopathy; PLTE, postliver transplant encephalopathy; RHE, residual HE; OHE, overt HE; MHE, minimal HE; PSE, portosystemic encephalopathy; PHES, psychometric hepatic encephalopathy score; CRT, continuous reaction time; ICT, inhibitory control test; CFF, critical flicker frequency; EEG, electroencephalogram; MRI, magnetic resonance imaging; MR, magnetic resonance.

Disclosure

The authors declare no conflicts of interest in this work.

References

- Zakhari S. Bermuda triangle for the liver: alcohol, obesity, and viral hepatitis. *J Gastroenterol Hepatol.* 2013;28(SUPPL 1):18–25. doi:10.1111/jgh.12207

2. Smith JM, Weaver T, Skeans MA, et al. OPTN/SRTR 2016 annual data report: liver. 2016;1–37. doi:10.1111/ajt.14560.
3. Farkas S, Hackl C, Schlitt HJ. Overview of the indications and contraindications for liver transplantation. *Cold Spring Harb Perspect Med.* 2014;4(5):1–13. doi:10.1101/cshperspect.a015602
4. Buis CI, Wiesner RH, Krom RAF, Kremers WK, Wijdsicks EFM. Acute confusional state following liver transplantation for alcoholic liver disease. *Neurology.* 2002;59(4):601–605. doi:10.1212/WNL.59.4.601
5. Goldbecker A, Weissenborn K, Shahrezaei GH, et al. Comparison of the most favoured methods for the diagnosis of hepatic encephalopathy in liver transplantation candidates. *Gut.* 2013;62(10):1497–1504. doi:10.1136/gutjnl-2012-303262
6. Kim KM, Kim GS, Ko JS, Gwak MS, Lee SK, Son MG. Factors associated with consciousness recovery time after liver transplantation in recipients with hepatic encephalopathy. *Transplant Proc.* 2014;46(3):712–715. doi:10.1016/j.transproceed.2013.12.031
7. Bernhardt M, Pflugrad H, Goldbecker A, et al. Central nervous system complications after liver transplantation: common but mostly transient phenomena. *Liver Transplant.* 2015;21(2):224–232. doi:10.1002/lt.24035
8. Burra P, Burroughs A, Graziadei I, et al. EASL clinical practice guidelines: liver transplantation. *J Hepatol.* 2016;64(2):433–485. doi:10.1016/j.jhep.2015.10.006
9. Stracciari A, Guarino M. Neuropsychiatric complications of liver transplantation. *Metab Brain Dis.* 2001;16(1–2):3–11. Available from: <http://ovidsp.ovid.com/ovidweb.cgi?T=JS&PAGE=reference&D=emed5&NEWS=N&AN=2001405771>. Accessed October 6, 2018.
10. Fu KA, DiNorcia J, Sher L, et al. Predictive factors of neurological complications and one-month mortality after liver transplantation. *Front Neurol.* 2014;5:1–6. doi:10.3389/fneur.2014.00275
11. Saner FH, Sotiropoulos GC, Gu Y, et al. Severe neurological events following liver transplantation. *Arch Med Res.* 2007;38(1):75–79. doi:10.1016/j.arcmed.2006.07.005
12. Bronster DJ, Emre S, Boccagni P, Sheiner PA, Schwartz ME, Miller CM. Central nervous system complications in liver transplant recipients - Incidence, timing, and long-term follow-up. *Clin Transplant.* 2000;14(1):1–7. doi:10.1034/j.1399-0012.2000.140101.x
13. Bajaj JS, Schubert CM, Heuman DM, et al. Persistence of cognitive impairment after resolution of overt hepatic encephalopathy. *Gastroenterology.* 2010;138(7):2332–2340. doi:10.1053/j.gastro.2010.02.015
14. Riggio O, Ridola L, Pasquale C, et al. Evidence of persistent cognitive impairment after resolution of overt hepatic encephalopathy. *Clin Gastroenterol Hepatol.* 2011;9(2):181–183. doi:10.1016/j.cgh.2010.10.002
15. Umapathy S, Dhiman RK, Grover S, Duseja A, Chawla YK. Persistence of cognitive impairment after resolution of overt hepatic encephalopathy. *Am J Gastroenterol.* 2014;109(7):1011–1019. doi:10.1038/ajg.2014.107
16. Nardelli S, Allampati S, Riggio O, et al. Hepatic encephalopathy is associated with persistent learning impairments despite adequate medical treatment: a multicenter, international study. *Dig Dis Sci.* 2017;62(3):794–800. doi:10.1007/s10620-016-4425-6
17. Campagna F, Montagnese S, Schiff S, et al. Cognitive impairment and electroencephalographic alterations before and after liver transplantation: what is reversible? *Liver Transpl.* 2014;20(8):977–986. doi:10.1002/lt.23909
18. García-Martínez R, Córdoba J. Acute-on-chronic liver failure: the brain. *Curr Opin Crit Care.* 2011;17(2):177–183. doi:10.1097/MCC.0b013e328344b37e
19. Chavarría L, Córdoba J. Encephalopathy and liver transplantation. *Metab Brain Dis.* 2013;28(2):285–292. doi:10.1007/s11011-012-9350-6
20. Butterworth RF. Neuronal cell death in hepatic encephalopathy. *Metab Brain Dis.* 2007;22(3–4):309–320. doi:10.1007/s11011-007-9072-3
21. Jepsen P, Watson H, Andersen PK, Vilstrup H. Diabetes as a risk factor for hepatic encephalopathy in cirrhosis patients. *J Hepatol.* 2015;63(5):1133–1138. doi:10.1016/j.jhep.2015.07.007
22. Elkrif L, Rautou PE, Sarin S, Valla D, Paradis V, Moreau R. Diabetes mellitus in patients with cirrhosis: clinical implications and management. *Liver Int.* 2016;36(7):936–948. doi:10.1111/liv.13115
23. Butterworth RF. Pathogenesis of hepatic encephalopathy in cirrhosis: the concept of synergism revisited. *Metab Brain Dis.* 2016;31(6):1211–1215. doi:10.1007/s11011-015-9746-1
24. Bechstein WO. Neurotoxicity of calcineurin inhibitors: impact and clinical management. *Transpl Int.* 2000;13(5):313–326. Available from: <http://www.ncbi.nlm.nih.gov/pubmed/11052266>. Accessed September 14, 2018.
25. Amodio P, Biancardi A, Montagnese S, et al. Neurological complications after orthotopic liver transplantation. *Dig Liver Dis.* 2007;39(8):740–747. doi:10.1016/j.dld.2007.05.004
26. Lewis MB, Howdle PD. Cognitive dysfunction and health-related quality of life in long-term liver transplant survivors. *Liver Transplant.* 2003;9(11):1145–1148. doi:10.1053/jlts.2003.50239
27. Pflugrad H, Tryc AB, Goldbecker A, et al. Hepatic encephalopathy before and neurological complications after liver transplantation have no impact on the employment status 1 year after transplantation. *World J Hepatol.* 2017;9(10):519–532. doi:10.4254/wjh.v9.i10.519
28. Jepsen P, Ott P, Andersen PK, Sørensen HT, Vilstrup H. Clinical course of alcoholic liver cirrhosis: a Danish population-based cohort study. *Hepatology.* 2010;51(5):1675–1682. doi:10.1002/hep.23500
29. Bustamante J, Rimola A, Ventura PJ, et al. Prognostic significance of hepatic encephalopathy in patients with cirrhosis. *J Hepatol.* 1999;30(5):890–895. doi:10.1016/S0168-8278(99)80144-5
30. Fichtel J, Mercier E, Genée O, et al. Prognosis and 1-year mortality of intensive care unit patients with severe hepatic encephalopathy. *J Crit Care.* 2009;24(3):364–370. doi:10.1016/j.jcrc.2009.01.008
31. Vilstrup H, Amodio P, Bajaj J, et al. Hepatic encephalopathy in chronic liver disease: 2014 Practice Guideline by the American Association for the Study of Liver Diseases and the European Association for the Study of the Liver. *Hepatology.* 2014;60(2):715–735. doi:10.1002/hep.27210
32. Groeneweg M, Moerland W, Quero JC, Hop WCJ, Krabbe PF, Schalm SW. Screening of subclinical hepatic encephalopathy. *J Hepatol.* 2000;32(5):748–753. doi:10.1016/S0168-8278(00)80243-3
33. Randolph C, Hilsabeck R, Kato A, et al. Neuropsychological assessment of hepatic encephalopathy: ISHEN practice guidelines. *Liver Int.* 2009;29(5):629–635. doi:10.1111/j.1478-3231.2009.02009.x
34. Weissenborn K, Ennen JC, Schomerus H, Rückert N, Hecker H. Neuropsychological characterization of hepatic encephalopathy. *J Hepatol.* 2001;34(5):768–773. Available from: <http://www.ncbi.nlm.nih.gov/pubmed/11434627>. Accessed February 6, 2019.
35. Lauridsen MM, Thiele M, Kimer N, Vilstrup H. The continuous reaction times method for diagnosing, grading, and monitoring minimal/covert hepatic encephalopathy. *Metab Brain Dis.* 2013;28(2):231–234. doi:10.1007/s11011-012-9373-z
36. Bajaj JS, Hafeezullah M, Franco J, et al. Inhibitory control test for the diagnosis of minimal hepatic encephalopathy. *Gastroenterology.* 2008;135(5):1591–1600. doi:10.1053/j.gastro.2008.07.021
37. Bajaj S, Thacker LR, Heuman DM, Fuchs M, Al E. The stroop smartphone app is a short and valid method to screen for minimal hepatic encephalopathy. *Hepatology.* 2014;58(3):1122–1132. doi:10.1002/hep.26309.The
38. Amodio P, Del Piccolo F, Marchetti P, et al. Clinical features and survival of cirrhotic patients with subclinical cognitive alterations detected by the number connection test and computerized psychometric tests. *Hepatology.* 1999;29(6):1662–1667. doi:10.1002/hep.510290619

39. Häussinger D, Wettstein M, Kircheis G, Schnitzler A, Timmermann L. Critical flicker frequency for quantification of low-grade hepatic encephalopathy. *Hepatology*. 2002;35(2):357–366. doi:10.1053/jhep.2002.30957
40. Sharma P, Sharma BC, Puri V, Sarin SK. Critical flicker frequency: diagnostic tool for minimal hepatic encephalopathy. *J Hepatol*. 2007;47(1):67–73. doi:10.1016/j.jhep.2007.02.022
41. Guerit JM, Amantini A, Fischer C, et al. Neurophysiological investigations of hepatic encephalopathy: ISHEN practice guidelines. *Liver Int*. 2009;29(6):789–796. doi:10.1111/j.1478-3231.2009.02030.x
42. Amodio P, Montagnese S, Spinelli G, Schiff S, Mapelli D. Cognitive reserve is a resilience factor for cognitive dysfunction in hepatic encephalopathy. *Metab Brain Dis*. 2017;32(4):1287–1293. doi:10.1007/s11011-017-0032-2
43. Tryc AB, Pflugrad H, Goldbecker A, et al. New-onset cognitive dysfunction impairs the quality of life in patients after liver transplantation. *Liver Transplant*. 2014;20(7):807–814. doi:10.1002/lt.23887
44. Mechtcheriakov S, Graziadei IW, Mattedi M, et al. Incomplete improvement of visuo-motor deficits in patients with minimal hepatic encephalopathy after liver transplantation. *Liver Transpl*. 2004;10(1):77–83. doi:10.1002/lt.20009
45. Mattarozzi K, Stracciari A, Vignatelli L, D'Alessandro R, Morelli MC, Guarino M. Minimal hepatic encephalopathy: longitudinal effects of liver transplantation. *Arch Neurol*. 2004;61(2):242–247. doi:10.1001/archneur.61.2.242
46. Mattarozzi K, Cretella L, Guarino M, Stracciari A. Minimal hepatic encephalopathy: follow-up 10 years after successful liver transplantation. *Transplantation*. 2012;93(6):639–643. doi:10.1097/TP.0b013e318244f734
47. Kulisevsky J, Pujol J, Balanzó J, et al. Pallidal hyperintensity on magnetic resonance imaging in cirrhotic patients: clinical correlations. *Hepatology*. 1992;16(6):1382–1388.
48. Córdoba J, Raguer N, Flavià M, et al. T2 hyperintensity along the cortico-spinal tract in cirrhosis relates to functional abnormalities. *Hepatology*. 2003;38(4):1026–1033. doi:10.1053/jhep.2003.50406
49. Córdoba J, Alonso J, Rovira A, et al. The development of low-grade cerebral edema in cirrhosis is supported by the evolution of fH-magnetic resonance abnormalities after liver transplantation. *J Hepatol*. 2001;35(5):598–604. doi:10.1016/S0168-8278(01)00181-7
50. Häussinger D, Kircheis G, Fischer R, Schliess F, Dahl SV. Hepatic encephalopathy in chronic liver disease: a clinical manifestation of astrocyte swelling and low-grade cerebral edema? *J Hepatol*. 2000;32(6):1035–1038. doi:10.1016/S0168-8278(00)80110-5
51. García-Martínez R, Rovira A, Alonso J, et al. Hepatic encephalopathy is associated with posttransplant cognitive function and brain volume. *Liver Transpl*. 2011;17(1):38–46. doi:10.1002/lt.22197
52. García-Martínez R, Simón-Talero M, Córdoba J. Prognostic assessment in patients with hepatic encephalopathy. *Dis Markers*. 2011;31(3):171–179. doi:10.3233/DMA-2011-0840
53. D'Avola D, Cuervas-Mons V, Martí J, et al. Cardiovascular morbidity and mortality after liver transplantation: the protective role of mycophenolate mofetil. *Liver Transplant*. 2017;23(4):498–509. doi:10.1002/lt.24738
54. Pflugrad H, Schrader A-K, Tryc AB, et al. Longterm calcineurin inhibitor therapy and brain function in patients after liver transplantation. *Liver Transplant*. 2018;24(1):56–66. doi:10.1002/lt.24984
55. Schoening W, Buescher N, Neidel N, et al. Cerebrovascular events in 20 years of follow-up after liver transplantation: an underestimated issue? *Clin Transplant*. 2016;30(10):1276–1282. doi:10.1111/ctr.12819

Hepatic Medicine: Evidence and Research

Dovepress

Publish your work in this journal

Hepatic Medicine: Evidence and Research is an international, peer-reviewed, open access journal covering all aspects of adult and pediatric hepatology in the clinic and laboratory including the following topics: Pathology, pathophysiology of hepatic disease; Investigation and treatment of hepatic disease; Pharmacology of drugs used for the

treatment of hepatic disease. Issues of patient safety and quality of care will also be considered. The manuscript management system is completely online and includes a very quick and fair peer-review system, which is all easy to use. Visit <http://www.dovepress.com/testimonials.php> to read real quotes from published authors.

Submit your manuscript here: <https://www.dovepress.com/hepatic-medicine-evidence-and-research-journal>