

# A rare case of brucellosis with dermatomal pattern of cutaneous manifestation

This article was published in the following Dove Press journal:  
*International Medical Case Reports Journal*

Naser Gharebaghi<sup>1</sup>  
Mojhdeh Mehrno<sup>2</sup>  
Amin Sedokani<sup>2</sup>

<sup>1</sup>Department of Infectious Disease, Faculty of Medicine, Urmia University of Medical Science, Urmia, Iran; <sup>2</sup>Student Research Committee, Urmia University of Medical Sciences, Urmia, Iran

**Abstract:** Brucellosis is a systemic disease which may involve any organ or system of the body, and is listed in the differential diagnosis of many diseases. In spite of described cutaneous involvements, skin manifestations are not common in brucellosis, particularly papulonodular lesions with dermatomal patterns that may overlap with dermatomal skin lesions. This may prevent correct diagnosis and treatment in practice, harming patients' health and leading to financial costs to the health system and patient. In this case, at first, due to left thigh and buttock skin lesions and dermatomal pattern, the patient was diagnosed with *Herpes zoster* infection. After medical treatment and no improvement of lesions, the patient was referred to the infectious clinic with low back pain; magnetic resonance imaging (ordered by a neurosurgeon) suggested infectious spondylodiscitis. At the infectious ward, brucellosis spondylitis was diagnosed and a biopsy was taken from dermatomal lesions. The patient's follow-up after 1, 2, and 3 months revealed that treatment of brucellosis had led to healing of lesions. Surprisingly, the histopathological assessment of the biopsy suggested psoriasis vulgaris. This was a rare case of manifestation of cutaneous brucellosis which could not even be diagnosed by histopathological assessment.

**Keywords:** brucellosis, cutaneous manifestations, dermatomal pattern, psoriasis

## Introduction

Brucellosis is the most common zoonotic bacterial infection worldwide with endemic patterns in some countries such as Iran, Turkey, Kuwait, Saudi Arabia, and Peru (most commonly seen in the Middle East, Central, and South America).<sup>1-3</sup> The disease is caused by *Brucella* species; a small, gram-negative, non-motile, non-spore-forming, intracellular-reproducing, aerobic coccobacilli microorganism that can survive inside macrophages due to specific survival mechanisms.<sup>1,4</sup> Dairy products contaminated with *Brucella melitensis* (mostly sheep and goat milk) seems to be the first main source of human brucellosis worldwide.<sup>5</sup> Brucellosis is a systemic disease and systemic infection may involve any organ or system of the body such as reticuloendothelial system (spleen, liver, bone marrow, and lymph nodes), gastrointestinal, central nervous system, cardiovascular, musculoskeletal, genitourinary, and integumentary systems.<sup>6,7</sup> Cutaneous involvement has also been described for brucellosis, but it is uncommon and unspecific.<sup>8</sup> Manifestations of cutaneous involvement have been described mostly as disseminated papulonodular eruption, erythema nodosum-like lesions, diffuse maculopapular rash, maculopapular eruptions, psoriasiform lesions, palmar erythema, malar eruption, and palmar eczema.<sup>9-11</sup> In summary, we can divide skin lesions associated with brucellosis into most frequent, such as papulonodular

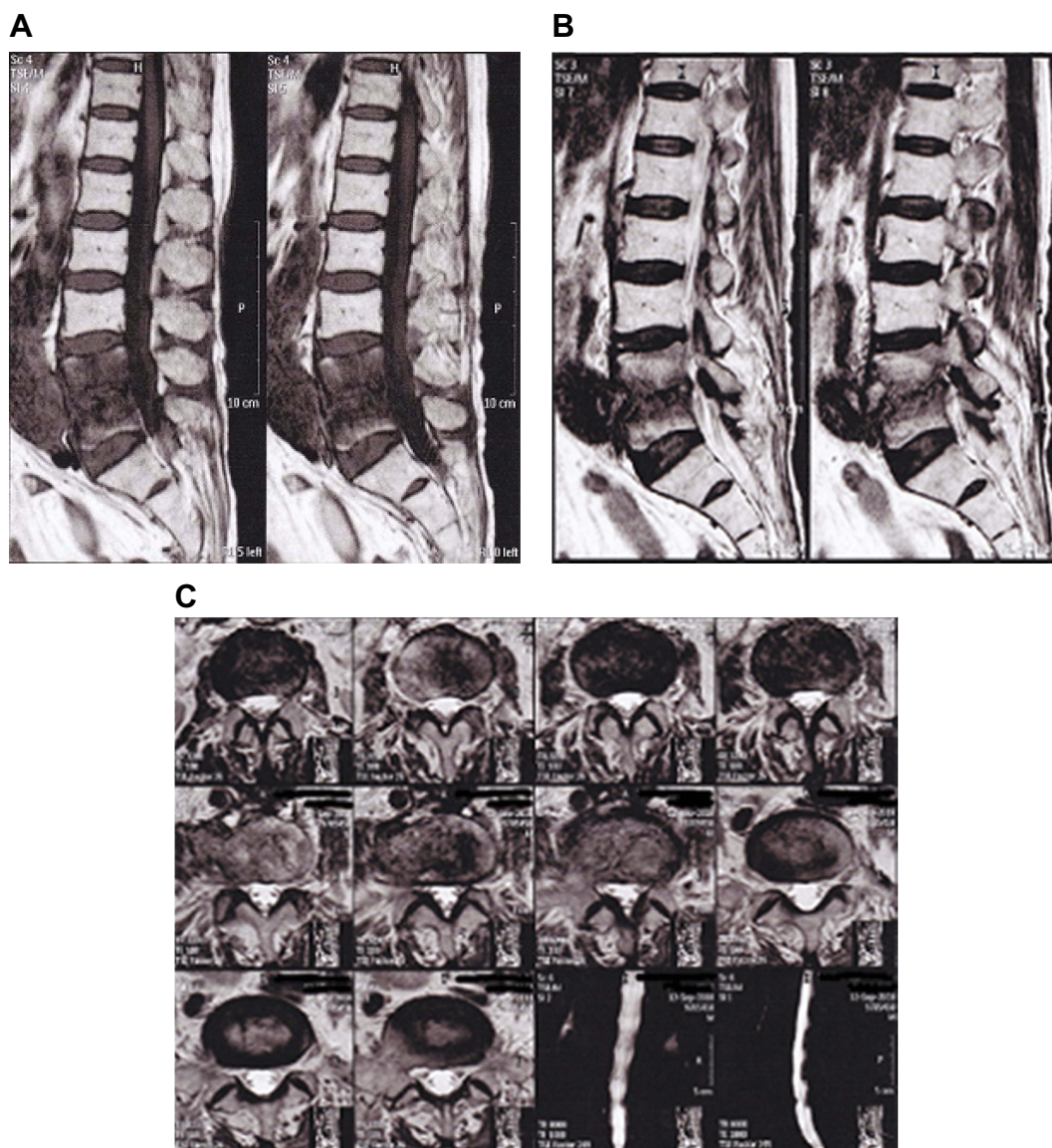
Correspondence: Amin Sedokani  
Student Research Committee, Urmia  
University of Medical Sciences, No. 6,  
Hezbollah St, 15<sup>th</sup> alley, Urmia 0098-  
5451738783, Iran  
Tel +98 914 324 1375/+98 443 344 4592  
Fax +98 414 422 7210  
Email a.sedoknai@gmail.com

lesions, erythema nodosum-like lesions, maculopapular eruptions, petechiae, purpura, and contact urticaria, and less frequent, such as vasculitic lesions, subcutaneous abscesses, chronic ulcerations, liquefactive panniculitis, recurrent epidermal cysts, palmar erythema, and livedo reticularis.<sup>12</sup>

## Case presentation

A 71-year old Iranian man was referred to the dermatology clinic of Ayatollah Taleghani Hospital of Urmia in September 2018. The patient had a history of visits to the neurosurgery department in August 2018 with a complaint of low back pain with non-specific clinical symptoms (tenderness without

radiculopathy), and lumbosacral/spine magnetic resonance imaging (MRI) without contrast was performed. MRI reported decrement in lumbar lordosis, extensive bone marrow edema at L4 and L5 vertebral bodies, and obliteration of L4-L5 disk. The appearance was “suspicious” for infectious spondylodiscitis (Figure 1A–C). At a visit to the dermatology department (September 2018), the patient’s chief complaint was patchy and vesicular plaque lesions on the anterior left thigh and the left buttock region, matching dermatomal pattern (L2-L5). Lesions appeared about 20 days before the visit and were not itchy, painful or exuding at first but gradually increased and became purulent. The patient was admitted to the dermatology ward with a diagnosis of *Herpes zoster* infection. The patient had a



**Figure 1** Lumbo-sacral spine magnetic resonance imaging. Sagittal TIW view of T12-L5 (A), Sagittal T2W view T12-L5 (B), and axial view of L3-L5 (C).



**Table 1** Biochemical laboratory data from dermatology ward admission

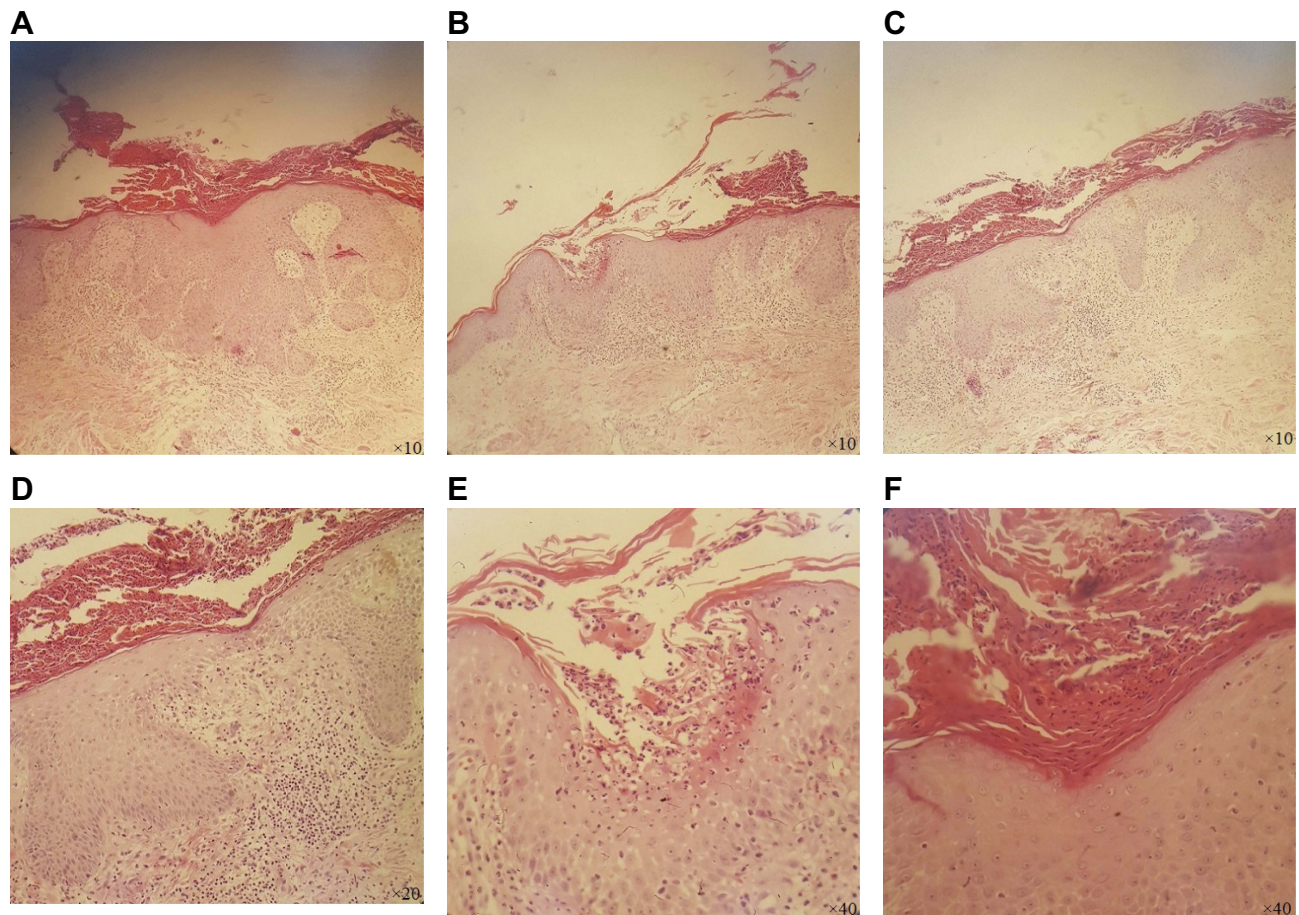
Laboratory data	Value	Normal reference range
Aspartate aminotransferase	14 U/L	<37 U/L
Alanine transaminase	12 U/L	<41 U/L
Alkaline phosphatase	252 U/L	80–360 U/L
Total bilirubin	0.4 mg/dL	0.1–1.2 mg/dL
Direct bilirubin	0.2 mg/dL	0.1–0.3 mg/dL
Fasting blood sugar	90 mg/dL	<92 mg/dL
Urea	28 mg/mL	19–44 mg/mL
Serum creatinine	1.1 mg/dL	—

history of smoking (20 packs/year), hypertension for the last 4 years, and underwent a laparotomy due to perforated peptic ulcer 2 years ago. He was taking losartan 25 mg BID for hypertension. The biochemical laboratory data on admission are reported in Table 1. Complete blood count revealed white blood cell count of 5,400/mL (neutrophil: 60%, lymphoid: 33%,

**Table 2** Biochemical laboratory data from infectious disease ward admission

Laboratory data	Value	Reference normal range
Serum creatinine	0.9 mg/dL	—
Serum urea	21 mg/mL	19–44 mg/mL
Random blood sugar	142 mg/dL	<200 mg/dL
Serum K	4 mEq/L	3.5–5 mEq/L
Serum Na	140 mEq/L	135–145 mEq/L
Carcinoembryonic antigen	1.1 ng/mL	Smokers 0.4–8.5 ng/mL
Alpha-fetoprotein	2.7 ng/mL	0.2–8.5 ng/mL
Erythrocyte sedimentation rate 1 hour	9 mm/hour	<20 mm/hour
Qualitative C-reactive protein	4 <sup>+</sup>	—

and MXD: 7%), red blood cell count of 3.46 million/mL, hemoglobin of 9.9 gr/dL, hematocrit of 29.8%, mean corpuscular volume of 86.13 fl, and platelet count of 284,000/mL. During admission the patient was afebrile. The patient was

**Figure 2** Histopathological view of lesion biopsy, acanthosis with elongation of rete ridges and thickening of lower portion, parakeratosis with perivascular infiltration of lymphoid cells (A–F).

discharged after 3 days of hospitalization with medical therapy of cephalexin capsules 500 mg QID and gabapentin. The lesions had improved relatively during hospitalization but were not completely resolved.

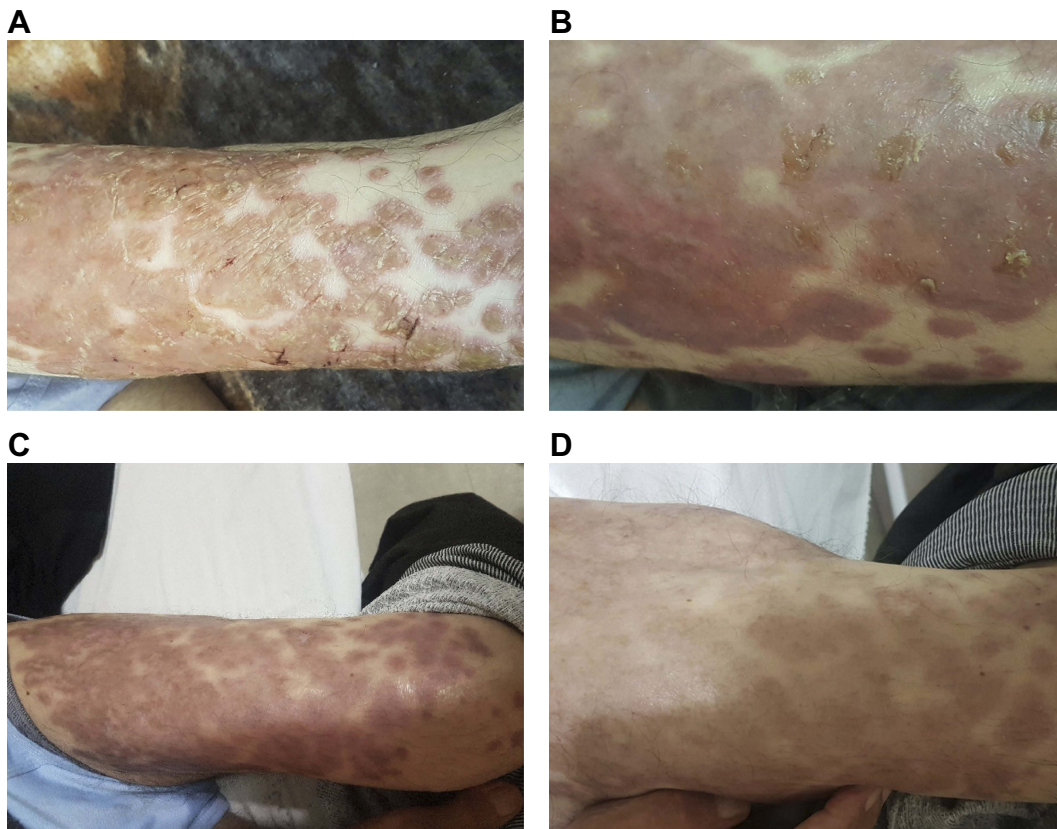
Forty-five days later, in October 2018, the patient was referred to the infectious clinic of Ayatollah Taleghani hospital with a major complaint of low back pain and unimproved skin lesions.

The patient's low back pain started about 3 months earlier (early August 2018), it was initially low and gradually increased. The pain was continuous, increasing with activity and decreasing with rest. There were no other symptoms such as nausea, vomiting, coughing, and shortness of breath. He had had low-grade fever for about 2 weeks and also had a history of unpasteurized cheese consumption.

At the visit to the infectious disease clinic, the patient had itchy, patchy, and vesicular plaque lesions on the anterior left thigh and the left buttock region. There was no active or passive movement limitation on examination. Nervous examinations were normal. There was no lymphadenopathy.

Considering clinical symptoms, the history of unpasteurized cheese consumption, and the MRI report (Figure 1A–C), the patient was admitted to the infectious disease ward of Ayatollah Taleghani hospital for further investigation and probable diagnosis of brucellosis spondylitis. The laboratory data on admission were reported as (biochemical laboratory data are reported in Table 2) complete blood count revealed: white blood cell count of 7,600/ $\mu$ L (neutrophil: 65%, lymphoid: 31%, MXD: 2%, and monocytes: 2%), red blood cell count of 3.94 million/ $\mu$ L, hemoglobin of 11 gr/dL, hematocrit of 34%, mean corpuscular volume of 86.29 fl, and platelet count of 290,000/ $\mu$ L. Coombs anti-Brucella and Wright test was done and the antibody titers were 1/1,280 and 1/640 respectively.<sup>13,14</sup>

By considering clinical symptoms and paraclinical assessments, the diagnosis of brucellosis was confirmed and medical therapy of gentamycin 80 mg QID, doxycycline 100 mg BID, and rifampin 300 mg BID was begun. For pain management, 100 mg of gabapentin BID was



**Figure 3** (A) The patchy and vesicular plaque lesions with dermatomal pattern on anterior left thigh at first day of admission and treatment. (B) Skin lesions after 1 month of treatment. (C) Healed skin lesions at 2 months after treatment. (D) Vanished papulovesicular lesions and effading pigmented macula and patches at the end of third month after treatment.



prescribed and for itching and redness, topical 0.025% fluocinolone ointment TDS.

On the second day of admission, a skin lesion biopsy was done. Two weeks after the biopsy, histopathological assessment showed parakeratosis with spongiform pustule and Munro abscess, acanthosis with elongation of rete ridges and thickening of lower portion, perivascular infiltration of lymphoid cells, and exocytosis. The final histopathological diagnosis from the pathologist was compatible with psoriasis vulgaris (Figure 2).

Back pain gradually decreased during admission after medical treatment for brucella was started. On the third day of admission, subjectively; the patient's pain during walking had improved. Figure 3 shows gross healing process and regression of skin lesions on admission, and at the end of first, second, and third month after beginning treatment.

## Conclusion

Brucellosis is a disease with several clinical symptoms and various organ involvement and is listed in the differential diagnosis list of many diseases. Chronic brucellosis can involve the spinal cord in the form of spondylitis and spondylodiscitis that can cause fractures and even serious neurological complications. Skin manifestations are not common in brucellosis, particularly papulonodular lesions with dermatomal patterns; as seen in this case, cutaneous involvement can mimic diseases with a dermatomal pattern of involvement such as *Herpes zoster* infection. Even on histopathological assessment, the disease could mimic pemphigus vulgaris and pemphigoid lesions. By diagnosis of brucellosis through clinical and paraclinical assessment and beginning treatment, the lesions started to heal and had vanished by 3 months after the first day of treatment. This case showed a rare condition of cutaneous involvement of brucellosis that can mimic dermatomal gross pattern and pemphigoid lesions on histopathological assessment.

## Ethical statement

The patient provided written informed consent to have the case details and any accompanying images published and

the ethics committee of Ayatollah Taleghani University Hospital and Urmia University of Medical Sciences provided their approval to publish the case details. The patient had the opportunity to refuse. The patient's personal information remained confidential. There was no cost or harm to the patient as a result of the study.

## Disclosure

The authors report no conflicts of interest in this work.

## References

1. Franco MP, Mulder M, Gilman RH, Smits HL. Human brucellosis. *Lancet Infect Dis.* 2007;7(12):775–786. doi:10.1016/S1473-3099(07)70286-4
2. Güngör K, Bekir N, Namiduru M. Ocular complications associated with brucellosis in an endemic area. *Eur J Ophthalmol.* 2002;12(3):232–237.
3. Pappas G, Papadimitriou P, Akritidis N, Christou L, Tsianos EV. The new global map of human brucellosis. *Lancet Infect Dis.* 2006;6(2):91–99. doi:10.1016/S1473-3099(06)70382-6
4. Ugalde RA. Intracellular lifestyle of *Brucella* spp. Common genes with other animal pathogens, plant pathogens, and endosymbionts. *Microb Infect.* 1999;1(14):1211–1219.
5. Seleem MN, Boyle SM, Sriranganathan N. Brucellosis: a re-emerging zoonosis. *Vet Microbiol.* 2010;140(3–4):392–398. doi:10.1016/j.vetmic.2009.06.021
6. Buzgan T, Karahocagil MK, Irmak H, et al. Clinical manifestations and complications in 1028 cases of brucellosis: a retrospective evaluation and review of the literature. *Int J Infect Dis.* 2010;14(6):e469–e78. doi:10.1016/j.ijid.2009.06.031
7. Colmenero JD, Reguera JM, Martos F, et al. Complications associated with *Brucella melitensis* infection: a study of 530 cases. *Medicine (Baltimore).* 1996;75(4):195–211. doi:10.1097/00005792-199607000-00003
8. Balabanova-Stefanova M, Starova A, Arsovska-Bezhoska I. Cutaneous manifestations of brucellosis. *Maced J Med Sci.* 2010;3(3):257–262. doi:10.3889/MJMS.1857-5773.2010.0130
9. Turunç T, Kurşun E, Demiroğlu YZ, Alışkan E. Bruselloza Bağlı Nadir Görülen Tutulum ve Komplikasyonlar ile Seyreden 46 Olgunun Değerlendirilmesi. *Croat Med J.* 2014;39(4). doi:10.17826/cutf.52311
10. Metin A, Akdeniz H, Buzgan T, Delice I. Cutaneous findings encountered in brucellosis and review of the literature. *Int J Dermatol.* 2001;40(7):434–438.
11. Akcali C, Savas L, Baba M, Turunc T, Seckin D. Cutaneous manifestations in brucellosis: a prospective study. *Adv Ther.* 2007;24(4):706–711.
12. Korkmaz P, Kartal ED. Skin manifestations associated with brucellosis. *EMJ Dermatol.* 2016;4:119–125.
13. Wilson M, Merrifield E. The antiglobulin (Coombs) test in brucellosis. *Lancet.* 1951;258(6690):913–914. doi:10.1016/S0140-6736(51)91875-2
14. Weight AE. On the application of the serum test to the differential diagnosis of typhoid and Malta fever: and on the further application of the method of serum diagnosis to the elucidation of certain problems in connexion with the duration of immunity and the geographical distribution of disease. *The Lancet.* 1897;149(3836):656–659.

### International Medical Case Reports Journal

Dovepress

#### Publish your work in this journal

The International Medical Case Reports Journal is an international, peer-reviewed open-access journal publishing original case reports from all medical specialties. Previously unpublished medical posters are also accepted relating to any area of clinical or preclinical science. Submissions should not normally exceed 2,000 words or 4

published pages including figures, diagrams and references. The manuscript management system is completely online and includes a very quick and fair peer-review system, which is all easy to use. Visit <http://www.dovepress.com/testimonials.php> to read real quotes from published authors.

Submit your manuscript here: <https://www.dovepress.com/international-medical-case-reports-journal-journal>