

Awake tracheostomy in a patient with acute upper airway obstruction: an emergency application of an elective percutaneous procedure

This article was published in the following Dove Press journal:
Open Access Emergency Medicine

Pierluigi Fusco
Angela Iuorio
Mirco Della Valle
Fausto Ferraro

Dipartimento Della Donna, Del Bambino,
Della Chirurgia Generale e Specialistica,
Università Degli Studi Della Campania
Luigi Vanvitelli, Naples, IT 80138, Italy

Abstract: Since its introduction in 1985 with Ciaglia, percutaneous tracheostomy (PT) was contraindicated in emergency settings and obesity. However, several case series in the last 20 years have documented the use of PT in life-threatening airway emergencies. We present a case of severe acute airway obstruction in a 66-year-old woman successfully treated with a placement of an awake PT. The woman's glottic obstruction was caused by a recurrent laryngeal neoplasia and revealed by nasoendoscopy. This acute condition required a serious effort from the patient to oxygenate and therefore prevented orotracheal intubation as well as the use of any supraglottic device and/or sedation. Blood aspiration after a first attempt to make a quick access to the tracheal lumen with an emergency cricothyroidotomy, and difficulties in the exact identification of tumor infiltration, led us to perform an awake tracheostomy. Due to elevated risk of airway bleeding, we started with a surgical approach to better identify anatomical structures. After the correct inter-tracheal ring space identification, sudden worsening of clinical symptoms required that we complete the procedure quickly with the aid of a Ciaglia Blue Rhino™-Cook (CBR) tracheostomy kit. At the tracheostomy tube placement, the patient quickly resolved her dyspnea and physiological breathing was restored.

Keywords: emergency, hypoxia, tracheostomy

Background

Cricothyroidotomy is actually the gold standard to emergency airway access. However, there are particular cases in which this approach cannot be adopted. Tracheostomy is considered an elective procedure for long-term airway management but is not indicated in emergency settings because it is considered a time-consuming procedure and often too slow to resolve the acute difficulty.¹ Several case series on the use of percutaneoustracheostomy (PT) in emergency conditions reports that the technique is safe and feasible¹⁻³ even in trauma patients without hyperextension of the neck.¹ We describe our experience with successful placement of awake PT for emergency airway control. Acquisition of technical skills in non-emergency settings is crucial.

As the data reported is related to a single case study, specific-informed consent for publication of the case details was obtained. No institutional approval was required to publish the case details. A written informed consent for the procedure was obtained from the patient as required. The authors declare that there is no conflict of interest regarding the publication of this article.

Correspondence: Fausto Ferraro
Università Degli Studi Della Campania
Luigi Vanvitelli, Dipartimento Della
Donna, Del Bambino, Della Chirurgia
Generale e Specialistica, Piazza Miraglia, 2
Naples, IT 80138, Italy
Tel +39 335 523 7900
Email fausto.ferraro3@gmail.com

Case presentation

A 66-year-old woman was admitted to our ICU with acute respiratory failure related to acute upper airway obstruction. The patient was hospitalized in the general surgery department of our Institution waiting for preventive pre-radiation tracheostomy for recurrent laryngeal tumor. Five years earlier, she had undergone esophagectomy and esophagogastroplasty for esophageal squamous cell carcinoma. On admission, she was choking, agitated, cyanotic, dyspneic, with massive aid of accessory muscles and inspiratory stridor.

Oxygenation with 100% oxygen was immediately delivered through face mask. After local anesthesia and premedication (atropine 0.5 mg + midazolam 1 mg) were administered, the patient underwent to nasoendoscopy. Fiberoptic laryngeal examination revealed a vegetant and

infiltrative tough mass filling the airway at the glottis causing sub-total airway obstruction (Figure 1); edema and hyperemia of the mucosa with abundant secretions of mucus and blood; and hyperreflexia.

Because of the worsening of clinical conditions, we decided to secure the airway performing open surgical tracheostomy. We chose surgical tracheostomy instead of percutaneous dilatational tracheostomy (PDT) to best evaluate the mass, being impossible to insert the flexible bronchoscope into the trachea to perform a video-assisted PDT.

We obtained the informed consent from the patient's relatives and only oral consent from the patient, considering the gravity of the situation. The whole intervention was carried out in local anesthesia, given the need of the patient collaboration.

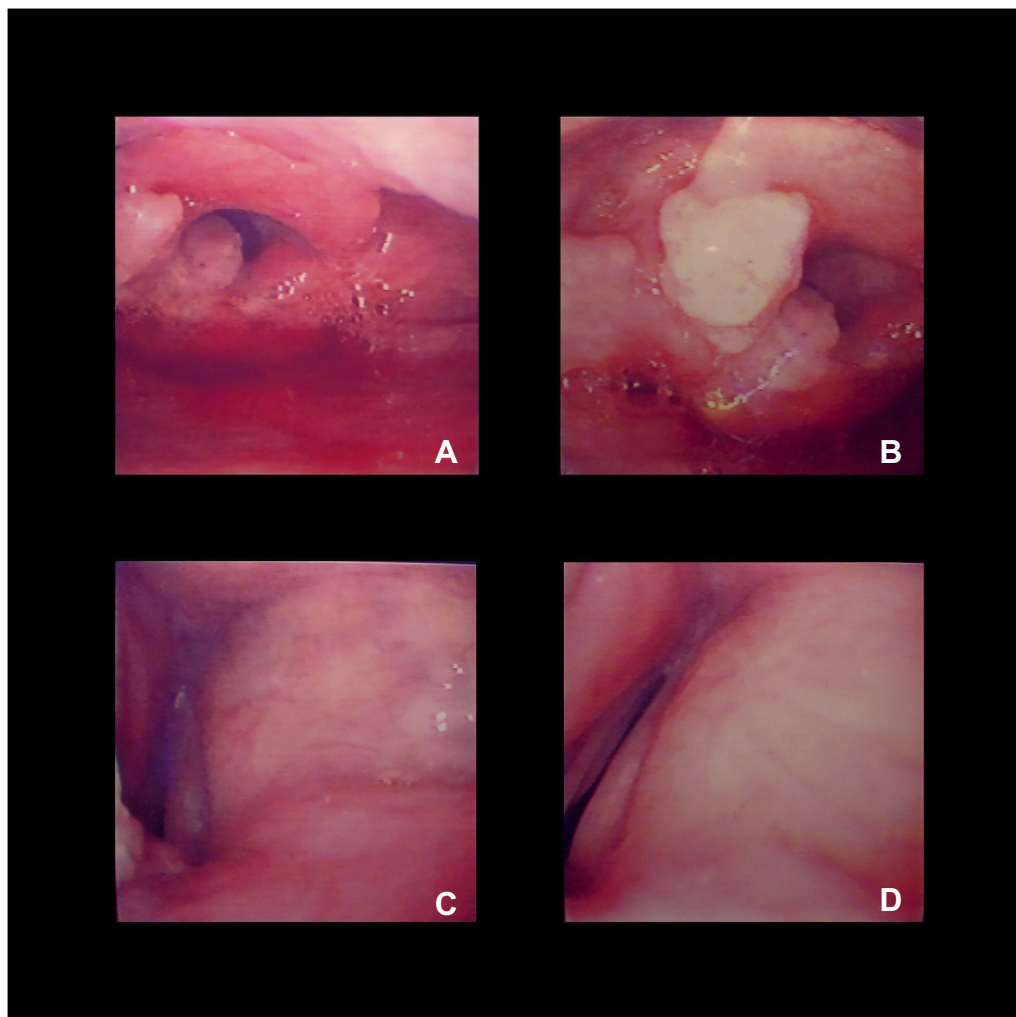


Figure 1 Nasoendoscopy in acute dyspneic hypoxia with stridor. Top left, (A) glottis edema and hyperemia with laryngeal mass filling the airway; top right, (B) a vegetant and tough mass infiltrating the epiglottis and left arytenoid causing sub-total airway obstruction; bottom left, (C) obstructive edema of the true and false right vocal cords; and bottom right, (D) obstruction of the laryngeal aditus with vocal cords in blocked adduction.

SpO₂ values were kept constant thanks to a nasal trumpet (oxygen FiO₂:1) placed to oxygenate the patient during the intervention, and to the patient's great effort, who appeared sweaty and with *tirage*. Once at level of the anterior wall of trachea, the worsening of symptoms and the appearance of cough, although with stable SpO₂ rate, threatened the oxygenation of the patient. Because of the elevated risk of bleeding into the airway caused by surgical incision of the neoplastic trachea and the further risk of worsening of general condition, we decided to accelerate in securing the airway completing the procedure with a CBR kit.

The tracheal interspace between the second and third ring was identified. After puncturing the space with the needle, a guidewire was inserted easily and without any resistance; a single, beveled, curve dilator was passed on the guidewire and a 7 mm inner diameter tracheostomy tube was inserted through the stoma.

As the tracheostomy tube was placed, a dramatic improvement in the patient's condition was immediately seen: stridor and dyspnea ended both; breathing was spontaneous on ambient air with normal SpO₂ values.

An endoscopic control through the tracheostomy tube was carried out. The patient stayed in ICU for the night and then was transferred to the general surgery department. Five days later, the tracheal tube was substituted with a Shiley dual-cannula tube and phonetic valve.

Discussion

Upper airway obstruction requiring rapid access to the trachea is uncommon, but when it does occur it is a life-threatening condition that necessitates immediate action.¹ Guidelines for difficult airways management^{4,5} pertain to failed intubation and extubation and cannot be applied to cases of airways obstruction. In case of "cannot ventilate/cannot intubate" settings, a variety of supraglottic devices have been developed as an alternative to tracheal intubation, but in case of supraglottic or glottic obstruction, the only way is reduced to the quick access to the tracheal lumen. At present, there are no guidance or shared management for this specific occurrence. A recent work of Lynch and Crawley⁶ underlines the importance of maintaining a good oxygenation and the important role of high-flow nasal cannulae in these conditions. At the same time, they highlight that the management is highly context-sensitive.⁶

Currently, there is no accordance for the use of tracheostomy as an alternative for emergency airway management because it is considered a time-consuming procedure, too

slow to resolve the acute difficult airway. A surgical cricothyroidotomy should be considered as the technique of choice, especially in cases of hypoxemia.⁶

However, there are several clinical circumstances in which cricothyroidotomy could present some difficulties or contraindication, such as impossible visual or digital recognition of the cricoid cartilage, tumor mass, anatomical abnormalities. In these cases, emergency tracheostomy could represent the only solution to secure the airway. Other theoretical advantages of PDT in these settings include the fact that it is an effective airway for ventilation, suctioning and bronchoscopy; mitigates the damage to vocal cords and does not require conversion in a more stable airway.⁷

In our case, after a diagnosis confirmation of glottic obstruction by nasoendoscopy, we first approached to the difficult airway quickly accessing by a cricothyroid puncture, but the tumor extension prevented from pursuing this approach. Any accidental puncture of this formation would have caused a high bleeding risk, with subsequent blood aspiration in the airways. Also, induction of general anesthesia in combination with the administration of neuromuscular blocking agents was excluded, because we would have lost the accessory respiratory muscles aid, highly involved in winning the obstruction. Due to this elevated risk of bleeding, together with difficulties in the exact identification of cricoid cartilage caused by tumor disruption and the risk of a cannula kinking placed in these conditions, we decided to perform an awake PT starting with a surgical approach for a better identification of anatomical structures. After the correct inter-tracheal ring space identification, sudden worsening of clinical symptoms imposed to complete the procedure quickly with the aid of a CBR tracheostomy kit. The use of a PDT kit was also recommended in order to minimize the bleeding into the airway, dilating without cutting. Our familiarity with the procedure, gained in elective settings, allowed us to easily pass from a surgical to a percutaneous approach and to secure the airway in a short time without endoscopic surveillance. At present, the largest retrospective study on the use of PT in emergency settings involved 18 patients. These patients were successfully treated with the CBR kit.² Other encouraging reports are shown with the Griggs technique.⁸⁻¹⁰ We believe that in trained hands emergency PDT is a safe alternative to cricothyroidotomy in case of acute glottic obstruction with stable SpO₂ values. Its role in emergency settings should be reviewed even in a context of specific guidelines. We also emphasize the role of training of these procedures routinely.

Learning points

According to the literature, this case suggests that PT, operated by an expert team, could be a safe practice for emergency airways management in laryngeal neoplastic obstruction, ensuring at the same time airways oxygenation quickly and definitely.

Author contributions

All authors contributed towards data analysis, drafting and critically revising the paper, gave final approval of the version to be published, and agreed to be accountable for all aspects of the work.

Disclosure

The authors report no conflicts of interest in this work.

References

1. Klein M, Weksler N, Kaplan DM, Weksler D, Chorny I, Gurman GM. Emergency percutaneous tracheostomy is feasible in experienced hands. *Eur J Emerg Med.* 2004;11:108–112.
2. Davidson SB, Blostein PA, Walsh J, Maltz SB, VandenBerg SL. Percutaneous tracheostomy: a new approach to the emergency airway. *J Trauma Acute Care Surg.* 2012;73(2 Suppl 1):S83–8. doi:10.1097/TA.0b013e3182606279
3. Schmitz S, Boven MV, Hamoir M. Percutaneous tracheostomy in emergency situation setting. *Ann Otolaryngol Rhinol.* 2015;2:1028.
4. Gruppo di studio SIAARTI. Vie aeree difficili. *Minerva Anesthesiol.* 2005;71:617–657.
5. Frerk C, Mitchell VS, McNarry AF, et al. Difficult airway society 2015 guidelines for management of unanticipated difficult intubation in adults. *Br J Anaesth.* 2015;115(6):827–848. doi:10.1093/bja/aev371
6. Lynch J, Crawley SM. Management of airway obstruction. *BJA Educ.* 2018;18(2):46–51. doi:10.1016/j.bjae.2017.11.006
7. Ault MJ, Ault B, Ng PK. Percutaneous dilatational tracheostomy for emergent airway access. *J Intensive Care Med.* 2003;18(4):222–226. doi:10.1177/0885066603254108
8. Dob DP, McLure HA, Soni N. Failed intubation and emergency percutaneous tracheostomy. *Anaesthesia.* 1998;53:69–78.
9. Clarke J, Jaffery A. How we do it: emergency percutaneous tracheostomy: a case series. *Clin Otolaryngol.* 2004;29:558–561. doi:10.1111/j.1365-2273.2004.00845.x
10. Schlossmacher P, Martinet O, Testud R, Agesilas F, Benhamou L, Gauzère BA. Emergency percutaneous tracheostomy in a severely burned patient with upper airway obstruction and circulatory arrest. *Resuscitation.* 2006;68(2):301–305. doi:10.1016/j.resuscitation.2005.06.021

Open Access Emergency Medicine

Dovepress

Publish your work in this journal

The Open Access Emergency Medicine is an international, peer-reviewed, open access journal publishing original research, reports, editorials, reviews and commentaries on all aspects of emergency medicine. The manuscript management system is completely online

and includes a very quick and fair peer-review system, which is all easy to use. Visit <http://www.dovepress.com/testimonials.php> to read real quotes from published authors.

Submit your manuscript here: <https://www.dovepress.com/open-access-emergency-medicine-journal>