

# Cervical intradural disc herniation with Brown-Séguard syndrome: case report and literature review

This article was published in the following Dove Press journal:  
*Journal of Pain Research*

Yuluo Rong\*  
Jiaying Wang\*  
Tao Sui  
Wei Liu  
Yongjun Luo  
Weihua Cai

Department of Orthopaedics, First  
Affiliated Hospital of Nanjing Medical  
University, Nanjing 210029, Jiangsu,  
People's Republic of China

\*These authors contributed equally to  
this work

**Objective:** To report a rare case of cervical intradural disc herniation (IDH) with Brown-Séguard syndrome and to review the related literature.

**Methods:** Pathogenesis, preoperative diagnosis, and the surgical technique are discussed, and previous literature reports are reviewed.

**Results:** A 44-year-old woman complained of weakness of the left upper and lower extremities and paresthesias in the right limbs after a bicycle ride 3 days earlier. She had a history of neck pain for 2 years prior. CT showed obvious ossification of the posterior longitudinal ligament (OPLL), and MRI revealed C3-7 disc herniations, with a positive “halo sign” around the herniated C4/5. We performed emergency decompression through anterior cervical corpectomy, and vertebroto my decompression and fusion. At review 3 months after surgery, the patient's neck pain was markedly relieved, and motor strength in the limbs had improved. At 1 year after surgery, she had recovered completely.

**Conclusion:** Cervical IDH is a rare condition that may be related to the traumatic inflammatory response and OPLL. Relatively rare imaging features such as the hawk-beak sign, halo sign, Y sign, and epidural gas sign could help in preoperative diagnosis. Prompt anterior cervical decompression is the preferred treatment for this condition.

**Keywords:** cervical intradural disc herniation, Brown-Séguard syndrome, ossification of posterior longitudinal ligament, cerebrospinal fluid leakage, surgical treatment

## Introduction

Intradural disc herniation (IDH) is a rare condition that mostly occurs in the lumbar spine (92%); about 5% of cases occur in the thoracic spine, and 3% in the cervical spine.<sup>1,2</sup> More than 100 cases of lumbar IDHs have been reported since the first description by Dandy et al in 1942.<sup>3</sup> The first case of cervical IDH was reported in 1959.<sup>4</sup> The pathogenetic mechanism of cervical IDH is unclear, but ossification of the posterior longitudinal ligament (OPLL) and trauma are probably involved.<sup>5</sup>

In 2010, Hsieh et al<sup>6</sup> reported a patient with OPLL who developed cervical IDH after spinal manipulation. Wang et al and Baudracco et al have reported spontaneous cervical IDH in patients with OPLL.<sup>5,7</sup> In this article, we report a woman with OPLL who developed cervical IDH and Brown-Séguard syndrome following minor trauma. We also briefly review all cases of cervical IDH reported to date (Table 1). Written informed consent was obtained from the patient to publish the

Correspondence: Weihua Cai  
Department of Orthopaedics, First  
Affiliated Hospital of Nanjing Medical  
University, 300 Guangzhou Road, Gulou  
Qu, Nanjing 210029, Jiangsu, People's  
Republic of China  
Tel +86 1 395 166 1018  
Email caiwhspine@sina.com

**Table 1** Summary of reported cases with intradural cervical disc herniation

Case (Authors and Publication year)	Sample	Gender	Age (y)	Level of herniation	History of trauma	Association with OPPL	BSS present	HS present	Surgical Approach	Follow-up outcome
Marega et al 1959 <sup>4</sup>	1	M	41	C5/6	No	N/A	No	Yes	Posterior laminectomy	Residual symptoms
Dürig et al 1977 <sup>8</sup>	1	F	52	C5/6	NO	N/A	Yes	Yes	Posterior laminectomy	Disability
Roda et al 1982 <sup>9</sup>	1	M	43	C6/7	NO	N/A	Yes	No	Posterior hemilaminectomy	Residual symptoms
Caetano de Barros et al 1984 <sup>10</sup>	1	M	24	C3/4	Yes	N/A	No	No	Anterior discectomy	Full recovery
Jomin et al 1985 <sup>11</sup>	1	M	42	C4/5	Yes	N/A	NO	NO	Anterior discectomy	Full recovery
Eisenberg et al 1986 <sup>12</sup>	1	M	25	C5/6	NO	NO	Yes	No	Posterior laminectomy	Residual symptoms
Lechowski et al 1986 <sup>13</sup>	1	M	N/A	C5/6	Yes	N/A	N/A	N/A	N/A	Residual symptoms
Vernay et al 1986 <sup>14</sup>	1	M	N/A	C5/6	N/A	N/A	N/A	N/A	N/A	N/A
Schneider et al 1988 <sup>15</sup>	1	F	50	C5/6	NO	NO	Yes	No	Anterior discectomy	Residual symptoms
Parnell et al 1988 <sup>16</sup>	1	M	47	C5/6	Yes	NO	Yes	No	Anterior discectomy	Full recovery
Destee et al 1989 <sup>17</sup>	1	M	31	C5/6	Yes	NO	NO	NO	Anterior discectomy	Full recovery
Lee et al 1989 <sup>18</sup>	1	M	53	C6/7	Yes	NO	Yes	NO	Posterior laminectomy	Full recovery
Epstein et al 1990 <sup>19</sup>	1	M	38	C6/7	NO	N/A	NO	NO	Posterior hemilaminectomy	Full recovery
Sprick et al 1991 <sup>20</sup>	1	F	49	C6/7	NO	N/A	Yes	Yes	Anterior discectomy	Minor deficits
Özer et al 1994 <sup>21</sup>	1	F	36	C5/6	Yes	NO	NO	NO	Posterior laminectomy	Full recovery
Mihara et al 1998 <sup>22</sup>	N/A	N/A	N/A	N/A	N/A	N/A	N/A	N/A	N/A	N/A
Born et al 2000 <sup>23</sup>	1	M	40	C5/6	Yes	NO	Yes	NO	Anterior discectomy	Full recovery
Clatterbuck et al 2000 <sup>24</sup>	3	M	40	C4/5	NO	NO	Yes	NO	Anterior discectomy	Residual symptoms
		F	52	C3/4	NO	NO	Yes	NO	Anterior discectomy	Full recovery
		M	32	C5/6	NO	NO	Yes	NO	Anterior discectomy	Full recovery
Iwamura et al 2001 <sup>25</sup>	1	M	45	C6/7	NO	Yes	Yes	NO	Anterior (en bloc)	Residual symptoms
Neroni et al 2007 <sup>26</sup>	1	M	52	C6/7	NO	NO	NO	NO	Anterior discectomy	Full recovery
Woischneck et al 2009 <sup>27</sup>	1	F	70	C7/T1	Yes	NO	NO	NO	Posterior laminectomy	Full recovery

(Continued)

Table 1 (Continued).

Case (Authors and Publication year)	Sample	Gender	Age (y)	Level of herniation	History of trauma	Association with OPLL	BSS present	HS present	Surgical Approach	Follow-up outcome
Heieh et al 2010 <sup>6</sup>	1	F	61	C3/4	Yes	NO	Yes	NO	Anterior discectomy	Full recovery
Kansal et al 2011 <sup>28</sup>	1	M	54	C5/6	Yes	NO	Yes	NO	Anterior discectomy	Full recovery
Pan et al 2011 <sup>29</sup>	2	F	50	C6/7	NO	NO	NO	NO	Anterior discectomy	Full recovery
Warade et al 2014 <sup>30</sup>	1	F	58	C4/5	NO	NO	NO	NO	Anterior discectomy	Residual symptoms
Wang et al 2014 <sup>5</sup>	1	M	64	C6/7	NO	NO	NO	NO	Anterior microdiscectomy	Disability
Yang et al 2016 <sup>1</sup>	1	M	32	C5/6	Yes	NO	NO	NO	Anterior discectomy	Full recovery
Mitchell et al 2016 <sup>31</sup>	1	F	80	C5/6	NO	NO	NO	NO	Anterior discectomy	Full recovery
Lian et al 2016 <sup>32</sup>	1	M	55	C3/4	Yes	NO	NO	NO	Anterior discectomy	Full recovery
Baudracco et al 2017 <sup>7</sup>	1	F	45	C4/5	NO	Yes	Yes	Yes	Anterior discectomy	Residual symptoms
Gunasekaran et al 2017 <sup>33</sup>	1	M	52	C7/T1	NO	NO	NO	NO	Posterior laminectomy	Full recovery
Brogna et al 2018 <sup>34</sup>	1	M	42	C4/5	NO	NO	Yes	NO	Anterior discectomy	Residual symptoms
Present case	1	M	44	C4/5	Yes	Yes	Yes	NO	Anterior discectomy	Full recovery

case details and the accompanying images. Institutional approval is not required to publish anonymized patient data.

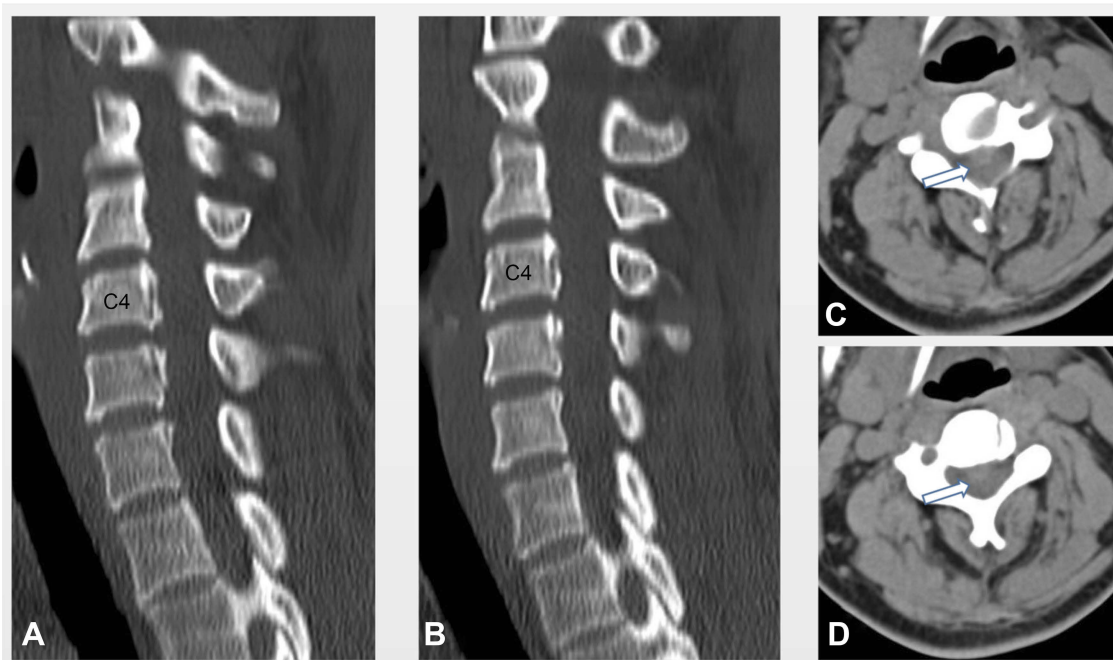
## Case report

A 44-year-old woman complained of weakness of the left upper and lower limbs and paresthesias in the right limbs after a bumpy bicycle ride 3 days earlier. She had a history of neck pain for 2 years prior. On physical examination, she had flaccid paralysis of the left limbs, with grade 0 muscle strength; sensation was normal. On the right side, she had grade 4 muscle strength, and total loss of pain and temperature sensation. There was no sphincter dysfunction. CT revealed C3-7 intervertebral disc herniations and OPLL (Figure 1). MRI showed C3-7 intervertebral disc herniations (most prominent at C3/4, C4/5, and C5/6) and marked compression of the dural sac (Figure 2). A “halo” was seen around the C4/5 level protrusion (Figure 2A). Based on the clinical features and imaging findings, our diagnosis was 1) cervical disc herniations (C3-7, with cervical IDH at C4/5); 2) Brown-Séquard syndrome (cervical myelopathy); and 3) cervical OPLL.

Surgery was performed under general anesthesia, with the aim of C3-6 anterior cervical discectomy and fusion (ACDF) or C4 anterior cervical corpectomy and fusion (ACCF) + C5/6 ACDF. The classic anterior cervical

approach was used. C5/6 was completely decompressed and an artificial bone cage (DePuy Synthes, MA, USA) was installed and filled. The C4/5 intervertebral disc was resected. The nucleus pulposus had protruded into the dura mater, and its removal was difficult because of tight adhesions between the dura and the posterior longitudinal ligament. Therefore, subtotal resection of C4 vertebra body was performed. After the nucleus pulposus was removed, a small break in the dura mater, with exudation of cerebrospinal fluid (CSF), was apparent (Figure 3A). The posterior longitudinal ligament was dissected free of the dura and resected. The dural tear was closed. A titanium mesh (Weigao, ShanDong, China) was then installed and filled with autologous bone. The vertebral body was fixed with a titanium plate and screws (Weigao, ShanDong, China).

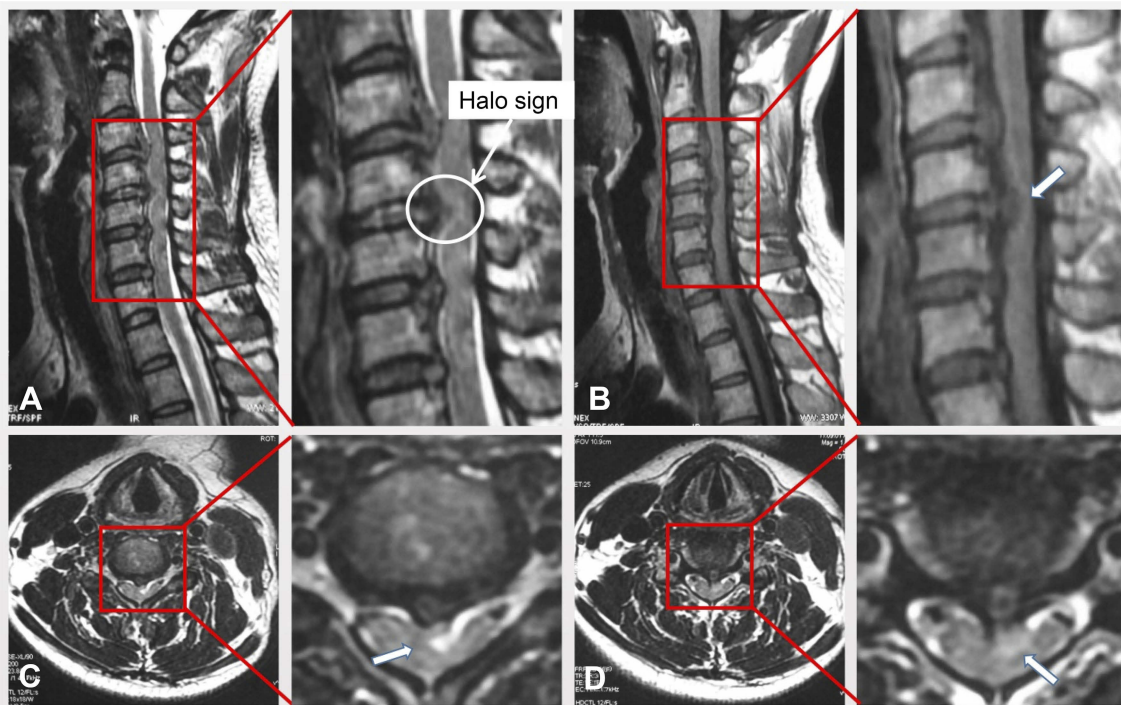
Postoperatively, the patient had obvious relief of symptoms. At review 3 months after surgery, muscle strength was normal but mild sensory abnormalities persisted. The shallow feeling of the right limb skin was slightly abnormal. Imaging showed stable internal fixation, satisfactory decompression of the surgical segment, and no compression of the dural sac (Figure 3B–D). At 1 year after surgery, the patient had recovered completely, with normal muscle strength on both sides and no paresthesias. Figure 4 shows the preoperative and follow-up radiographs.



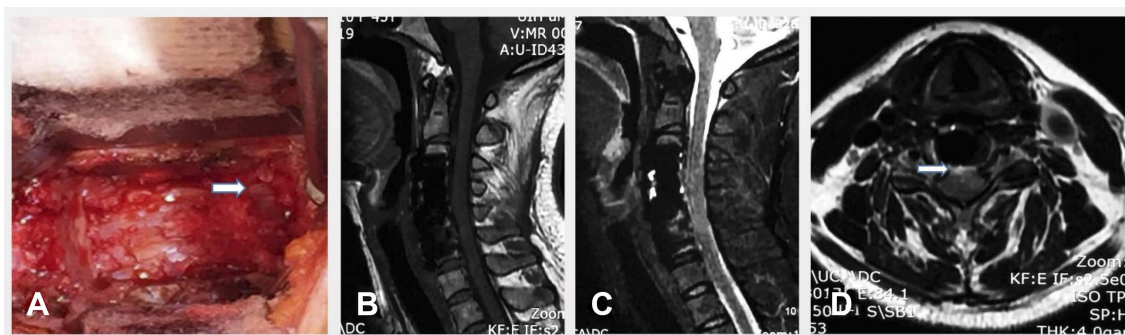
**Figure 1** Preoperative CT. (A, B) CT-scan sagittal reconstruction (bone windows). (A, D) CT-scan transverse cut at the C4-5 level. CT revealed disc herniation at C4-5 (arrow) and ossification of the posterior longitudinal ligament.

**Note:** N/A indicates not available.

**Abbreviations:** OPLL, ossification of posterior longitudinal ligament; BSS, Brown-Séquard syndrome; HS, Horner syndrome.



**Figure 2** Preoperative MRI. (A) T2-weighted images and b: T1-weighted images. Sagittal image of the cervical spine reveals large disc herniation at C3-C7 and C4-C5 with severe spinal cord compression. A “halo” of CSF isointensity surrounds the herniated disc (arrow). (C, D) Axial T2-weighted image of the cervical spine reveals large, central disc herniation at C4-C5 (arrow) with severe spinal cord compression and surrounding edema.



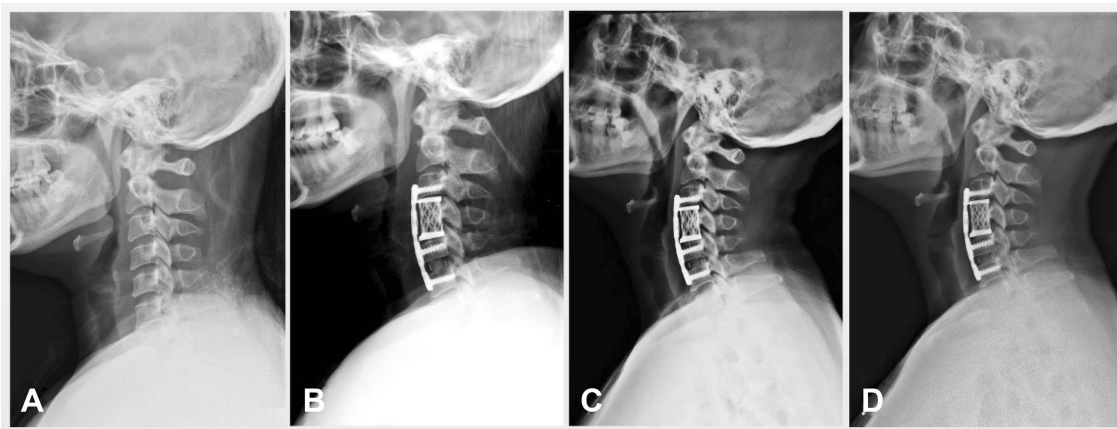
**Figure 3** Intraoperative photograph and sagittal and axial magnetic resonance images obtained 3 months postoperatively. (A) A small breach in the dura mater (white arrow) was seen after the removal of the nucleus pulposus. There was minimal cerebral spinal fluid leakage. T1-weighted (B) and T2 weighted (C, D) MR images reveal satisfactory segmental decompression and no compression of the dural sac (whitarrow).

## Discussion

Disc herniation usually occurs in the anterior epidural space; protrusion into the intradural space is unusual, especially for cervical disc herniation.<sup>34</sup> Cervical IDH is most common at C5/6, followed by C6/7.<sup>35</sup> Clinical manifestations include quadriplegia, paresthasias, and ataxia and, less often, radiculopathy.<sup>35,19</sup> Brown-Séquard syndrome (hemicord syndrome) and Horner syndrome are rare presenting symptoms.<sup>6,7,36</sup>

Definitive diagnosis of IDH depends on demonstration of dural rupture during surgery. MRI may show

intramedullary signals or intradural filling defects, but dural rupture is difficult to identify. However, four rare imaging signs should raise suspicion of cervical IDH: the hawk-beak sign, the halo sign, the Y sign, and the epidural gas sign. The hawk-beak sign—an abrupt termination of the posterior longitudinal ligament on MRI—was first described by Choi et al.<sup>37</sup> The halo sign presents as a rim of isointense signal in the CSF around the herniated disc in sagittal T2-weighted images.<sup>38</sup> The Y sign is caused by the herniated intervertebral disc peeling the arachnoid away from the dura mater, creating a “Y”



**Figure 4** Preoperative and postoperative follow-up radiographs; (A) lateral radiograph of the cervical spine shows absence of the physiological curvature, with degenerative changes in the cervical vertebrae. (B) Radiograph obtained 3 days after surgery shows partial restoration of the cervical curvature. (C) Radiograph obtained 3 months after surgery shows no displacement of internal fixation. (D) Radiograph obtained 1 year after surgery shows stable internal fixation.

shape on sagittal MR images.<sup>39</sup> The epidural gas sign (on CT) presents as gas in the epidural space.<sup>40</sup> According to Yang et al<sup>1</sup> the presence of the halo sign and the Y sign in MRI is strongly suggestive of cervical IDH. In our patient the halo sign was positive (Figure 2A).

Trauma and OPLL are believed to be important factors in the pathogenesis of IDH. Adhesions between the posterior longitudinal ligament and the dura mater are common,<sup>35</sup> and chronic adhesion may be the result of repeated trauma. Anatomical studies have demonstrated strong adhesions between the posterior longitudinal ligament and dura, with the C5/6 and C6/7 levels being most often involved;<sup>41</sup> this is consistent with the levels involved in our patient. OPLL, which has high prevalence in Asians (~2.4%), most commonly affects the cervical spine.<sup>42</sup> Mechanical irritation by the OPLL may lead to chronic inflammation of the adjacent dura mater, and subsequent scarring can result in adhesions between the dura and the posterior longitudinal ligament. The fragility of the dura mater and the posterior longitudinal ligament after adhesion is increased by stimulation. When this reaches to a certain extent, the protruding intervertebral disc may penetrate the posterior longitudinal ligament and the dura mater through accidental external force into the dura.

All previously reported patients were treated with surgery (Table 1), as it is the standard treatment for cervical IDH. Anterior surgery can directly enter the area of the diseased disc and facilitate removal of the protruding disc and repair of the dura. From previous reports, anterior bone graft fusion appears to be superior to posterior decompression (Table 1). Anterior

discectomy is the preferred treatment because it directly addresses the problem.<sup>43</sup> Vertebral resection may be required depending on the size and location of the compressed disc fragments and the degree of adhesion between the dura and the posterior longitudinal ligament. Our patient had OPLL and multisegment disc herniation, along with close adhesions between the posterior longitudinal ligament and the dura. We therefore chose discectomy and decompression plus subtotal corpectomy and bone graft fusion (ACDF + ACCF).

To summarize, cervical IDH is a rare condition, with pathogenesis probably related to the traumatic inflammatory response and OPLL. Preoperative diagnosis is difficult, but imaging signs such as the hawk-beak sign, halo sign, Y sign, and epidural gas sign can be useful indicators. Prompt anterior cervical decompression is the preferred treatment. In patients with cervical spine IDH accompanied by OPLL, the possibility of dural rupture should be kept in mind, adequate preoperative preparation made, and CSF leakage carefully looked for during surgery.

## Ethical approval

Ethical approval was not required for this study.

## Acknowledgments

This work was sponsored by the Wu Jieping Foundation (Grant No.320-2745-16-117).

## Disclosure

The authors report no conflicts of interest in this work.

## References

- Yang HS, Oh YM, Eun JP. Cervical intradural disc herniation causing progressive quadriplegia after spinal manipulation therapy: a case report and literature review. *Medicine*. 2016;95(6):e2797. doi:10.1097/MD.0000000000004864
- Madhugiri VS, Gundamaneni SK, Yadav AK, Sasidharan GM, Roopesh Kumar VR, Shankar Ganesh CV. Intradural thoracic disc presenting with radiculopathy. *Neurol India*. 2012;60(2):257–259. doi:10.4103/0028-3886.96435
- Dandy WE. Serious complications of ruptured intervertebral discs. *JAMA*. 1942;474–475. doi:10.1001/jama.1942.02830230008002
- Marega T, Komjanc G. Injury and hernia of the disk. *Minerva Ortop*. 1959;10:649–652.
- Wang D, Wang H, Shen WJ. Spontaneous cervical intradural disc herniation associated with ossification of posterior longitudinal ligament. *Case Rep Orthop*. 2014;2014:256207. doi:10.1155/2014/256207
- Hsieh JH, Wu CT, Lee ST. Cervical intradural disc herniation after spinal manipulation therapy in a patient with ossification of posterior longitudinal ligament: a case report and review of the literature. *Spine (Phila Pa 1976)*. 2010;35(5):E149–E151. doi:10.1097/BRS.0b013e3181bee8a7
- Baudracco I, Grahovac G, Russo VM. Spontaneous cervical intradural disc herniation presenting with Brown-Sequard and Horner's syndrome: lesson learned from a very unique case. *Eur Spine J*. 2017;26(Suppl 1):218–221. doi:10.1007/s00586-017-5044-4
- Durig M. Intradurale sequestration einer cervikalen diskushernie. ein kasuistischer beitrag[J]. *Arch Orthop Unfall Chir*. 1977;87:151–157.
- Roda JM, Gonzalez C, Blazquez MG, Alvarez MP, Arguello C. Intradural herniated cervical disc. Case report. *Journal of neurosurgery*. 1982;57:278–280.
- Caetano de Barros A, Caetano de Barros M. Traumatic extradural and intradural herniation of cervical disk treated surgically. *Surgical neurology*. 1984;21:577–580.
- Jomin M, Lesoin F, Wavreille A, Destee A, Gozet G. [Extra- and intradural cervical disk hernia. A case]. *Revue du rhumatisme et des maladies osteo-articulaires*. 1985;52:593–594.
- Eisenberg RA, Bremer AM, Northup HM. Intradural herniated cervical disk: a case report and review of the literature. *AJNR American journal of neuroradiology*. 1986;7:492–494.
- Lechowski S, Urbaniak J. [Intradural herniation of the intervertebral disk of the cervical segment of the spine]. *Neurologia i neurochirurgia polska*. 1986;20:589–591.
- Vernay D, Rampon S, Fraysse P, Cheminat JC, Irthum B, Clavelou P. [Extra- and intradural cervical hernia. A new case]. *Revue du rhumatisme et des maladies osteo-articulaires*. 1986;53:403.
- Schneider SJ, Grossman RG, Bryan RN. Magnetic resonance imaging of transdural herniation of a cervical disk. *Surgical neurology*. 1988;30:216–219.
- Parnell AP. Cervical intradural disc protrusion. *Journal of Neurology, Neurosurgery, and Psychiatry*. 1988;51:1007.
- Destee A, Lesoin F, Di Paola F, Warot P. Intradural herniated cervical disc associated with chiropractic spinal manipulation. *Journal of Neurology, Neurosurgery, and Psychiatry*. 1989;52:1113.
- Lee ST, Cheng SY, Lui TN. Intradural rupture of cervical intervertebral disc. *Spine (Phila Pa 1976)*. 1989;14:1412–1414.
- Epstein NE, Syrquin MS, Epstein JA, Decker RE. Intradural disc herniations in the cervical, thoracic, and lumbar spine: report of three cases and review of the literature. *Journal of spinal disorders*. 1990;3:396–403.
- Sprick C, Fegers S. [Intradural sequestration of cervical intervertebral disk displacement]. *Der Nervenarzt*. 1991;62:133–135.
- Ozer AF, Ozek MM, Pamir MN, Zirh TA, Erzen C. Intradural rupture of cervical vertebral disc. *Spine (Phila Pa 1976)*. 1994;19:843–845.
- Mihara H. Intradural disc herniation in the cervical spine: a case report[J]. *Kanto Seikei Saigai Gekagakkai*. 1998;29:27–32.
- Borm W, Bohnstedt T. Intradural cervical disc herniation. Case report and review of the literature. *Journal of neurosurgery*. 2000;92:221–224.
- Clatterbuck RE, Belzberg AJ, Ducker TB. Intradural cervical disc herniation and Brown-Sequard's syndrome. Report of three cases and review of the literature. *Journal of neurosurgery*. 2000;92:236–240.
- Iwamura Y, Onari K, Kondo S, Inasaka R, Horii H. Cervical intradural disc herniation. *Spine (Phila Pa 1976)*. 2001;26:698–702.
- Neroni M, Gazzeri R, Galarza M, Alfieri A. Intradural cervical disc herniation in a Klippel-Feil patient. *Spine (Phila Pa 1976)*. 2007;32: E608–610.
- Woischneck D, Schmitz B, Kapapa T. [First description of an intradural disc herniation at the C7-T1 level]. *Zeitschrift fur Orthopadie und Unfallchirurgie*. 2009;147:600–602.
- Kansal R, Mahore A, Kukreja S. Cervical intradural disc herniation and cerebrospinal fluid leak. *Neurology India*. 2011;59:447–450.
- Pan J, Li L, Qian L et al. Intradural cervical disc herniation: report of two cases and review of the literature. *Spine (Phila Pa 1976)*. 2011;36:E1033–1037.
- Warade AG, Misra BK. Spontaneous cervical intradural disc herniation. *J Clin Neurosci*. 2014;21:872–873.
- Mitchell BD, Verla T, Reddy D, Winnegan L, Omeis I. Reliable Intraoperative Repair Nuances of Cerebrospinal Fluid Leak in Anterior Cervical Spine Surgery and Review of the Literature. *World neurosurgery*. 2016;88:252–259.
- Lian F J, Chang C J. Cervical intradural disc herniation and intradural gas on CT scan[J]. *Fu-Jen J Med*. 2016;14:39–44.
- Gunasekaran A, de Los Reyes NKM, Walters J, Kazemi N. Clinical Presentation, Diagnosis, and Surgical Treatment of Spontaneous Cervical Intradural Disc Herniations: A Review of the Literature. *World neurosurgery*. 2018;109:275–284.
- Brogna C, Lavrador JP, Patel S, et al. Posterior longitudinal ligament and its implications in intradural cervical disc herniation: case report and review of the literature. *Surg Neurol Int*. 2018;9:119. doi:10.4103/sni.sni\_32\_18
- Guan Q, Xing F, Long Y, Xiang Z. Cervical intradural disc herniation: a systematic review. *J Clin Neurosci*. 2018;48:1–6. doi:10.1016/j.jocn.2017.10.024
- Ma H, Kim I. Horner syndrome associated with a herniated cervical disc: a case report. *Korean J Spine*. 2012;9(2):108–110. doi:10.14245/kjs.2012.9.2.108
- Choi JY, Lee WS, Sung KH. Intradural lumbar disc herniation—is it predictable preoperatively? A report of two cases. *Spine J*. 2007;7(1):111–117. doi:10.1016/j.spinee.2006.02.025
- Börm W, Bohnstedt T. Intradural cervical disc herniation. Case report and review of the literature. *J Neurosurg*. 2000;92(2 Suppl):221–224.
- Sasaji T, Horaguchi K, Yamada N, Iwai K. The specific sagittal magnetic resonance imaging of intradural extra-arachnoid lumbar disc herniation. *Case Rep Med*. 2012;2012:383451. doi:10.1155/2012/383451
- Hidalgo-Ovejero AM, Garcia-Mata S, Izco-Cabezón T, Garralda-Galarza G, Martínez-Grande M. Intradural disc herniation associated with epidural gas. *Spine (Phila Pa 1976)*. 1998;23(2):281–283.
- Yildizhan A, Pasaoglu A, Okten T, Ekinçi N, Aycan K, Aral O. Intradural disc herniations pathogenesis, clinical picture, diagnosis and treatment. *Acta Neurochir (Wien)*. 1991;110(3–4):160–165.
- Min JH, Jang JS, Lee SH. Clinical results of ossification of the posterior longitudinal ligament (OPLL) of the thoracic spine treated by anterior decompression. *J Spinal Disord Tech*. 2008;21(2):116–119. doi:10.1097/BSD.0b013e318060091a
- Rong Y, Luo Y, Liu W, Gong F, Tang P, Cai W. Clinical effects of the bridge-type ROI-C interbody fusion cage system in the treatment of cervical spondylosis with osteoporosis. *Clin Interv Aging*. 2018;13:2543–2551. doi:10.2147/CIA.S182969

## Journal of Pain Research

Dovepress

### Publish your work in this journal

The Journal of Pain Research is an international, peer reviewed, open access, online journal that welcomes laboratory and clinical findings in the fields of pain research and the prevention and management of pain. Original research, reviews, symposium reports, hypothesis formation and commentaries are all considered for publication. The manuscript

management system is completely online and includes a very quick and fair peer-review system, which is all easy to use. Visit <http://www.dovepress.com/testimonials.php> to read real quotes from published authors.

Submit your manuscript here: <https://www.dovepress.com/journal-of-pain-research-journal>