

Transconjunctival sutureless vitrectomy with tissue plasminogen activator, gas and intravitreal bevacizumab in the management of predominantly hemorrhagic age-related macular degeneration

Luis Arias^{1,2}
Jordi Monés¹

¹Institut de la Màcula i de la Retina, Centro Médico Teknon, Barcelona;
²Hospital Universitari de Bellvitge, L'Hospitalet de Llobregat, Barcelona

Purpose: To determine the efficacy and safety of treating predominantly hemorrhagic age-related macular degeneration (AMD) with transconjunctival sutureless vitrectomy (TSV), tissue plasminogen activator (tPA), sulphur hexafluoride (SF6), and intravitreal bevacizumab.

Methods: Retrospective study, consecutive case series. Patients with acute hemorrhagic AMD treated with 25- or 23-gauge TSV, subretinal or intravitreal tPA, fluid-air-SF6 exchange and intravitreal injection of bevacizumab. All operations were performed within the first 5 days after the start of symptoms, which consisted of visual acuity (VA) loss and central scotoma.

Results: Fifteen eyes from 15 patients were included. The patients' mean age was 79.6 years, and the mean follow-up was 11.8 months. Five patients (33%) were receiving oral anticoagulant treatment. At baseline, the mean VA (logMAR values) was 1.5 (20/640 Snellen equivalent). At the last follow-up visit, the mean VA was 1.1 (20/250) ($P < 0.0001$; paired t -test). The submacular hemorrhage was successfully displaced in all the cases. Complications consisted of three cases of vitreous hemorrhage and a tear of the retinal pigment epithelium. Twelve cases (80%) did not require further treatment during the follow-up period.

Conclusion: A surgical approach with 25- or 23-gauge TSV, tPA, SF6 and intravitreal bevacizumab is an efficacious and safe procedure in patients with hemorrhagic AMD. Early treatment is advisable for obtaining the optimal outcome.

Keywords: Hemorrhagic age-related macular degeneration, tissue plasminogen activator, intravitreal bevacizumab; transconjunctival sutureless vitrectomy

Introduction

Submacular hemorrhages can arise from retinal or choroidal circulation associated with age-related macular degeneration (AMD), arterial macroaneurysms and severe traumas. Several factors, such as a release of toxins, tractional forces acting on the retina and a diffusion barrier created by the hemorrhage can promote photoreceptor damage and a loss of visual acuity (VA).¹

To date, intravitreal injections of anti-vascular endothelial growth factor (anti-VEGF) drugs have been the gold standard for the treatment of choroidal neovascularization (CNV) secondary to AMD. Notwithstanding, clinical trials used for drug approval, such as the MARINA and ANCHOR studies of ranibizumab, excluded patients with predominantly hemorrhagic lesions.²

In contrast, the Submacular Surgery Trial did not report favorable results in patients with subfoveal hemorrhagic lesions secondary to neovascular AMD.³

Correspondence: Luis Arias
Department of Ophthalmology, Hospital
Universitari de Bellvitge, C/Feixa Llarga,
sn, 08907 – L'Hospitalet de Llobregat,
Barcelona, Spain
Tel +34 6 2089 8469
Fax +34 9 3260 7981
Email luisarias@telefonica.net

Photodynamic therapy (PDT) with verteporfin has been proven, with limited success, in these patients as well.⁴

Peyman and colleagues⁵ were the first to report the success of a subretinal injection of tPA in five patients with submacular hemorrhages related to arterial macroaneurysms and AMD. They claimed that tPA administration reduced the surgical manipulation of the retina and allowed a smaller retinotomy to drain the blood.

Since then, several techniques have been described. Some have proposed pneumatic displacement of the hemorrhage combined with subretinal tPA and gas.^{6,7} Olivier and colleagues⁸ published a study of 29 eyes in 28 patients, using this technique to treat thick submacular hemorrhages secondary to AMD. They achieved a total displacement of the subfoveal blood in 25 cases and 17 eyes gained ≥ 2 lines of VA. Reported complications included two cases of vitreous hemorrhage that cleared within 4 weeks.

Other authors have proposed that intravitreal injections of tPA and expansile gas can be used without vitrectomy.⁹ Chen and colleagues¹⁰ used this treatment to obtain satisfactory results in 104 eyes, although they reported eight cases of vitreous hemorrhage and three cases of retinal detachment.

Other techniques described in the literature include pneumatic displacement without tPA¹¹ and the preoperative intravitreal injection of tPA.¹²

A recent study found favorable results with a triple injection of tPA, gas, and bevacizumab without vitrectomy.¹³

The aim of the present study was to determine the efficacy and safety of the treatment of hemorrhagic AMD with 25- or 23-gauge transconjunctival sutureless vitrectomy (TSV), tPA, sulphur hexafluoride (SF6), and intravitreal bevacizumab.

Methods

This is a retrospective study comprised of consecutive case series of patients with submacular, predominantly hemorrhagic lesions (blood $\geq 50\%$ of total lesion size) secondary to neovascular AMD. Patients were operated at the *Institut de la Màcula i de la Retina* and at the *Hospital Universitari de Bellvitge* between May 2007 and November 2008. All the included patients had been diagnosed of neovascular AMD. Based on clinical features of previously treated patients and status of the fellow eye we did not identify any polypoidal choroidal vasculopathy or any other cause of submacular hemorrhage.

A single surgeon (LA) operated on all of the recruited patients within the first 5 days after the beginning of the symptoms, which consisted of VA loss and a central scotoma. A 25- or 23-gauge TSV was performed under retrobulbar

anesthesia with posterior hyaloid dissection. In cases with a thick submacular hemorrhage, two or three retinotomies were performed with subretinal injection of tPA (concentration of 125 mg/mL of balance salt solution) using a 39-gauge tip cannula. Subsequently, a fluid-air-20% SF6 exchange was performed with a final intravitreal injection of bevacizumab. In cases with a flat submacular hemorrhage, an intravitreal injection of tPA was administered after the fluid-air-gas exchange. A thick hemorrhage was defined as one causing a significant bulging and elevation of the macular surface from the posterior pole plane (Figure 1).

Patients were left lying on their back for 1 hour after the surgical procedure, and were subsequently instructed to keep a face-down position for 3 days. Follow-up visits were performed 24 hours and 1 week after the surgery, and

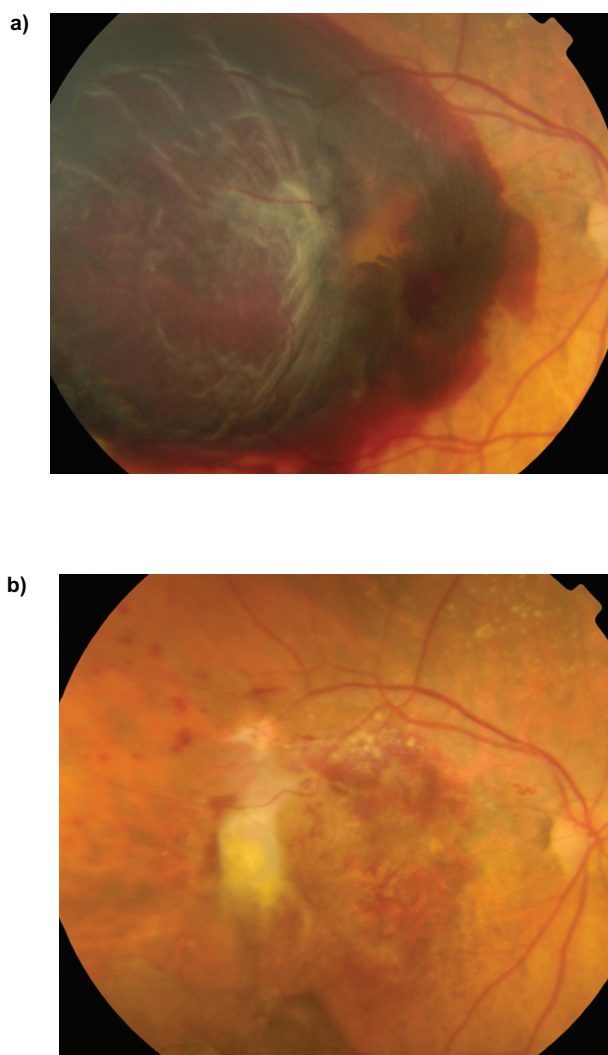


Figure 1 Female aged 89 years (patient no. 5). Baseline fundus photograph (a) and 2 months after the surgery (b). Visual acuity improved from 20/1000 to 20/400. No further treatment was needed during the 12-month follow-up.

then monthly. They included VA measurement using Early Treatment Diabetic Retinopathy Study (ETDRS) charts, anterior segment examination, intraocular pressure measurement, funduscopy examination and retinographies. Additional fluorescein angiography (FA) and optical coherence tomography (OCT) scans were performed at the investigator's discretion.

During follow-up examinations, patients who exhibited CNV activity were treated, as usual, with intravitreal injections of anti-VEGF agents.

Results

The present study included 15 eyes of 15 patients; 10 women (67%) and five men (33%). The affected eye was right in eight cases (53%) and left in seven cases (47%). Six patients (40%) were phakic, eight patients (53%) were pseudophakic and one patient (7%) was aphakic. Eleven patients (73%) had an advanced AMD in the fellow eye and one patient (7%) had lost vision in the other eye due to a neovascular glaucoma secondary to a central retinal vein occlusion (Table 1).

The mean age of the patients was 79.6 years (standard deviation [SD]: 8.6 years; range: 62–94 years). The mean follow-up after the surgery was 11.8 months (SD: 8.3 months; range: 3–24 months).

Eight patients (53%) had been previously treated in the study eye with PDT or intravitreal injections of anti-VEGF drugs (Table 1).

Five patients (33%) were receiving treatment with oral anticoagulant drugs for heart arrhythmia. Four of the five patients under coumadin therapy were among the cases with the most massive bleeds (Table 1).

Three of the operations (20%) were performed using 23-gauge TSV and 12 cases (80%) using 25-gauge TSV. Combined cataract surgery consisting of phakoemulsification plus intraocular lens was performed in two cases (13%).

In eight cases (53%) with thick submacular hemorrhage we performed subretinal injection of tPA (Figure 1), and in the other seven cases (47%), characterized by flat submacular hemorrhage, an intravitreal injection of tPA was administered after the fluid-air-gas exchange (Figure 2).

Lesion size ranged from 15 mm² (5.5 disc areas) to 41 mm² (15 disc areas). The mean lesion size was 33.1 mm² (SD: 4.2 mm²) in the patients with thick submacular hemorrhages and 19.4 mm² (SD: 3.3 mm²) in the patients with flat submacular hemorrhages.

The submacular hemorrhage was successfully displaced in all cases. At baseline, the mean VA (logMAR values) was 1.5 (SD: 0.2) (20/640 Snellen equivalent). At the last follow-up visit, the mean VA was 1.1 (SD: 0.3) (20/250 Snellen equivalent) ($P < 0.0001$; paired *t*-test). The mean VA (ETDRS) improved from 9.4 letters to 28.2 letters with a mean change of +18.7 letters ($P < 0.0001$; paired *t*-test). Eleven patients (73%) gained 15 or more letters of VA.

Table 1 Characteristics of patients included in the study

Patient	Sex	Age	Eye	Lens status	Fellow eye	Anti-coagulant treatment	Previous treatment	Macular hemorrhage	Lesion size
1	Female	70 yo	Left	Pseudo-phakic	Disciform scar	Coumadin	No	Thick	32 mm ²
2	Male	78 yo	Left	Phakic	Disciform scar	No	No	Flat	15 mm ²
3	Male	83 yo	Right	Pseudo-phakic	Normal	Coumadin	4 Lucentis	Thick	35 mm ²
4	Male	94 yo	Right	Pseudo-phakic	Disciform scar	No	No	Thick	31 mm ²
5	Female	89 yo	Right	Pseudo-phakic	Atrophic AMD	No	No	Thick	41 mm ²
6	Female	62 yo	Right	Phakic	Wet AMD	No	No	Flat	18 mm ²
7	Female	88 yo	Right	Phakic	Disciform scar	No	No	Flat	23 mm ²
8	Female	76 yo	Left	Pseudo-phakic	Wet AMD	No	3 Macugen	Flat	20 mm ²
9	Female	86 yo	Left	Pseudo-phakic	Disciform scar	Coumadin	3 Lucentis	Thick	34 mm ²
10	Female	75 yo	Left	Phakic	Disciform scar	Coumadin	1PDT 2 Macugen 3 Avastin	Flat	24 mm ²
11	Male	82 yo	Left	Phakic	Lost by glaucoma	No	1 PDT 3 Lucentis	Flat	20 mm ²
12	Female	75 yo	Right	Pseudo-phakic	Wet AMD	No	3 Lucentis	Flat	16 mm ²
13	Male	89 yo	Left	Aphakic	Wet AMD	Coumadin	1 Lucentis	Thick	32 mm ²
14	Female	71 yo	Right	Pseudo-phakic	Normal	No	3 Lucentis	Thick	34 mm ²
15	Female	77 yo	Right	Phakic	Normal	No	No	Thick	26 mm ²

Abbreviations: AMD, age-related macular degeneration; PDT, photodynamic therapy; yo, years old.

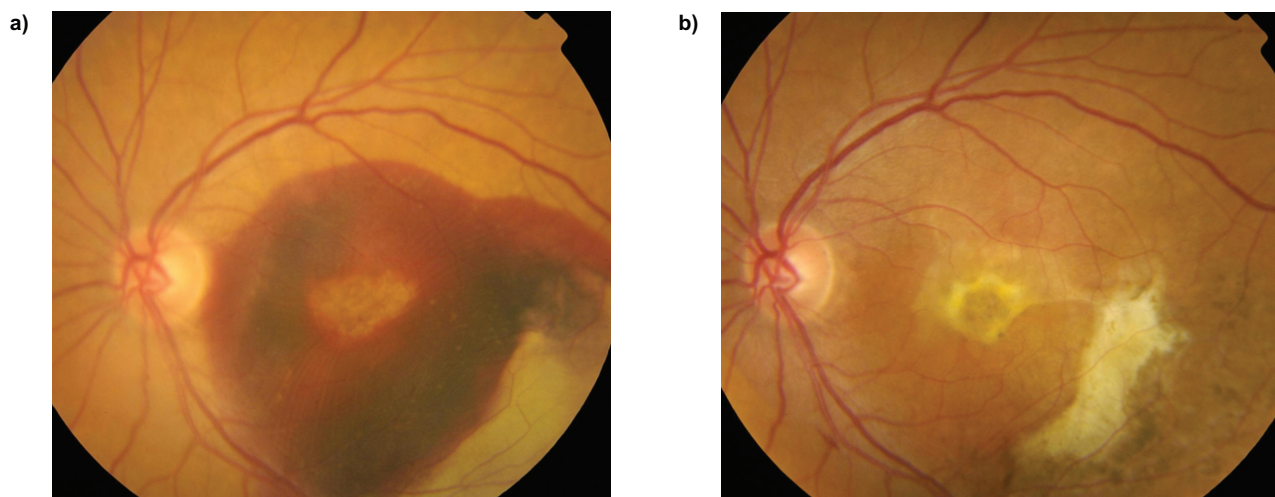


Figure 2 Female aged 76 years (patient no. 8). Baseline fundus photograph (a) and 12 months after the surgery (b). Visual acuity improved from 20/800 to 20/200. No further treatment was needed during the 20-month follow-up.

Complications consisted of three cases (20%) of vitreous hemorrhage that spontaneously resolved after 2–3 weeks. Additionally, one patient (7%) had a tear of the retinal pigment epithelium (RPE) (Figure 3).

Twelve cases (80%) did not require further treatment during the follow-up period. Three cases (20%) were treated with additional intravitreal injections of anti-VEGF drugs (Table 2).

Discussion

The present study found a favorable outcome of managing predominantly hemorrhagic lesions, secondary to AMD, with TSV combined with tPA, SF6, and intravitreal bevacizumab. The submacular hemorrhage was successfully displaced in all cases, and the mean VA significantly improved after surgical treatment.

Recently, Meyer and colleagues¹³ published a study using a triple intravitreal injection of tPA, gas and bevacizumab without vitrectomy in 19 patients with acute subretinal hemorrhages. The initial size of the lesion was 1–3 disc diameters. In our study, lesion size was bigger, ranging from 15 mm² (5.5 disc areas) to 41 mm² (15 disc areas). In their study, the mean VA improved significantly from 20/133 at baseline to 20/74 at 3 months. In our study, the mean VA improved from 20/640 to 20/250. However, the mean ETDRS VA improvement was very similar in both studies (3.7 lines in their study compared with 3.6 lines in ours). Thus, a surgical approach in large lesions can obtain comparable results to a triple intravitreal injection procedure in smaller hemorrhagic lesions.

In our study, 33% of patients received oral anticoagulants. It is known that this medication significantly increases the risk of an intraocular hemorrhage in wet AMD patients.¹⁴

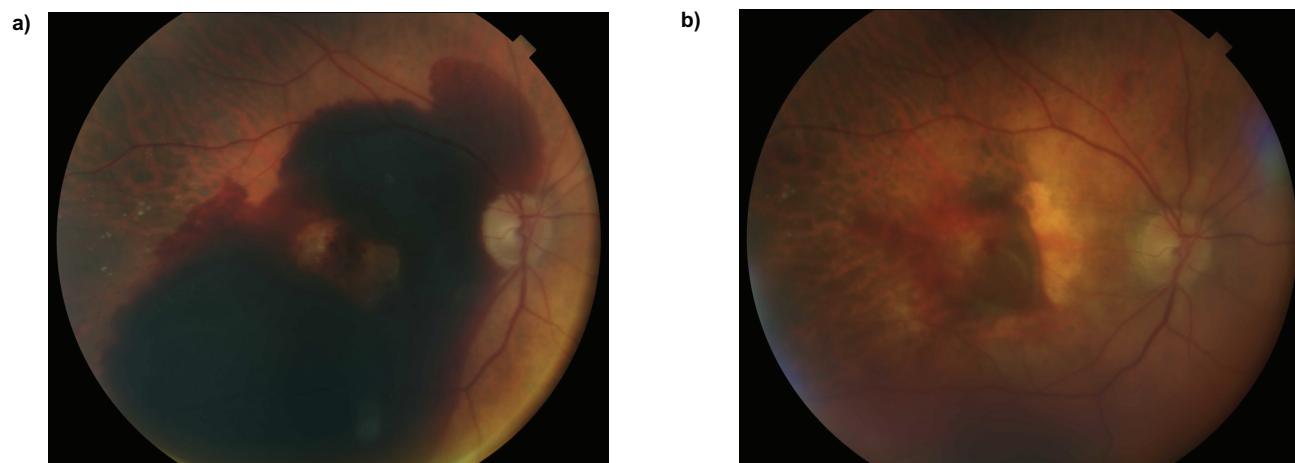


Figure 3 Male aged 83 years (patient no. 3). Baseline fundus photograph (a) and 2 weeks after the surgery showing a tear of the retinal pigment epithelium (b).

Table 2 Main results of the study

Patient	Surgery	tPA	Baseline VA logMAR (Snellen)	Baseline VA ETDRS	Final VA logMAR (Snellen)	Final VA ETDRS	Complications	Posterior treatment	Follow-up (months)
1	PPV 25 g	Subretinal	1.7 (20/1000)	4 letters	1.3 (20/400)	20 letters	No	No	12
2	PPV 25 g	Intravitreal	1.6 (20/800)	8 letters	1.1 (20/250)	30 letters	No	3 Lucentis	24
3	PPV 23 g	Subretinal	1.6 (20/800)	8 letters	1.3 (20/400)	20 letters	RPE tear	No	7
4	PPV 25 g	Subretinal	1.7 (20/1000)	4 letters	1.3 (20/400)	20 letters	Vitreous hemorrhage	No	8
5	PPV 25 g	Subretinal	1.7 (20/1000)	4 letters	1.3 (20/400)	20 letters	Vitreous hemorrhage	No	12
6	PPV 25 g	Intravitreal	0.7 (20/100)	50 letters	0.1 (20/25)	80 letters	No	3 Avastin	24
7	Phako+IOLPPV 23 g	Intravitreal	1.6 (20/800)	8 letters	1.3 (20/400)	20 letters	No	No	20
8	PPV 25 g	Intravitreal	1.6 (20/800)	8 letters	1 (20/200)	35 letters	No	No	20
9	PPV 25 g	Subretinal	1.7 (20/1000)	4 letters	1.3 (20/400)	20 letters	Vitreous hemorrhage	No	6
10	Phako+IOL PPV 25 g	Intravitreal	1.7 (20/1000)	4 letters	1.3 (20/400)	20 letters	No	No	24
11	PPV 25 g	Intravitreal	1.3 (20/400)	20 letters	0.6 (20/80)	55 letters	No	2 Lucentis	8
12	PPV 23 g	Intravitreal	1.6 (20/800)	8 letters	1.3 (20/400)	20 letters	No	No	3
13	PPV 25 g	Subretinal	1.7 (20/1000)	4 letters	1.3 (20/400)	20 letters	No	No	3
14	PPV 25 g	Subretinal	1.7 (20/1000)	4 letters	1 (20/200)	35 letters	No	No	3
15	PPV 25 g	Subretinal	1.7 (20/1000)	4 letters	1.6 (20/800)	8 letters	No	No	3

Abbreviations: ETDRS, early treatment diabetic retinopathy study; PPV, pars plana vitrectomy; tPA, tissue plasminogen activator; VA, visual acuity.

We decided to perform a posterior vitrectomy to minimize the risk of vitreoretinal tractions that could be associated with the single administration of intravitreal injections. In addition, a surgical approach seems advisable taking into account the large size of the lesions included in our study. Current systems of microincisional TSV allow efficacious, safe and swift surgery with minimal eye trauma and discomfort for the patient. However, we do not think that 25 g or 23 g vitrectomy may achieve better anatomical or functional outcome compared with that using 20 g instruments.

In cases of thick submacular hemorrhages, we injected subretinal tPA as previously described by Olivier and colleagues.⁸ In cases of flat submacular hemorrhages, we decided to perform an intravitreal tPA injection to reduce possible damage to photoreceptors and RPE cells associated with subretinal manipulation. The final results were better in the patients with flat submacular hemorrhages than in the patients with thick hemorrhages. This could be related to the smaller lesion size in the patients with flat hemorrhages.

We used SF6 because we believe that a short-acting gas is sufficient to obtain an adequate pneumatic displacement of the submacular hemorrhage.

In accordance with an experimental study published by Lüke and colleagues,¹⁵ we decided to administer a final

intravitreal injection of bevacizumab. Their study showed that tPA and bevacizumab are compatible drugs with no evidence of retinal toxicity. Moreover, the potent antiangiogenic effect associated with bevacizumab could be beneficial for reducing CNV activity. In fact, 80% of patients in our study did not require further treatment during the follow-up period. However, no strong evidence suggests bevacizumab is associated with more prompt or thorough lesion regression.

The only complications we detected were three cases of mild vitreous hemorrhage that spontaneously cleared within the first few weeks. It is logical that the liquefied subretinal blood enters the vitreous cavity to get reabsorbed posteriorly. None of our patients had a retinal tear or retinal detachment.

We observed a single tear of the RPE after resolution of the submacular hemorrhage. It was not clear whether the tear was present preoperatively or developed after the surgery. RPE rips have been described in large submacular hemorrhages in wet AMD patients.¹⁶

All operations were performed within the first 5 days after the patients first experienced symptoms. Olivier and colleagues⁸ reported an average submacular hemorrhage duration of 23 days before surgery. Meyer and colleagues¹³ reported a mean duration of symptoms of 9 days (range: 4–12 days). We believe that optimal results in these cases are

dependent upon early surgery to avoid irreversible damage to photoreceptors and RPE cells.

Limitations of this study are that it was retrospective, noncomparative, nonrandomized and included few patients with a limited follow-up. It is difficult to enroll a large number of cases with this macular disorder.

In conclusion, this small study has shown efficacy and safety in the management of predominantly hemorrhagic AMD lesions with an early TSV with tPA, gas and intravitreal bevacizumab.

Larger multicenter randomized studies are warranted to determine the real therapeutic effect of this surgical approach.

Disclosure

The authors have no financial or proprietary interest in any product mentioned in this article and received no financial support in this work.

References

- Hochman MA, Seery CM, Zarbin MA. Pathophysiology and management of subretinal hemorrhage. *Surv Ophthalmol.* 1997;42:195–213.
- Rosenfeld PJ, Brown DM, Heier JS, et al. Ranibizumab for neovascular age-related macular degeneration. *N Engl J Med.* 2006;355:1419–1431.
- Bressler NM, Bressler SB, Childs AL, et al. Submacular Surgery Trials (SST) Research Group. Surgery for hemorrhagic choroidal neovascular lesions of age-related macular degeneration: ophthalmic findings: SST report no. 13. *Ophthalmology.* 2004;111:1993–2006.
- Ahmad S, Bearely S, Stinnett SS, Cooney MJ, Fekrat S. Photodynamic therapy for predominantly hemorrhagic lesions in neovascular age-related macular degeneration. *Am J Ophthalmol.* 2008;145:1052–1057.
- Peyman GA, Nelson NC Jr, Alturki W, et al. Tissue plasminogen activating factor assisted removal of subretinal hemorrhage. *Ophthalmic Surg.* 1991;22:575–582.
- Hauptert CL, McCuen BW II, Jaffe GJ, et al. Pars plana vitrectomy, subretinal injection of tissue plasminogen activator, and fluid-gas exchange for displacement of thick submacular hemorrhage in age-related macular degeneration. *Am J Ophthalmol.* 2001;131:208–215.
- Singh RP, Patel C, Sears JE. Management of subretinal macular haemorrhage by direct administration of tissue plasminogen activator. *Br J Ophthalmol.* 2006;90:429–431.
- Olivier S, Chow DR, Packo KH, MacCumber MW, Awh CC. Subretinal recombinant tissue plasminogen activator injection and pneumatic displacement of thick submacular hemorrhage in age-related macular degeneration. *Ophthalmology.* 2004;111:1201–1208.
- Hassan AS, Johnson MW, Schneiderman TE, et al. Management of submacular hemorrhage with intravitreal tissue plasminogen activator injection and pneumatic displacement. *Ophthalmology.* 1999;106:1900–1906.
- Chen CY, Hooper C, Chiu D, et al. Management of submacular hemorrhage with intravitreal injection of tissue plasminogen activator and expansile gas. *Retina.* 2007;27:321–328.
- Ohji M, Saito Y, Hayashi A, Lewis JM, Tano Y. Pneumatic displacement of subretinal hemorrhage without tissue plasminogen activator. *Arch Ophthalmol.* 1998;116:1326–1332.
- Oshima Y, Ohji M, Tano Y. Pars plana vitrectomy with peripheral retinotomy after injection of preoperative intravitreal tissue plasminogen activator: a modified procedure to drain massive subretinal haemorrhage. *Br J Ophthalmol.* 2007;91:193–198.
- Meyer CH, Scholl HP, Eter N, Helb HM, Holz FG. Combined treatment of acute subretinal haemorrhages with intravitreal recombinant tissue plasminogen activator, expansile gas and bevacizumab: a retrospective pilot study. *Acta Ophthalmol.* 2008;86:490–494.
- Tilanus MA, Vaandrager W, Cuypers MH, Verbeek AM, Hoyng CB. Relationship between anticoagulant medication and massive intraocular hemorrhage in age-related macular degeneration. *Graefes Arch Clin Exp Ophthalmol.* 2000;238:482–485.
- Lüke M, Januschowski K, Warga M, et al. The retinal tolerance to bevacizumab in co-application with a recombinant tissue plasminogen activator. *Br J Ophthalmol.* 2007;91:1077–1082.
- Biester S, Bartz-Schmidt KU, Gelissen F. Retinal pigment epithelial tear after subretinal rtPA and intravitreal air for the displacement of a large submacular hemorrhage. *Retinal Cases and Brief Reports.* 2009;3(1):62–63.

Clinical Ophthalmology

Publish your work in this journal

Clinical Ophthalmology is an international, peer-reviewed journal covering all subspecialties within ophthalmology. Key topics include: Optometry; Visual science; Pharmacology and drug therapy in eye diseases; Basic Sciences; Primary and Secondary eye care; Patient Safety and Quality of Care Improvements. This journal is indexed on

Submit your manuscript here: <http://www.dovepress.com/clinical-ophthalmology-journal>

Dovepress

PubMed Central and CAS, and is the official journal of The Society of Clinical Ophthalmology (SCO). The manuscript management system is completely online and includes a very quick and fair peer-review system, which is all easy to use. Visit <http://www.dovepress.com/testimonials.php> to read real quotes from published authors.