

# Responses to *ALK* Inhibitor Treatments in a Patient with Non-Small Cell Lung Cancer Harboring a Novel *HPCALI-ALK* Fusion Variant: A Case Report

This article was published in the following Dove Press journal:  
*OncoTargets and Therapy*

Ruixiao Wang<sup>1,\*</sup>  
Jiayue Qin<sup>1,\*</sup>  
Yafeng Fan<sup>2</sup>  
Zhimin Li<sup>1</sup>  
Chongjian Chen<sup>1</sup>  
Wenzhong Su<sup>2</sup>

<sup>1</sup>Annoroad Gene Technology Co., Ltd, Beijing 100176, People's Republic of China; <sup>2</sup>Department of Respiration Medicine, Shanxi Cancer Hospital, Taiyuan, Shanxi 030013, People's Republic of China

\*These authors contributed equally to this work

**Abstract:** Anaplastic lymphoma kinase (*ALK*) fusion is present in approximately 2–7% of patients with lung adenocarcinoma. *ALK* fusion-positive patients can benefit from targeted therapy. We herein report a 53-year-old Chinese male patient diagnosed as lung adenocarcinoma with a smoking history. Next-generation sequencing was performed to detect somatic mutations of oncogenic drivers and tumor suppressor genes in plasma-derived circulating tumor DNA using an ultra-deep 160-gene panel. A novel *HPCALI-ALK* fusion variant was identified in the patient responding to *ALK* inhibitor treatments, and the fusion variant was also confirmed by fluorescence in situ hybridization and immunohistochemical. Our study expands the mutational spectrum of *ALK* fusion variants and provides options for the precise treatment of such patients.

**Keywords:** non-small cell lung cancer, anaplastic lymphoma kinase fusion, next-generation sequencing, targeted therapy

## Introduction

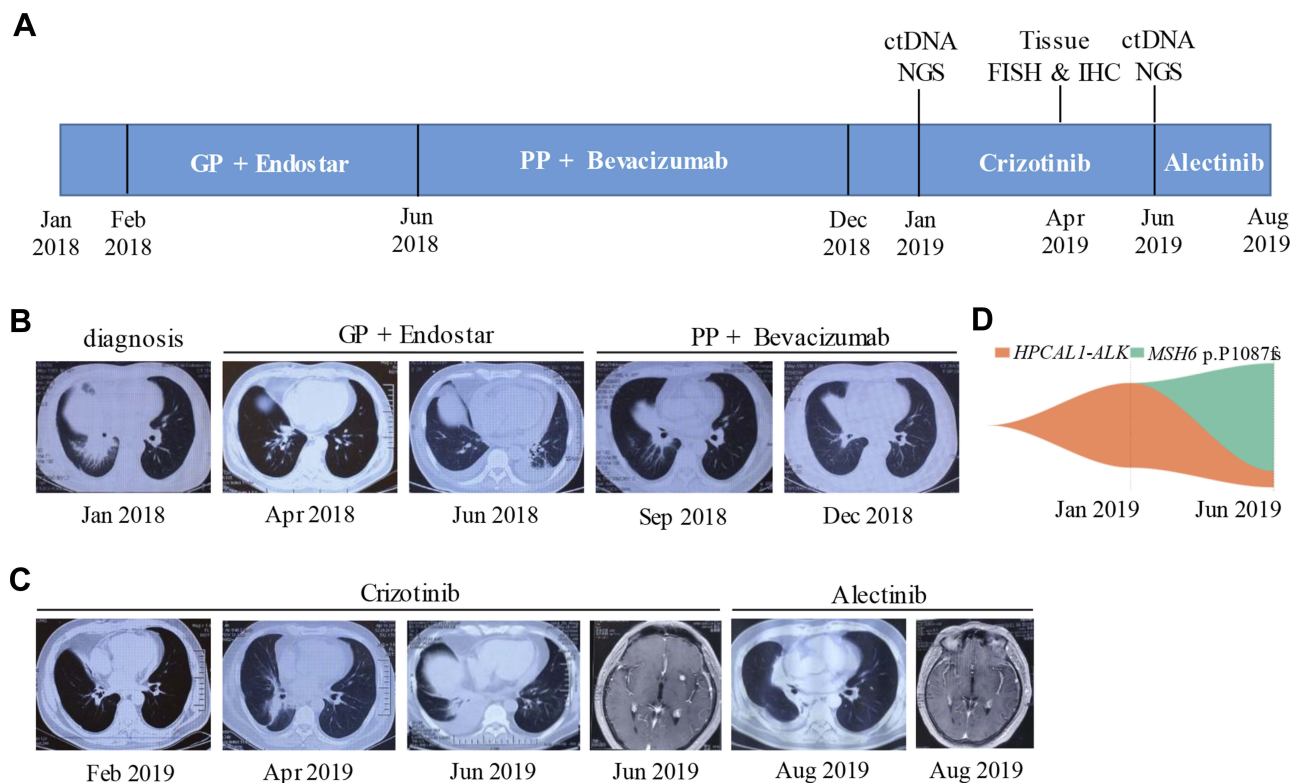
Anaplastic lymphoma kinase (*ALK*) fusions are relatively common in young, non-smoking patients, and approximately 2–7% of patients with lung adenocarcinoma are identified to carry the fusion variants.<sup>1,2</sup> Targeted therapies of *ALK* fusions by drugs such as crizotinib, ceritinib, alectinib, and brigatinib, are widely used to treat the *ALK* fusion-positive patients with non-small cell lung cancer (NSCLC).<sup>3–8</sup> Previous studies have demonstrated that the next-generation sequencing (NGS) technology could be utilized to circulating tumor DNA (ctDNA) extracted from patients' peripheral blood to guide their clinical treatments.<sup>9–11</sup>

Here, we report a novel *HPCALI-ALK* fusion variant in ctDNA was identified in a patient with NSCLC responding to *ALK* inhibitor treatments, using an ultra-deep (20000X) 160-gene panel through the NGS platform (shown in [Supplementary Materials](#) and [Table S1](#)).

## Case Report

The patient was a 53-year-old Chinese male with a smoking history. The timeline of his diagnosis and treatment was shown in [Figure 1A](#) and the detailed description was as follows. In January 2018, the patient started to have symptoms of coughing,

Correspondence: Wenzhong Su;  
Chongjian Chen  
Email wenzhongsu001@163.com;  
cchen@annoroad.com



**Figure 1** Clinical course and representative clinical images of the patient with NSCLC.

**Notes:** (A) Patient's treatment timeline showed the application of different drug treatments. (B) CT scan images were taken during baseline of cancer diagnosis, the GP regimen/recombinant human endostatin (Endostar) combinational treatment, and the PP regimen/bevacizumab combinational treatment, respectively. (C) CT scan images were taken during oral crizotinib treatment, and oral alectinib treatment, respectively. (D) Map of clonal evolution. Two ctDNA samples were collected before and after crizotinib treatment. The different colors represent different gene mutation sites, as measured by NGS platform.

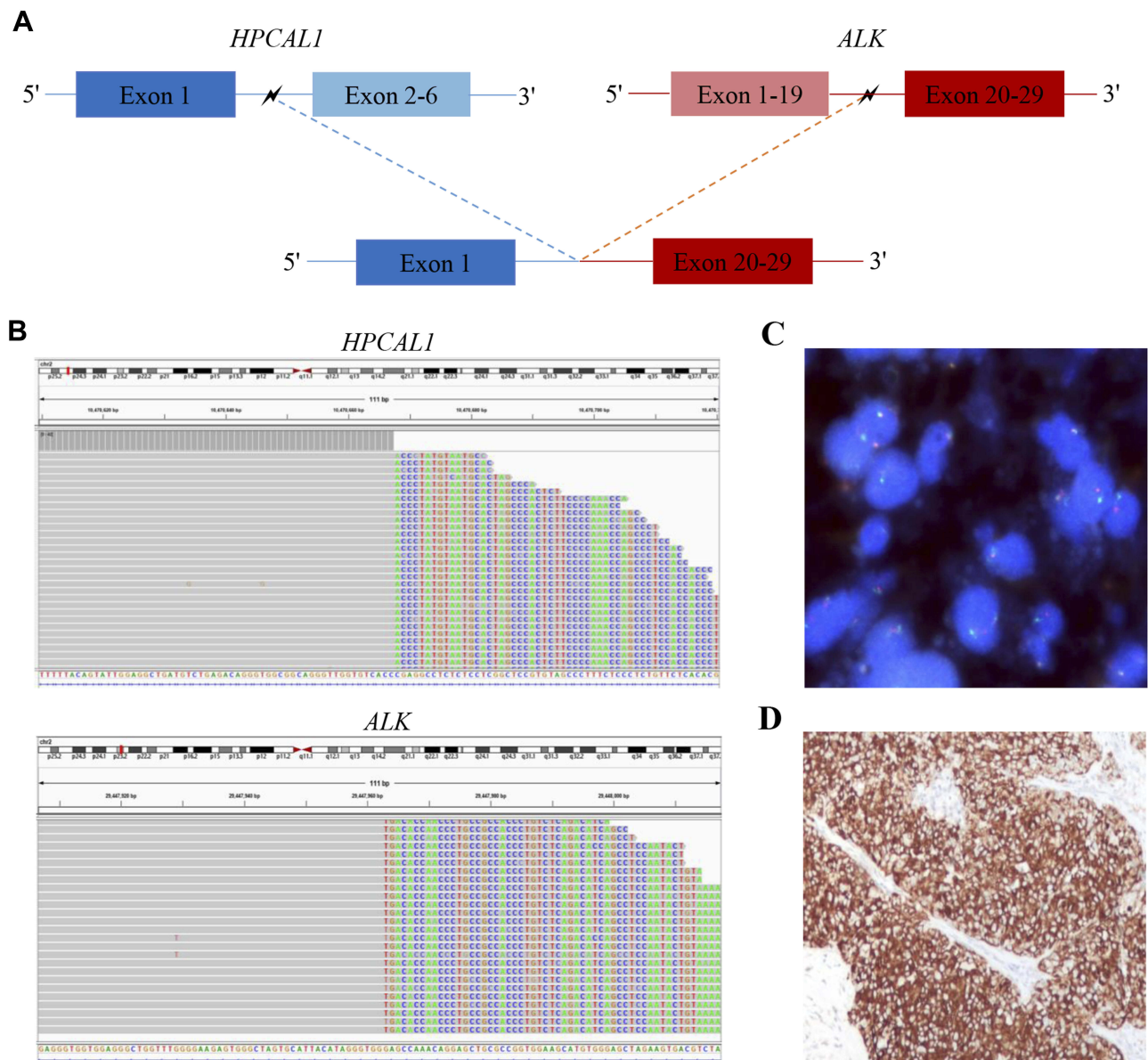
**Abbreviations:** NSCLC, non-small cell lung cancer; ctDNA, circulating tumor DNA; NGS, next-generation sequencing.

shortness of breath, chest pain, back pain and hemoptysis. The initial chest computed tomographic (CT) scan showed an irregular mass shadow with the size of 7x4 cm in the right middle lobe, accompanied by local atelectasis, mediastinal lymphadenopathy and right lower hilar lymph node enlargement of 4x4 cm (Figure 1B). The single-photon emission computerized tomography (SPECT) imaging of whole-body bone scan revealed abnormal isotopic accumulation in multiple sites and the CT guided lower lung biopsy sample showed moderately differentiated adenocarcinoma. Overall, the patient was newly diagnosed as right lung adenocarcinoma, bone metastasis and T4N2M1 stage IV.

Starting from February 2018, the patient was given 4 cycles of chemotherapy (GP regimen + recombinant human endostatin (Endostar)), and symptoms of coughing and shortness of breath were significantly relieved after the treatment. The chest CT scan showed a reduced right lung lesion of 3x3 cm, the size of lower hilar lymph node was down to 2.5x2.5 cm and local atelectasis and pericardial effusion were alleviated (Figure 1B). According to

RECIST version 1.1, the efficacy was evaluated as partial response (PR).

However, in late June 2018, the patient again developed coughing, shortness of breath, and lower back pain. The chest CT scan revealed an elevated local atelectasis, large amount of pericardial effusion and bilateral pleural effusion. The patient was given two cycles of chemotherapy (PP regimen + bevacizumab) but improvements were not observed after a thorough re-examination (Figure 1B). Fiberoptic bronchoscopy was performed in January 2019. The irregular swelling in the middle lobe of the right lung was found to swell and grow into the lumen, resulting in narrowing of the bronchus in the middle lobe of the right lung. The biopsy was pathologically lung adenocarcinoma. CtDNA extracted from the peripheral blood of the patient was sequencing based on the NGS platform, and the result showed a novel in-frame *HPCAL1-ALK* fusion, in which the full kinase domain of *ALK* was retained. The breakpoint was inside intron 1 of *HPCAL1* and intron 19 of *ALK* and the abundance of the fusion gene was 1.87% (Figure 1D, 2A and B). Oral crizotinib was administrated to the



**Figure 2** Identification of the novel *HPCALI-ALK* fusion.

**Notes:** (A) Structural illustration showed the *HPCALI-ALK* fusion variant. (B) IGV image showed chimeric reads indicated *HPCALI-ALK* fusion by NGS platform. (C) The representative FISH image showed split red-green or single red dots which indicating *ALK* fusion. Vysis *ALK* Break Apart Fish Probe Kit and Olympus Model BX51 Fluorescent Microscope were used for FISH detection. (D) The representative IHC staining image showed a strong protein expression, using *ALK* D5F3 (Ventana; 300X). **Abbreviations:** IGV, integrative genomics viewer; NGS, next-generation sequencing; FISH, fluorescence in situ hybridization; IHC, immunohistochemical.

patient at 250 mg bid. After a month of treatment in February 2019, the chest CT scan displayed a relieved atelectasis and diminished hilar lymph node tumor. The efficacy evaluation was PR (Figure 1C). The patient continued to proceed with the oral crizotinib treatment.

In April 2019, the re-examination CT scan revealed that the lesion at the right lung bronchus was almost disappeared, bilateral pleural effusion and pericardial effusion were nearly absorbed, but the tumor at the hilar lymph node was enlarged and the inflammation in the

right lower lung was aggravated (Figure 1C). The *HPCALI-ALK* fusion variant was then confirmed by fluorescence in situ hybridization (FISH) and immunohistochemical (IHC) in formalin fixed paraffin-embedded (FFPE) tissues (Figure 2C and D). In June 2019, symptoms of coughing and shortness of breath were worsened and discomfort in the upper right abdominal was developed. Chest CT scan showed increased right lung lesion of 2x4 cm, atelectasis at the right middle lobe, enlarged right lower hilar lymph node of 3x3 cm, pleural effusion,

pericardial effusion and multiple metastases in the liver. The cranial MRI results showed multiple brain metastases, with a maximum lesion of 0.7x0.7 cm (Figure 1C). At this point, the efficacy was assessed as progressive disease (PD). A second NGS detection in ctDNA was performed and the *HPCAL1-ALK* fusion was identified again at the abundance rate of 0.36% (Figure 1D). And then oral alectinib was prescribed to the patient at 600 mg bid. Chest CT scan performed in August 2019 showed reduced pleural effusion, relieved atelectasis at the right middle lobe, disappearance of pericardial effusion and inflammation in the right lower lung, and the size of right lung lesion and right lower hilar lymph node was reduced to 2x3 cm and 1.5x1 cm, respectively. Liver metastatic sites were also significantly smaller than before and partially disappeared. The cranial MRI image showed that the brain metastases almost disappeared (Figure 1C). The efficacy of the treatment was assessed as PR. The patient continued to receive the oral alectinib treatment.

## Discussion

In this study, we reported a 53-year-old Chinese male with NSCLC. After the patient's first two lines of chemotherapy failed, a subsequent ctDNA test revealed a novel *HPCAL1-ALK* fusion variant. The patient was then treated with crizotinib for targeted therapy. As crizotinib is a protein kinase inhibitor that binds target kinase pockets by competitively binding ATP,<sup>12</sup> the patient's symptoms were markedly relieved for nearly five months. However, the patient relapsed at a later stage and alectinib was used to treat this patient with crizotinib resistance.

Based on literature retrieval of PubMed and Web of Science, the *HPCAL1-ALK* fusion variant we found was not reported. However, we found that patient with the fusion variant responded to both crizotinib and alectinib. Several studies have shown that this *HPCAL1* gene is involved in calcium-dependent regulation of rhodopsin phosphorylation and is related to neuronal signaling in the central nervous system. The protein the gene encodes is a member of the family of neuron-specific calcium-binding proteins that are common in the retina and the brain.<sup>13–15</sup> However, the molecular mechanism and function of the *HPCAL1-ALK* fusion variant remains to be further studied, especially in NSCLC.

Some studies have shown that accurate identification of fusion partners affects treatment selection and plays an important role in prognosis. McLeer-Florin et al found that the clinical efficacy of NSCLC patients with *EML4* (exon 13)-*ALK* (exon 20) and *EML4* (exon 20)-

*ALK* (exon 20) variants based on crizotinib treatment was superior to that of patients with *EML4* (exon 6)-*ALK* (exon 20) variants,<sup>16</sup> suggesting that it is of great significance to evaluate the efficacy of crizotinib based on *ALK* variation types. Drilon et al found that based on RET inhibitor therapy, NSCLC patients with the *KIF5B-RET* fusion variant had a statistically significant difference in the objective remission rate when compared with patients with other non-*KIF5B* partners,<sup>17</sup> indicating that the accurate detection of the *RET* fusion variant partners is conducive to clinical efficacy evaluation. Li et al found that a novel *TFG-ROS1* fusion variant in an inflammatory myofibroblastic tumor (IMT) patient had a certain response to the treatment of ROS1 inhibitor ceritinib,<sup>18</sup> showing that the targeted therapy based on fusion variant can bring clinical benefit to patients.

As the clinical significance of fusion gene detection has been gradually proved, more and more technical methods have been applied to detect fusion variants, including FISH, IHC and NGS. FISH and IHC, as conventional fusion gene detection methods, have certain limitations, mainly because they cannot accurately determine the unknown fusion gene partner and the precise breakpoint. But ctDNA testing based on the NGS platform can reveal more details about the breakpoint structure of fusion genes, making up for the limitations of FISH and IHC.<sup>19,20</sup> Furthermore, this approach based on ctDNA testing is feasible in the absence of sufficient samples for tissue genetic testing and can greatly reduce the complexity of molecular work, providing a solution to the evolving actionable targets in NSCLC.<sup>21</sup>

To the best of our knowledge, we identified a novel *HPCAL1-ALK* fusion variant in the blood sample of a male patient with NSCLC. The patient firstly received the *ALK* inhibitor crizotinib treatment and efficacy was observed. Alectinib was secondly used after the patient showed resistance to the crizotinib and it has shown effective up to now.

## Conclusion

In summary, this is the first report on a novel *HPCAL1-ALK* fusion variant identified in NGS and validated by FISH and IHC. The discovery of this new fusion variant has supplemented the mutational spectrum of *ALK* fusion variants, highlights the need for predictive biomarkers, and provides options for the precise treatment of such patients.

## Ethics Approval

The patient provided written informed consent to participate in the study and for the case details to be published,



which was approved by the Clinical Research Ethics Committee of Shanxi Cancer Hospital.

## Acknowledgments

We thank the patient for participating in this study. We also thank Xueguang Sun, Jiawei Wang, Chen Chen, Ruilin Jing and Qianpeng Huang for their technical support.

## Disclosure

The authors declare that they have no conflicts of interest.

## References

- Rosenbaum JN, Bloom R, Forsys JT, et al. Genomic heterogeneity of ALK fusion breakpoints in non-small-cell lung cancer. *Mod Pathol.* 2018;31(5):791–808. doi:10.1038/modpathol.2017.181
- Chaft JE, Arcila ME, Paik PK, et al. Coexistence of PIK3CA and other oncogene mutations in lung adenocarcinoma—rationale for comprehensive mutation profiling. *Mol Cancer Ther.* 2012;11(2):485–491. doi:10.1158/1535-7163.MCT-11-0692
- Shaw AT, Kim DW, Nakagawa K, et al. Crizotinib versus chemotherapy in advanced ALK-positive lung cancer. *N Engl J Med.* 2013;368(25):2385–2394. doi:10.1056/NEJMoa1214886
- Shaw AT, Gandhi L, Gadgeel S, et al. Alectinib in ALK-positive, crizotinib-resistant, non-small-cell lung cancer: a single-group, multicentre, Phase 2 trial. *Lancet Oncol.* 2016;17(2):234–242. doi:10.1016/S1470-2045(15)00488-X
- Kwak EL, Bang YJ, Camidge DR, et al. Anaplastic lymphoma kinase inhibition in non-small-cell lung cancer. *N Engl J Med.* 2010;363(18):1693–1703. doi:10.1056/NEJMoa1006448
- Friboulet L, Li N, Katayama R, et al. The ALK inhibitor ceritinib overcomes crizotinib resistance in non-small cell lung cancer. *Cancer Discov.* 2014;4(6):662–673. doi:10.1158/2159-8290.CD-13-0846
- Peters S, Camidge DR, Shaw AT, et al. Alectinib versus Crizotinib in untreated ALK-positive non-small-cell lung cancer. *N Engl J Med.* 2017;377(9):829–838. doi:10.1056/NEJMoa1704795
- Kim DW, Tiseo M, Ahn MJ, et al. Brigatinib in patients with crizotinib-refractory anaplastic lymphoma kinase-positive non-small-cell lung cancer: a randomized, multicenter Phase II trial. *J Clin Oncol.* 2017;35(22):2490–2498. doi:10.1200/JCO.2016.71.5904
- Abbosh C, Birkbak NJ, Swanton C. Early stage NSCLC - challenges to implementing ctDNA-based screening and MRD detection. *Nat Rev Clin Oncol.* 2018;15(9):577–586. doi:10.1038/s41571-018-0058-3
- Rolfo C, Mack PC, Scagliotti GV, et al. Liquid biopsy for advanced Non-Small Cell Lung Cancer (NSCLC): a statement paper from the IASLC. *J Thorac Oncol.* 2018;13(9):1248–1268. doi:10.1016/j.jtho.2018.05.030
- Qin J, Wang J, Lin X, et al. Erlotinib resistance with EGFR L858R/Y891D double mutation in a patient with non-small cell lung cancer. *J Thorac Oncol.* 2019;14(4):e65–e68. doi:10.1016/j.jtho.2018.12.031
- Ou SH, Kwak EL, Siwak-Tapp C, et al. Activity of crizotinib (PF02341066), a dual mesenchymal-epithelial transition (MET) and anaplastic lymphoma kinase (ALK) inhibitor, in a non-small cell lung cancer patient with de novo MET amplification. *J Thorac Oncol.* 2011;6(5):942–946. doi:10.1097/JTO.0b013e31821528d3
- Zhang D, Liu X, Xu X, et al. HPCAL1 promotes glioblastoma proliferation via activation of Wnt/beta-catenin signalling pathway. *J Cell Mol Med.* 2019;23(5):3108–3117. doi:10.1111/jcmm.14083
- Zhang Y, Liu Y, Duan J, et al. Hippocalcin-like 1 suppresses hepatocellular carcinoma progression by promoting p21(Waf/Cip1) stabilization by activating the ERK1/2-MAPK pathway. *Hepatology.* 2016;63(3):880–897. doi:10.1002/hep.28395
- Fu J, Zhang J, Jin F, Patchefsky J, Braunewell KH, Klein-Szanto AJ. Promoter regulation of the visinin-like subfamily of neuronal calcium sensor proteins by nuclear respiratory factor-1. *J Biol Chem.* 2009;284(40):27577–27586. doi:10.1074/jbc.M109.049361
- McLeer-Florin A, Duruisseaux M, Pinsolle J, et al. ALK fusion variants detection by targeted RNA-next generation sequencing and clinical responses to crizotinib in ALK-positive non-small cell lung cancer. *Lung Cancer.* 2018;116:15–24. doi:10.1016/j.lungcan.2017.12.004
- Drilon A, Fu S, Patel MR, et al. A Phase I/Ib Trial of the VEGFR-sparing multikinase RET inhibitor RXDX-105. *Cancer Discov.* 2019;9(3):384–395. doi:10.1158/2159-8290.CD-18-0839
- Li Y, Chen X, Qu Y, et al. Partial response to ceritinib in a patient with abdominal inflammatory myofibroblastic tumor carrying a TFG-ROS1 fusion. *J Natl Compr Canc Netw.* 2019;17(12):1459–1462. doi:10.6004/jnccn.2019.7360
- Dagogo-Jack I, Shaw AT. Screening for ALK rearrangements in lung cancer: time for a new generation of diagnostics? *Oncologist.* 2016;21(6):662–663. doi:10.1634/theoncologist.2016-0179
- Lam SW, Cleton-Jansen AM, Cleven AHG, et al. Molecular analysis of gene fusions in bone and soft tissue tumors by anchored multiplex PCR-based targeted next-generation sequencing. *J Mol Diagn.* 2018;20(5):653–663. doi:10.1016/j.jmoldx.2018.05.007
- Cohen D, Hondelink LM, Solleveld-Westerink N, et al. Optimizing mutation and fusion detection in non-small cell lung cancer by sequential DNA and RNA sequencing. *J Thorac Oncol.* 2020. doi:10.1016/j.jtho.2020.01.019

### OncoTargets and Therapy

### Publish your work in this journal

OncoTargets and Therapy is an international, peer-reviewed, open access journal focusing on the pathological basis of all cancers, potential targets for therapy and treatment protocols employed to improve the management of cancer patients. The journal also focuses on the impact of management programs and new therapeutic

agents and protocols on patient perspectives such as quality of life, adherence and satisfaction. The manuscript management system is completely online and includes a very quick and fair peer-review system, which is all easy to use. Visit <http://www.dovepress.com/testimonials.php> to read real quotes from published authors.

Submit your manuscript here: <https://www.dovepress.com/oncotargets-and-therapy-journal>

Dovepress