

# Endovascular stent-graft placement for vascular failure of the thoracic aorta

Yoshihiko Kurimoto<sup>1</sup>  
Kiyofumi Morishita<sup>2</sup>  
Yasufumi Asai<sup>1</sup>

<sup>1</sup>Department of Traumatology and Critical Care Medicine, Sapporo Medical University, Sapporo, Japan;

<sup>2</sup>Department of Thoracic and Cardiovascular Surgery, Sapporo Medical University, Sapporo, Japan

**Abstract:** It still remains undetermined whether endovascular stent-graft placement (ESGP) is the optimal initial treatment for elective cases of thoracic aortic disease because of unknown long-term results. However, it is also recognized that ESGP contributes to better outcome as an initial treatment for aortic emergency, such as rupture, aortic injury, and complicated acute type B aortic dissection. Despite the fact that most patients are elderly, early mortality rates of ESGP are reportedly around 10% in cases of ruptured degenerative thoracic aortic aneurysm. Postoperative morbidity is also superior in ESGP compared with conventional open repair. Postoperative paraplegia has rarely occurred with ESGP. In cases of blunt aortic injury (BAI), other complications may also be present because of other serious injuries. ESGP has changed the surgical strategy for BAI and partially resolved some of the clinical dilemmas. Early mortality rate is almost zero when a stent graft can be placed before re-rupture. While BAI is a very good indication for ESGP, young patients need careful management and attention because of the unknown long-term outcome. In cases of complicated acute type B aortic dissection, the two main determinants of death, shock from rupture and visceral ischemia, could be managed by ESGP with or without conventional endovascular interventions. Recent reports disclosed less than 10% early mortality with ESGP for complicated acute aortic dissection. Even if the possibility of endotension remains, ESGP seems to be beneficial for these critical patients as the preferable initial treatment. The importance of close follow-up should be stressed to avoid some devastating late complications following ESGP.

**Keywords:** stent graft, ruptured thoracic aortic aneurysm, aortic injury, aortic dissection, organ ischemia

## Introduction

Recent advances in surgical management of thoracic aortic diseases has provided better outcomes and has led to an expansion of surgical indication for high-risk patients with comorbidities (Kouchoukos and Dougenis 1997; Svensson et al 1997). However, surgical management of these diseases cannot avoid thoracotomy, extracorporeal bypass, and aortic clamping, which, given the invasiveness of these treatment methods, mean that there are still limitations for critically ill patients. For this reason, the emergence of endovascular stent-graft placement (ESGP), a completely different approach, had a substantial and positive impact on management of aortic disease (Parodi et al 1991; Dake et al 1994). Many studies have investigated the effectiveness of ESGP for abdominal aortic aneurysm (AAA) prior to its application for thoracic aortic disease (Moore and Rutherford 1996; Buth and Laheij 2000; Harris et al 2000; Buth, Harris, et al 2002). Although the long-term outcome of ESGP for AAA was not as satisfactory as initially expected (Bequemin et al 1999; Buth, van Marrewijk, et al 2002; Alric et al 2003; Jacobs et al 2003; Sampram et al 2003), the number of ESGPs for AAA has not diminished as an initial treatment, even following the

Correspondence: Yoshihiko Kurimoto  
Department of Traumatology and  
Critical Care Medicine, Sapporo Medical  
University, South 1 West 16, Chuoku,  
Sapporo 060-8543, Japan  
Tel +81 11 611 2111  
Fax +81 11 611 4963  
Email kurimoto@sapmed.ac.jp

disappointing reports (Buth, Jajibi, et al 2002). We believe that the reason for this is that ESGP is less invasive.

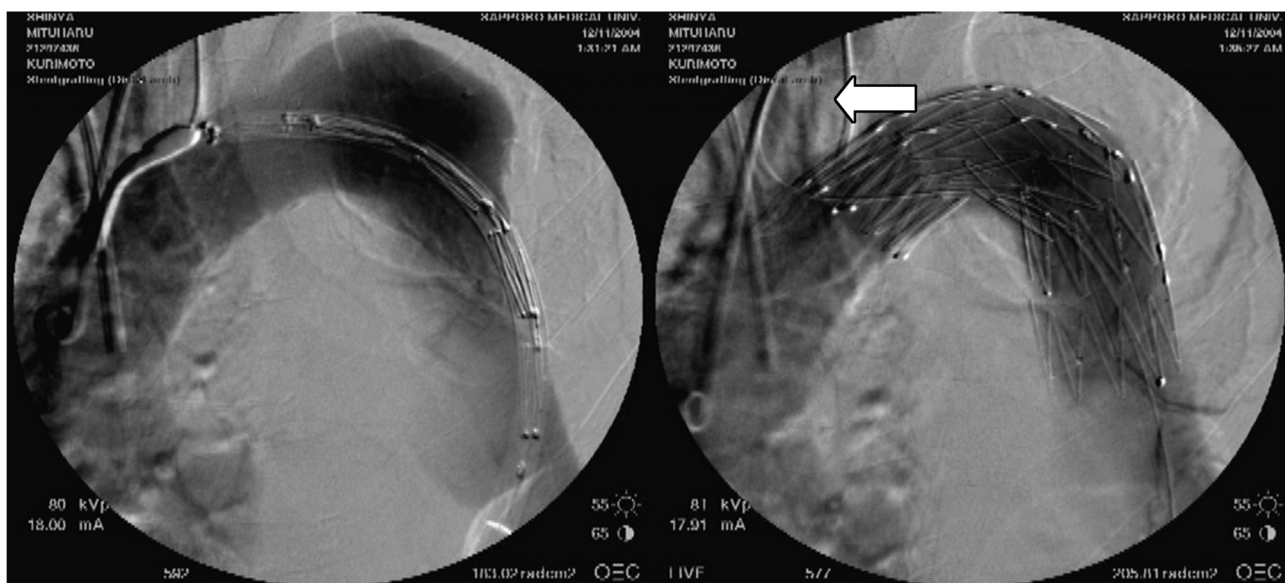
As is the case with AAA, the early outcome of ESGP for thoracic aortic disease seems satisfactory compared with conventional open surgery. Recently, the middle-term outcome (a few years postoperative) of ESGP for thoracic aortic disease has been reported to be acceptable (Doss et al 2004; Milnitchouk et al 2004; Makaroun et al 2005). Although there are only a few reports assessing the long-term outcome with follow-ups of five years or more (Orend et al 2003; Demers et al 2004), considerable stent-graft related events have been confirmed. It is easy to understand that localized aortic diseases, such as penetrating aortic ulcer, anastomotic pseudoaneurysm, and aortic isthmus injury, can be treated well by ESGP, but further follow-up assessments are still necessary to determine the appropriate treatment for elective cases of thoracic aortic disease.

On the other hand, ESGP has also been performed for emergency cases of acute thoracic aortic disease, in view of the high mortality of open surgical treatment (Miller et al 1984; Cowley et al 1990; Crawford et al 1991; Johansson et al 1995; von Segesser et al 1996; Miller and Calhoun 1997; Nienaber et al 1999; Lemaire et al 2002). It is rational that ESGP is applied for debilitated patients with aortic emergency if ESGP is less invasive. Based on the reported satisfactory early outcome of ESGP for thoracic aortic disease (Mitchell et al 1999; Bortone et al 2004), ESGP seems to contribute to better outcome as an initial treatment for aortic emergency.

We review reports on the use of ESGP for thoracic aortic emergency, divided into three categories; ruptured thoracic aortic aneurysm, blunt aortic injury, and complicated aortic dissection.

## Ruptured degenerative thoracic aortic aneurysm

Generally, the affected population is of an older age with a variety of comorbidities. Despite advancements in open surgical techniques, early mortality rate is still high (Crawford et al 1991; Mastroroberto and Chello 1999) and 50% in elderly patients (Huynh et al 2002). Several important points must be addressed to perform ESGP successfully, including identification of an access artery and accurate configuration of the ruptured aortic aneurysm. One popular reason for unsuccessful ESGP was reported to be access route troubles (Makaroun et al 2005). The latter investigators have reported that conduits to deliver the stent-graft system were required in approximately 15% of patients with thoracic aortic aneurysm. In order to choose ESGP for an emergency case, it is necessary that the left subclavian artery (LSA) does not originate from the ruptured aortic aneurysm (Figure 1). Although the usual indications for elective ESGP have reported that an aortic diameter of proximal and distal landing zone should be less than 40 mm, depending on available endoprosthesis, and a length for both landing zones of more than 20 mm (at least 10 mm) (Greenberg et al 2005; Makaroun et al 2005), emergency ESGP had to be often performed in even unfavorable



**Figure 1** 92-year-old man with distal aortic arch aneurysm ruptured into mediastinum. The left subclavian artery is covered by the stent graft, but full patency of the left carotid artery is achieved by the fenestrated stent graft (white arrow).

anatomical states. It is recognized that imaging modalities, such as computed tomography (CT) angiography and magnetic resonance (MR) angiography, are preferable to evaluate suitability of patients for ESGP if the patients' clinical condition allows further examinations. According to previously published reports, it seems to be a relatively safe technique to occlude the LSA intentionally by stent graft in order to make a proximal neck (Czermak et al 2002; Görich et al 2002; Destrieux-Garnier et al 2004; Dagenais et al 2005). On the other hand, carotid left subclavian bypass has commonly been performed before placing stent graft proximal to the LSA in the US (Makaroun et al 2005). Theoretically, cerebellar or brain stem ischemia is possible following occlusion of the LSA (van Herzele et al 2003) and we experienced that LSA occlusion test revealed the patient in whom the LSA was crucial for brain circulation (Kurimoto et al 2005), but this infrequent adverse event might be an acceptable risk in such emergency situations.

Currently, there are only a few reports which consist of more than 10 cases of ruptured degenerative thoracic aortic aneurysm (Doss et al 2004; Scheinert et al 2004), and early mortality rates are reportedly around 10%, although there are some reports with a small number of cases in which early mortality rate is almost 0% (Semba et al 1997; van Herzele et al 2003; Bortone et al 2004; Ianneli et al 2004; Milnitchouk et al 2004; Morishita et al 2004). Despite the fact that there are no reports presenting the results of ruptured degenerative thoracic aortic aneurysm in exclusion from other acute aortic diseases, there is a possibility that ESGP provides a better early mortality rate than conventional open surgery. In addition, postoperative morbidity is also superior in ESGP, as exemplified by shorter periods of mechanical ventilator support and lower rates of postoperative renal failure. In particular, postoperative paraplegia, a devastating complication which sometimes occurs following descending thoracic aorta operation, has rarely happened with ESGP, even in emergency operations. Most studies have reported a 0% postoperative paraplegia rate (Semba et al 1997; van Herzele et al 2003; Bortone et al 2004; Destrieux-Garnier et al 2004; Ianneli et al 2004; Morishita et al 2004; Scheinert 2004) and a few disclose a 4% rate of paraparesis (Dake et al 1994; Dagenais et al 2005). It is likely that post-stent-grafting paraplegia is very rare even in emergency cases of thoracic aortic diseases, as well as in elective cases. In addition, most cases with post-stent-grafting spinal ischemic complication seem to be able to recover to some degree following some rehabilitation.

In contrast to the satisfactory early outcome (Mitchell et al 1999; Bortone et al 2004; Grabenwoger et al 2004), there seems to be problems in the follow-up periods after ESGP (Buth and Laheij 2000). In the first few years after ESGP, there are rarely serious stent-graft related events. However, re-rupture secondary to endoleak or stent-graft migration has been reported in the middle-term periods, especially 5 or more years after ESGP (Buth and Laheij 2000), in cases who were not closely checked by CT examination after ESGP and for whom appropriate treatments, such as re-ESGP, were not performed.

Nevertheless, for elderly patients with significant comorbidity, ESGP is still a preferable initial treatment of choice for ruptured degenerative thoracic aortic aneurysm if the configuration of aneurysm allows it. In near future, the use of branched grafts might further expand the indication for stent-grafting for ruptured distal arch aneurysm (Schneider et al 2003).

## Blunt aortic injury

Since an anecdotal report by Parmley et al (1958), immediate open surgical treatment has been recommended to avoid re-rupture of pseudoaneurysm at the aortic isthmus. However, most patients with blunt aortic injury (BAI) are complicated with other serious injuries, such as head injury, which do not always allow immediate open repair of the injured aorta. Despite recent advancements in surgical techniques, extracorporeal bypass and aortic clamping are still potentially harmful for these patients. In this context, the timing of open repair of injured aorta has been controversially discussed for a decade because conventional open repair is possibly too invasive for multi-trauma patients (Walker and Pate 1990; Holmes et al 2002; Rousseau et al 2005).

However, the emergence of ESGP has changed surgical strategy for BAI and partially resolved some clinical dilemmas regarding thoracotomy, unilateral lung ventilation, aortic clamping, and heparinization for extracorporeal bypass. In the period when there were only the two choices of open repair or conservative treatment, initial conservative treatment and delayed open repair may well have been a reasonable strategy (Holmes et al 2002; Rousseau et al 2005), considering the high mortality associated with immediate open repair (Walker and Pate 1990). Nowadays, we know that ESGP is less invasive and very effective for BAI (Marty-Ane et al 2003; Dunham et al 2004; Neuhauser et al 2004; Wellons et al 2004; Rousseau et al 2005).

Considering the fact that 10% of BAIs have the possibility to re-rupture in the acute phase despite medical treatment (Fabian et al 1997; Holmes et al 2002), ESGP should be performed as early as possible if the patients can be transferred to an operating room or angiography suite.

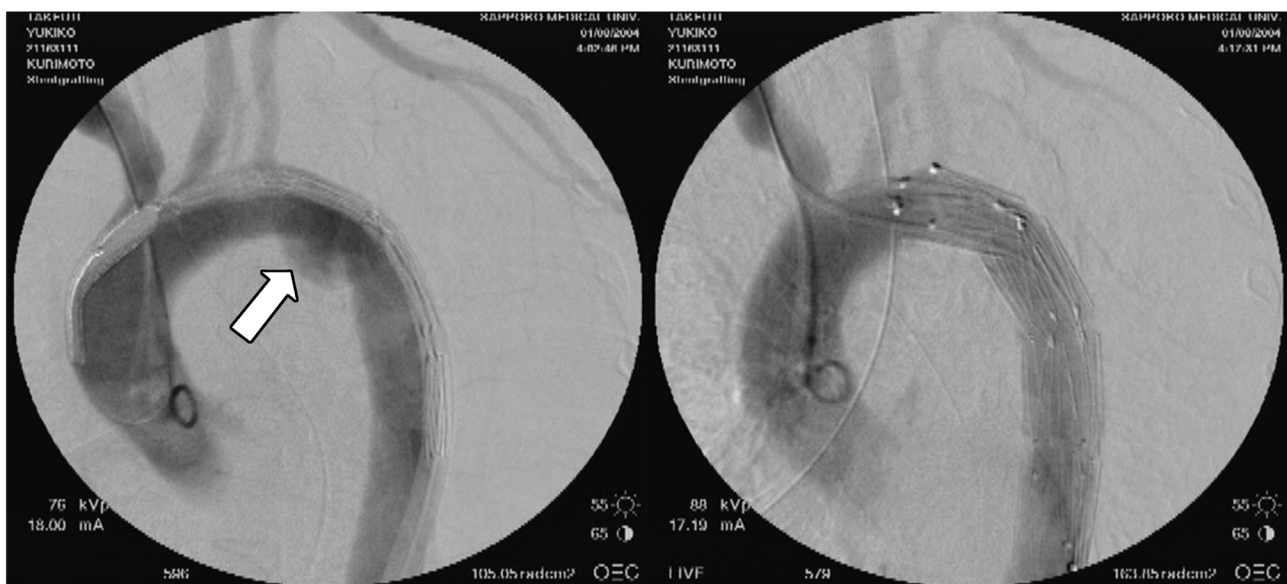Although there is no report that describes which type of BAI is indicated for initial conservative treatment, traumatic type B aortic dissection and pseudoaneurysm without mediastinal hematoma are probably candidates (Frykberg et al 1991). Since ascending aorta injury is fatal, commonly combining with cardiac injury or cardiac tamponade (Parmley et al 1958; Fishbone et al 1973), the incidence of BAIs affecting the aortic isthmus is high at more than 80% in patients who can be clinically treated for BAI (Duhaylongsod et al 1992; Fabian et al 1997). With the exception of young patients with acutely angled distal arch, ESGP seems to be very well suited to BAI because of the localized affect of the lesion, small diameter of aorta for landing neck and easy access to the injured aorta (Figure 2).

Early mortality rate of ESGP for BAI is almost zero in many reports (Marty-Ane et al 2003; Dunham et al 2004; Neuhauser et al 2004; Wellons et al 2004; Rousseau et al 2005). The cause of early death after ESGP was reportedly due to other concomitant critical injuries (Dunham et al 2004). The postoperative paraplegia rate following open repair for BAI is approximately 5% even when using distal aortic perfusion, which has been a concern because the patients are relatively young compared with those with

degenerative aortic aneurysm (Fabian et al 1997; Rousseau et al 2005). Certainly, the introduction of ESGP has made this devastating complication very rare (Marty-Ane et al 2003; Dunham et al 2004; Neuhauser et al 2004; Wellons et al 2004; Rousseau et al 2005) but a small number of cases have needed re-ESGP due to secondary endoleak (Neuhauser et al 2004). Critical events, such as rupture, are very rare in the middle term after ESGP. However, considering the small diameter of the aorta in young patients, migration of the deployed stent graft of small size is highly possible in some decades after ESGP (Duhaylongsod et al 1992). For the time being, indication of ESGP for young patients should be limited to those complicated with severe brain injury.

## Complicated aortic dissection

Except for Stanford type A retrograde aortic dissection (Doenst et al 2000), Stanford type B aortic dissection is a possible candidate for ESGP. Generally, type B aortic dissection has been managed by conservative treatment in acute phase if no dissection-related complications were present (Umana et al 2002; Suzuki et al 2003; Kusagawa et al 2005). The in-hospital mortality rate of acute type B was an average of 13% and was highest for patients who required surgery, at 32% (Suzuki et al 2003). Seventy percent of patients died from rupture with visceral ischemia being the next most frequent cause at 19% (Suzuki et al 2003). Emergency surgery has been performed for ruptured descending thoracic aorta and organ ischemia secondary to



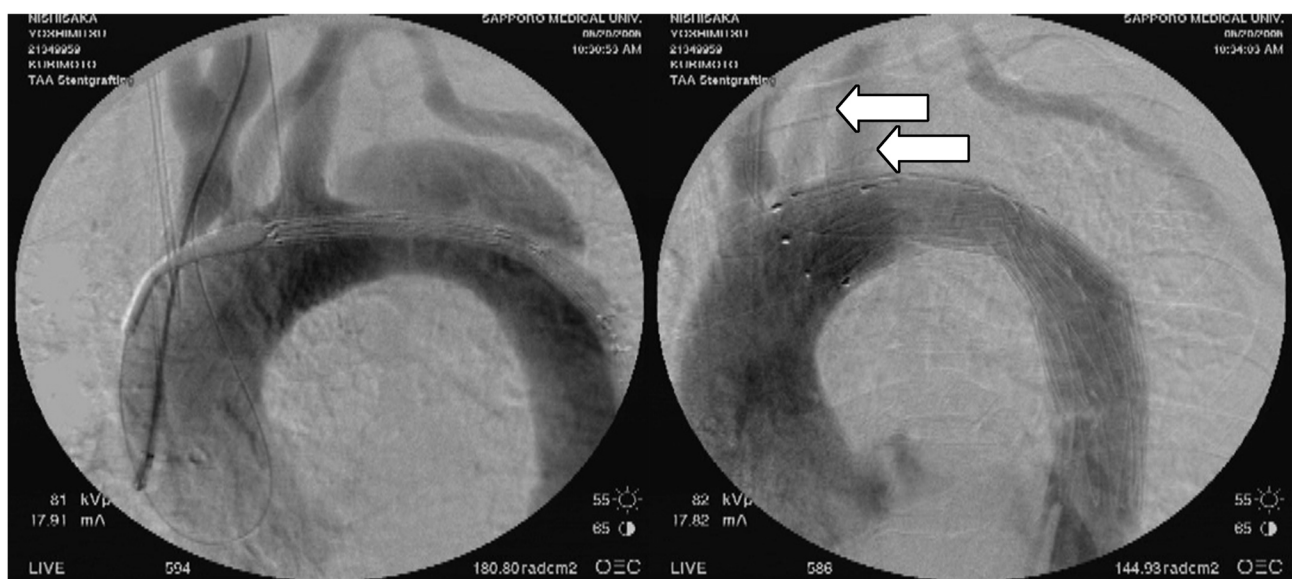
**Figure 2** 74-year-old woman with blunt aortic injury associated with intracranial hemorrhage and pelvic fracture. Emergency stent-grafting was performed 2 hours after arrival. Typical aortic isthmus injury (white arrow) is well excluded by the stent graft.

aortic branch malperfusion. Mortality rates for type B dissection with hypotension due to rupture or with organ ischemia were as high as 61.6% and 45.5%, respectively (Suzuki et al 2003).

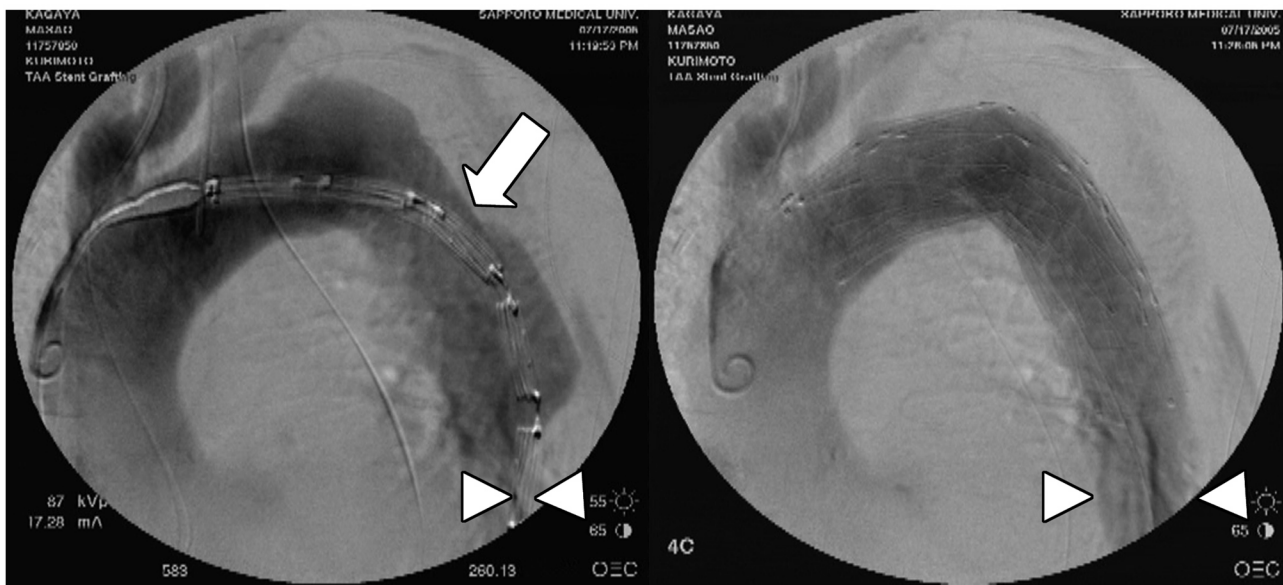
Aortic side branch occlusion associated with spontaneous acute aortic dissection was common, with an incident rate of 40% (Cambria et al 1988; Lauterbach et al 2001). Surgical procedure to restore the flow into an ischemic organ depends on whether the mechanism of aortic branch occlusion is dynamic or static (Lauterbach et al 2001; Beregi et al 2003; Vedantham et al 2003). Open surgical fenestration has been performed in cases of dynamic mechanism in which a true lumen of aorta is critically compressed by an expanded false lumen (Cambria et al 1988; Deeb et al 1997; Oderich and Panneton 2002). Lauterbach et al (2001) reported a recent improvement of in-hospital mortality rate to 23% in the group with end-organ ischemia (Cambria et al 1988). It was reported that after aortic rupture or tamponade is ruled out, mesenteric and renal revascularization precedes a proximal aortic operation, most often by open aortic fenestration (Lauterbach et al 2001). Deeb et al (1997) also recommended management of end-organ malperfusion prior to proximal aortic replacement even in cases of acute type A dissection (Oderich and Panneton 2002). Contrarily, Fann et al (1990) reported a 92% resolution of upper and lower limb ischemia following proximal aortic repair and insisted that proximal aortic operation should be performed first for cases of acute aortic dissection complicated with peripheral vascular

malperfusion, including mesenteric ischemia (Elefteriades et al 1990). Although endovascular treatments, such as balloon fenestration and stent placement, for end-organ ischemia caused by acute aortic dissection have been reported for selected patients (Fann et al 1990; Lauterbach et al 2001; Beregi et al 2003), the emergence of ESGP has changed surgical strategy for cases with complicated acute aortic dissection including rupture at the descending thoracic aorta (Slonim et al 1999; Bortone et al 2002; Herold et al 2002; Hutschala et al 2002; Duebener et al 2004).

The two main determinants of death due to acute type B dissection, shock from rupture (Figure 3) and visceral ischemia (Figure 4) (Umana et al 2002; Suzuki et al 2003), could be managed less invasively by ESGP with or without conventional endovascular interventions (Fann et al 1990; Slonim et al 1999; Doenst et al 2000; Lauterbach et al 2001; Herold et al 2002; Hutschala et al 2002; Beregi et al 2003; Duebener et al 2004). Considering reports of insufficient fenestrated re-entry size to rescue malperfusion in the acute phase and rupture in the late phase following percutaneous fenestration, primary entry closure using stent grafts seems to be preferable in cases with malperfusion by the dynamic mechanism (Cambria et al 1988; Bortone et al 2002). Initially, an early mortality rate of 16% was reported in patients with complicated acute type B dissection treated by ESGP (Williams et al 1990). Recent reports disclosed less than 10% early mortality with ESGP for complicated acute aortic dissection (Doenst et al 2000; Herold et al 2002; Hutschala et al 2002; Duebener et al 2004). Early outcomes



**Figure 3** 57-year-old man with acute type IIIa aortic dissection ruptured into the left pleural cavity. In addition to complete entry closure, full patency of the left carotid artery and the left subclavian artery is achieved by the fenestrated stent graft (white arrow).



**Figure 4** 81-year-old man with acute type IIIa aortic dissection complicated with visceral and leg ischemia. The entry site (white arrow) was revealed by intravascular ultrasound (IVUS) before deployment of the stent graft. Critically compressed true lumen of the distal descending thoracic aorta is sufficiently expanded by the entry closure using the stent graft (white arrowheads).

of ESGP were satisfactory. However, ESGP cannot close all entries or re-entries through the aorta, which means there is a possibility that endotension of a false lumen continues and causes critical late complications, such as re-rupture and aorto-esophageal fistula (Dake et al 1999; Duebener et al 2004). Even if the possibility of endotension remains, the value of ESGP is not reduced because patients undergo a second intervention, including open surgery, with acceptable results due to their stabilized condition. There are still some unclear problems in ESGP for aortic dissection including intramural hematoma which is obviously one possible lethal disease. Thus, there is a need to stress the importance of close follow-up to avoid devastating late complications.

## References

- Alic P, Hinchliffe RJ, Wenham PW, et al. 2003. Lessons learned from the long-term follow-up of a first-generation aortic stent graft. *J Vasc Surg*, 37:367-73.
- Bequemin JP, Lapie V, Favre JP, et al. 1999. Mid-term results of a second generation bifurcated endovascular graft for abdominal aortic aneurysm repair: The French Vanguard trial. *J Vasc Surg*, 30:209-18.
- Beregi JP, Haulon S, Ota P, et al. 2003. Endovascular treatment of acute complications associated with aortic dissection: Midterm results from a multicenter study. *J Endovasc Ther*, 10:486-93.
- Bortone AS, Schena S, D'Agostino D, et al. 2002. Immediate versus delayed endovascular treatment of post-traumatic aortic pseudoaneurysms and type B dissections: Retrospective analysis and premises to the upcoming European trial. *Circulation*, 106(Suppl 1):1-234-40.
- Bortone AS, Cillis ED, D'Agostino D, et al. 2004. Endovascular treatment of thoracic aortic disease: four years of experience. *Circulation*, 110(Suppl II):II-262-7.

- Buth J, Laheij RJF. 2000. Early complications and endoleaks after endovascular abdominal aortic aneurysm repair: Report of a multicenter study. *J Vasc Surg*, 31:134-46.
- Buth J, Harris PL, van Marrewijk C. 2002. Causes and outcomes of open conversion and aneurysm rupture after endovascular abdominal aortic aneurysm repair: Can type II endoleaks be dangerous? *J Am Coll Surg*, 194(Suppl 1):S98-102.
- Buth J, van Marrewijk CJ, Harris PL, et al. 2002. Outcome of endovascular abdominal aortic aneurysm repair in patients with conditions considered unfit for an open procedure: A report on the EUROSTAR experience. *J Vasc Surg*, 35:211-21.
- Buth RL, Jajibi S, Lin PH, et al. 2002. Conservatism and new technology: The impact on abdominal aortic aneurysm repair. *Am Surg*, 68:57-60.
- Cambria RP, Brewster DC, Gertler J, et al. 1988. Vascular complications associated with spontaneous aortic dissection. *J Vasc Surg*, 7:199-209.
- Cowley RA, Turney SZ, Hankins JR, et al. 1990. Rupture of thoracic aorta caused by blunt trauma. A fifteen-year experience. *J Thorac Cardiovasc Surg*, 100:652-61.
- Crawford ES, Hess KR, Cohen ES, et al. 1991. Ruptured analysis according to size and treatment. *Ann Surg*, 213:417-26.
- Czermak BV, Waldenberger P, Perkmann R, et al. 2002. Placement of endovascular stent-grafts for emergency treatment of acute disease of the descending thoracic aorta. *AJR*, 179:337-45.
- Dagenais F, Normand JP, Turcotte R, et al. 2005. Changing trends in management of thoracic aortic disease: Where do we stand with thoracic endovascular stent grafts? *Can J Cardiol*, 21:173-8.
- Dake MD, Miller DC, Semba CP, et al. 1994. Transluminal placement of endovascular stent-grafts for the treatment of descending thoracic aortic aneurysms. *N Engl J Med*, 331:1729-34.
- Dake MD, Kato N, Mitchell RS, et al. 1999. Endovascular stent-graft placement for the treatment of acute aortic dissection. *N Engl J Med*, 340:1546-52.
- Deeb GM, Williams DM, Bolling SF, et al. 1997. Surgical delay for acute type A dissection with malperfusion. *Ann Thorac Surg*, 64:1669-77.
- Demers P, Miller DC, Mitchell RS, et al. 2004. Midterm results of endovascular repair of descending thoracic aortic aneurysms with first-generation stent grafts. *J Thorac Cardiovasc Surg*, 127:664-73.

- Destrieux-Garnier L, Haulon S, Willoteaux S, et al. 2004. Midterm results of endoluminal stent grafting of the thoracic aorta. *Vascular*, 12:179-85.
- Doenst T, Schlensak C, Beyersdorf F. 2000. Limitations to the therapeutic potential of endoluminal stent placement in the thoracic aorta. *Circulation*, 101:e96.
- Doss M, Wood JP, Balzer J, et al. 2004. Emergency endovascular interventions for acute thoracic aortic rupture: Four-year follow-up. *J Thorac Cardiovasc Surg*, 129:645-51.
- Duebener LF, Lorenzen P, Richardt G, et al. 2004. Emergency endovascular stent-grafting for life-threatening acute type B aortic dissections. *Ann Thorac Surg*, 78:1261-7.
- Duhaylongsod FG, Glower DD, Wolfe WG. 1992. Acute traumatic aortic aneurysm: the Duke experience from 1970 to 1990. *J Vasc Surg*, 15:331-43.
- Dunham MB, Zygun D, Petrsek P, et al. 2004. Endovascular stent grafts for acute blunt aortic injury. *J Trauma*, 56:1173-8.
- Eggebrecht H, Baumgart D, Radecke K, et al. 2004. Aorto-esophageal fistula secondary to stent-graft repair of the thoracic aorta. *J Endovasc Ther*, 11:161-7.
- Elefteriades JA, Hammond GL, Gusberg RJ, et al. 1990. Fenestration revisited. *Arch Surg*, 125:786-90.
- Fabian TC, Richardson JD, Croce MA, et al. 1997. Prospective study of blunt aortic injury: Multicenter trial of the American Association for the Surgery of Trauma. *J Trauma*, 42:374-80.
- Fann JI, Sarris GE, Mitchell RS, et al. 1990. Treatment of patients with aortic dissection presenting with peripheral vascular complications. *Ann Surg*, 212:705-13.
- Fattori R, Napoli G, Lovato L, et al. 2002. Indication for, timing of, and results of catheter-based treatment of traumatic injury to the aorta. *AJR*, 179:603-9.
- Fishbone G, Robbins DI, Osborn DJ, et al. 1973. Trauma to the thoracic aorta and great vessels. *Radiol Clin North Am*, 11:543-53.
- Frykberg ER, Crump JM, Dennis JW, et al. 1991. Non-operative observation of clinically occult arterial injuries: a prospective evaluation. *Surgery*, 109:85-96.
- Görich J, Asquan Y, Seifarth H, et al. 2002. Initial experience with intentional stent-graft coverage of the subclavian artery during endovascular thoracic aortic repairs. *J Endovasc Ther*, 9(Suppl II):II-39-II43.
- Grabenwoger M, Fleck T, Ehrlich M, et al. 2004. Secondary surgical interventions after endovascular stent-grafting of the thoracic aorta. *Eur J Cardio-thorac Surg*, 26:608-13.
- Greenberg RK, O'Neill S, Walker E, et al. 2005. Endovascular repair of thoracic aortic lesions with the Zenith TX1 and TX2 thoracic grafts: Intermediate-term results. *J Vasc Surg*, 41:589-96.
- Harris PL, Vallabhaneni SR, Desgranges P, et al. 2000. Incidence and risk factors of late rupture, conversion, and death after endovascular repair of infrarenal aortic aneurysms: The EUROSTAR experience. *J Vasc Surg*, 32:739-49.
- Herold U, Piotrowski J, Baumgart D, et al. 2002. Endoluminal stent graft repair for acute and chronic type B aortic dissection and atherosclerotic aneurysm of the thoracic aorta: an interdisciplinary task. *Eur J Cardio Thorac Surg*, 22:891-7.
- Holmes JH, Bloch RD, Hall RA, et al. 2002. Natural history of traumatic rupture of the thoracic aorta managed nonoperatively: A longitudinal analysis. *Ann Thorac Surg*, 73:1149-54.
- Hutschala D, Fleck T, Czerny M, et al. 2002. Endoluminal stent-graft placement in patients with acute aortic dissection type B. *Eur J Cardio Thorac Surg*, 21:964-9.
- Huynh TTT, Miller CC, Estreza AL, et al. 2002. Thoracoabdominal and descending thoracic aortic aneurysm surgery in patients aged 79 years or older. *J Vasc Surg*, 36:469-75.
- Ianneli G, Piscione F, Di Tommaso L, et al. 2004. Thoracic aortic emergencies: impact of endovascular surgery. *Ann Thorac Surg*, 77:591-6.
- Jacobs TS, Won J, Gravereaux EC, et al. 2003. Mechanical failure of prosthetic human implants: A 10-year experience with aortic stent graft devices. *J Vasc Surg*, 37:16-26.
- Johansson G, Markstrom U, Swedenborg J. 1995. Ruptured thoracic aortic aneurysms: a study of incidence and mortality rates. *J Vasc Surg*, 21:985-8.
- Kouchoukos NT, Dougenis D. 1997. Surgery of the thoracic aorta. *N Engl J Med*, 336:1876-88.
- Kurimoto Y, Asai Y, Maeda T, et al. 2005. How to deal with the left subclavian artery in endovascular stent-grafting for distal aortic arch aneurysm. *Circulation*, 112(Suppl II):II-712.
- Kusagawa H, Shimono T, Ishida M, et al. 2005. Changes in false lumen after transluminal stent-graft placement in aortic dissections. Six years' experience. *Circulation*, 111:2951-7.
- Lauterbach SR, Cambria RP, Brewster DC, et al. 2001. Contemporary management of aortic branch compromise resulting from acute aortic dissection. *J Vasc Surg*, 33:1185-92.
- Lemaire SA, Rice DC, Schmitting ZC, et al. 2002. Emergency surgery for thoracoabdominal aortic aneurysms with acute presentation. *J Vasc Surg*, 35:1171-8.
- Makaroun MS, Dillavou ED, Kee ST, et al. 2005. Endovascular treatment of thoracic aortic aneurysms: Results of the phase II multicenter trial of the GORE TAG thoracic endoprosthesis. *J Vasc Surg*, 41:1-9.
- Marty-Ane CH, Berthet JP, Branchereau P, et al. 2003. Endovascular repair for acute traumatic rupture of the thoracic aorta. *Ann Thorac Surg*, 75:1803-7.
- Mastoroberto P, Chello M. 1999. Emergency thoracoabdominal aortic aneurysm repair: clinical outcome. *J Thorac Cardiovasc Surg*, 118:477-82.
- Miller DC, Mitchell RS, Oyer PE, et al. 1984. Independent determinants of operative mortality for patients with aortic dissection. *Circulation*, 70(Suppl. I):I-153-64.
- Miller OL, Calhoun JH. 1997. Acute traumatic aortic transection. In: Kaiser LR (ed). *Mastery of cardiothoracic surgery*. Philadelphia, PA, USA: Lippincott-Raven. p 478-9.
- Milnitchouk S, Pfammatter T, Kadner A, et al. 2004. Emergency stent-graft placement for hemorrhage control in acute thoracic rupture. *Eur J Cardio Thorac Surg*, 25:1032-8.
- Mitchell RS, Miller DC, Dake MD, et al. 1999. Thoracic aortic aneurysm repair with an endovascular stent graft: The "first generation". *Ann Thorac Surg*, 67:1971-4.
- Moore WS, Rutherford RB. 1996. Transfemoral endovascular repair of abdominal aortic aneurysm: results of the North American EVT phase I trial. *J Vasc Surg*, 23:543-53.
- Morishita K, Kurimoto Y, Kawaharada N, et al. 2004. Descending thoracic aortic rupture: role of endovascular stent-grafting. *Ann Thorac Surg*, 78:1630-4.
- Neuhauser B, Czermak B, Jaszchke W, et al. 2004. Stent-graft repair for acute traumatic thoracic aortic rupture. *Am Surgeon*, 70:1039-44.
- Nienaber CA, Fattori R, Lund G, et al. 1999. Nonsurgical reconstruction of thoracic aortic dissection by stent-graft placement. *N Engl J Med*, 340:1539-45.
- Oderich GS, Panneton JM. 2002. Acute aortic dissection with side branch vessel occlusion: Open surgical options. *Semin Vasc Surg*, 15:89-96.
- Orend KH, Scharrer-Palmer R, Kapfer X, et al. 2003. Endovascular treatment in diseases of the descending thoracic aorta: 6-year results of a single center. *J Vasc Surg*, 37:91-9.
- Parmley LF, Mattingly TW, Manion WC, et al. 1958. Nonpenetrating traumatic injury of the aorta. *Circulation*, XVII:1086-101.
- Parodi JC, Palmaz JC, Barone HD. 1991. Transfemoral intraluminal graft implantation for abdominal aortic aneurysms. *Ann Vasc Surg*, 5: 491-9.
- Rousseau H, Dambrin C, Marcheix B, et al. 2005. Acute traumatic aortic rupture: A comparison of surgical and stent-graft repair. *J Thorac Cardiovasc Surg*, 129:1050-5.

- Sampram ESK, Karafa MT, Mascha EJ, et al. 2003. Nature, frequency and predictors of secondary procedures after endovascular repair of abdominal aortic aneurysm. *J Vasc Surg*, 37:930-7.
- Scheinert D, Krankenberg H, Schmidt A, et al. 2004. Endoluminal stent-graft placement for acute rupture of the descending thoracic aorta. *Eur Heart J*, 25:694-700.
- Schneider DB, Curry TK, Reilly LM, et al. 2003. Branched endovascular repair of aortic arch aneurysm with a modular stent-graft system. *J Vasc Surg*, 38:855.
- Semba CP, Kato N, Kee ST, et al. 1997. Acute rupture of the descending thoracic aorta: repair with use of endovascular stent-grafts. *JVIR*, 8:337-42.
- Slonim SM, Miller DC, Mitchell RS, et al. 1999. Percutaneous balloon fenestration and stenting for life-threatening ischemic complications in patients with acute aortic dissection. *J Thorac Cardiovasc Surg*, 117:1118-27.
- Suzuki T, Mehta RH, Ince H, et al. 2003. Clinical profiles and outcomes of acute type B aortic dissection in the current era: Lessons from the international registry of aortic dissection (IRAD). *Circulation*, 108(Suppl II): II-312-II-317.
- Svensson LG. 1997. Natural history of aneurysms of the descending and thoracoabdominal aorta. *J Card Surg*, 12:279-84.
- Umana JP, Miller DC, Michell RS. 2002. What is the best treatment for patients with acute type B aortic dissections- Medical, surgical, or endovascular stent-grafting? *Ann Thorac Surg*, 74:S1840-3.
- van Herzele I, Vermassen F, Durieux C, et al. 2003. Endovascular repair of aortic rupture. *Eur J Endovasc Surg*, 26:311-16.
- Vedantham S, Picus D, Sanchez LA, et al. 2003. Percutaneous management of ischemic complications in patients with type-B aortic dissection. *J Vasc Interv Radiol*, 14: 181-93.
- von Segesser LK, Genoni M, Kunzli A, et al. 1996. Surgery for ruptured thoracic and thoraco-abdominal aortic aneurysms. *Eur J Cardiothoracic Surg*, 10:996-1001.
- Walker WA, Pate JW. 1990. Medical management of acute traumatic rupture of the thoracic aorta. *Ann Thorac Surg*, 50: 965-7.
- Wellons ED, Milner R, Solis M, et al. 2004. Stent-graft repair of traumatic thoracic aortic disruptions. *J Vasc Surg*, 40:1095-100.
- Williams DM, Brothers TE, Messina LM. 1990. Relief of mesenteric ischemia in type III aortic dissection with percutaneous fenestration of the aortic septum. *Radiology*, 174:450-2.