

Amniotic Membrane Transplantation in Ophthalmology: An Updated Perspective

This article was published in the following Dove Press journal:
Clinical Ophthalmology

Andrew Walkden ^{1,2}

¹Manchester Royal Eye Hospital, Manchester University Foundation Trust, Manchester, UK; ²University of Manchester Faculty of Medical and Human Sciences, Manchester, Greater Manchester, UK

Aim: The aim of this paper is to provide a succinct literature review of the different clinical applications for AMT usage in an ophthalmic setting, ranging from commonly used applications to less mainstream approaches. The hope is that this review enables the reader to have a better understanding of the biological properties of amnion as well as the indications and scenarios in which AMT can be used, whilst presenting relevant evidence from within the literature which may be of interest. We also provide an update on the methods of preservation of amniotic membrane and the application methodologies.

Methods: Literature search. A PubMed search was performed using the search terms “amniotic membrane transplant”, “amnion AND cornea”, amnion AND ophthalmology”, “amnion AND ocular surface” and “Amnion AND eye”. A full review of the literature using the PubMed database was conducted up until 01/05/20. The articles used were written in English, with all articles accessed in full. Both review articles and original articles were used for this review. All full publications related to ophthalmology were considered.

Keywords: amnion, amniotic membrane transplant, amniotic membrane graft, amniotic membrane

Introduction

The placenta is usually discarded as a waste material following birth. However, amnion, the innermost layer of the placental sac can be harvested as a transplant material. AMT is useful clinically due to its unique structure, biocompatible composition and subsequent biological functions.^{1,2} Amnion was first introduced into clinical medicine as a substrate for skin transplantation³ and has since been adopted into a wide range of surgical applications including adhesion reduction,⁴ restoration of hearing,⁵ and replacing the vaginal⁶ and urethral⁷ mucous membranes.

The role of an AMT in an ophthalmic setting is usually to support damaged tissue, protect and shield defects from further degeneration or breakdown from external factors and to promote re-cellularisation.¹ This is possible due to a myriad of biological properties, including a lack of immunogenicity, thus reducing the risk of inciting an immune response.⁸ AMT also preserves and supports stem cells⁹ whilst inhibiting neoplastic,^{10,11} inflammatory,^{12,14} angiogenic and fibroblastic cells.^{1,12} When applied in combination these biological properties support and facilitate wound healing.^{8,15} Amnion has also been shown to improve pain management^{16,17} in conjunction with delivering anti-microbial benefits.^{18,20}

Correspondence: Andrew Walkden
Email walkdenandrew@gmail.com

The Historical Background of Amniotic Membrane Transplantation

In 1910, AMT was first utilised surgically as a skin graft substitute material.³ The first ophthalmic usage was in the 1940s as a conjunctival substitute after removal of fibrotic tissue,²¹ with good outcomes reported when compared with the widely used alternative of rabbit peritoneum. Its usage then fell out of favour, potentially as in this era only fresh amniotic membrane was available which was difficult to obtain, and carried a risk of bloodborne virus infection. By the early 1990s, alternative applications began to gain popularity amongst ophthalmologists for a second time. After different preservation methods were developed and refined, better storage and distribution techniques increased tissue accessibility.

The Wide-Ranging Properties of Amniotic Membrane

General Structure

Amnion is composed of five layers, usually between 20–500µm thick in total²² (see Figure 1). It consists of an epithelial monolayer supported by a basement membrane, and an extracellular matrix (ECM) stromal layer, consisting of an acellular compact layer and sparsely populated fibroblast layer. The innermost layer, called the spongy layer, acts as the interface between the fibroblastic layer of the amnion and the reticular layer of the chorion.^{23,26} By the second month of gestation, the mesenchymal cells separate from the epithelium by a layer of tissue containing loosely packed collagen fibrils and occasional fibroblastic cells. It is predominantly the collagen component of the mesenchymal layer that provides additional tensile strength.⁸ Structural proteins such as laminin, fibronectin and collagens in the amnion ECM and basement membrane provide a scaffold with which cells can interact to promote epithelial regeneration.^{27,29} At full term, a single layer of amniotic cells exists, firmly adherent to a mesenchymal layer usually six to eight cells in thickness.^{30,31} Unusually it is avascular with no direct blood supply.^{8,32,33} Although the exact role

that AM performs in the homeostasis of amniotic fluid currently remains uncertain, it has an exceptional metabolic activity during pregnancy.³⁴ As it does not have a blood supply of its own, it derives its nutrition and oxygen supply from the surrounding chorionic fluid, amniotic fluid, and fetal surface blood vessels. Energy is derived primarily through anaerobic glycolysis pathways.⁸

Anti-Angiogenic, Anti-Inflammatory, Anti-Scarring and Anti-Fibrotic Factors

The tissue's anti-inflammatory properties have been well documented within the literature.^{17,35,36} Although the exact mechanism of action is not yet understood, evidence points towards a range of properties that summate to this, such as the expression of anti-inflammatory and regulatory mediators coupled with the added ability to remove infiltrating inflammatory cells.

The amnion ECM complex contains protease inhibitors of heavy chain 1 of inter- α -trypsin and hyaluronan/pentaxin 3 (HC-HA/PTX3), which is thought to contribute to the anti-inflammatory, anti-scarring and anti-angiogenic therapeutic action.^{37,39} In addition, inhibition of the ever recognised TGF- β signal transduction within fibroblasts by mediators from the stromal layer provides additional anti-scarring properties by up-regulating matrix metalloproteinases,¹² with reduced numbers of fibroblasts shown in the cornea, limbus and conjunctiva after the application of AMT stromal matrix.¹² IL-10 is also present, which is known to reduce IL-6 and TNF alpha levels. This blocks the process of fibrosis formation by removing the activation of the profibrogenic cytokines. Authors have also shown the glycoprotein Lubricin to be present in AM, which is a naturally occurring boundary lubricant with anti-inflammatory, anti-adhesive, and anti-friction properties and this is likely to play a role in the wide-ranging functions of AMT.⁴⁰

Fibrosis development is driven by the formation of myofibroblasts, which form following the activation of keratocytes, as a response to the disruption of the ocular

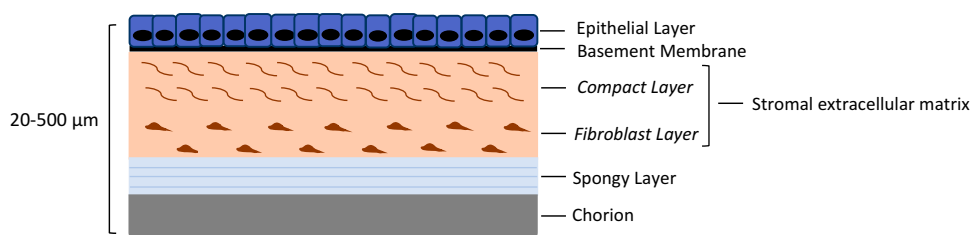


Figure 1 A diagram of the general structure of an amniotic membrane.

surface. The anti-fibrotic features of amniotic membrane act in a complementary fashion to the anti-inflammatory nature of the tissue.

Anti-Microbial Action

The antibacterial effects of both amnion and chorion are active against a range of bacteria, including Hemolytic streptococcus group A, Staphylococcus aureus, Escherichia coli and Pseudomonas aeruginosa.^{41,42} Several factors have been demonstrated to be present in amniotic fluid including bacitracin, beta-lysin, lysozyme, transferrin, and immunoglobulins. Progesterone hormones present in the amniotic fluid are also said to be bacteriostatic against some gram-positive organisms.^{41,43}

Amnion secretes elafin (peptidase inhibitor 3) and secretory leukocyte proteinase inhibitor, both of which have antimicrobial action and are components of the innate immune system.⁴⁴ Amnion is also reported to have antiviral properties due to the analogue of a cystine proteinase inhibitor, cystatin E.⁴⁴

Promotion of Epithelisation

Amnion's ECM and epithelial layers are interspersed with a complement of trophic components, in particular, epidermal growth factor, keratocyte growth factor and neurotrophic substances that support the wound healing properties of the matrix mentioned above. This complex interplay of healing components uniquely regulates and promotes regenerative healing.^{45,46} The structure and especially the collagen composition of AM's basement membrane closely resemble that of the conjunctiva and cornea. This allows it to act as a substrate on which epithelial cells can easily replicate. AM is said to have multiple effects on the regenerating corneal epithelium, including facilitation of migrating epithelial cells^{47,48} and reinforcing basal epithelial cell adhesion.⁴⁹ It also plays a role in the promotion cell differentiation^{50,51} and blockade of apoptosis.^{52,53} These features mean it can be useful in cases of non-healing or persistent epithelial defects, as will be discussed later on in this review.

Amniotic Membrane Procurement and Manufacture

Procurement of Amniotic Membrane

Amnion is procured from consenting mothers who are undergoing elective caesarean sections. All donors answer a lifestyle questionnaire, which is used to minimise the hazard of any transmissible diseases by removing

potentially "high risk" donors. For all consenting donors, blood samples are extensively tested for any viral infections or disease markers to ensure the risk of transmission from transplantation is minimised.

The physical processing of amniotic membrane is conducted under sterile conditions and the tissue is washed using antibacterial and antifungal agents. Following this the chorion is usually removed prior to processing,^{54,55} but this does vary between amnion manufacturers. Amnion is then preserved to allow long-term storage of the tissue; this can be conducted in multiple ways as discussed below.

Methods of Amniotic Membrane Preservation

It must be noted that all preservation methods cause some degree of compromise to integrity of the tissue.

Cryopreservation

Cryopreservation is the most common technique of preservation. Cryopreservation involves adding a storage medium to the tissue, such as Dulbecco's Modified Eagle Medium containing cryoprotectants such as glycerol, and freezing to -80°C . When cooled to these temperatures, degradation through unregulated enzymatic reactions is said to be limited. Some reports within the literature suggest that freezing may lead to ice crystal formation which potentially damages cellular integrity, and the thawing process prior to application may result in a loss of soluble proteins that are important to the wound healing process^{55,56} such as the aforementioned angiogenic factors.⁵⁶

Freeze-Drying/Lyophilisation

Freeze-drying involves cooling the amnion to -80°C and then a process of sublimation follows in order to remove the water from the tissue. Gamma irradiation is used in order to sterilise the tissue. This process can inflict similar ice crystal damage to the tissue as cryopreservation, but unlike cryopreserved products, these do not have cold chain storage logistical issues and do not require thawing prior to use.⁵⁷ Lyophilisation is a method that consists of removing water by a sublimation process. This results in the inhibition of chemical reactions that lead to adverse alteration of tissues.⁵⁷ Lyophilised tissue can then be stored at room temperature for long periods facilitating transportation, thus resolving the two main disadvantages of cryopreservation. Authors comparing cryopreserved and lyophilized samples have shown the presence of type IV collagen throughout the basement membranes, in both cryopreserved

and lyophilized samples.⁵⁷ Growth factors and total protein content were not significantly different in either preservation method, other than certain fibroblast growth factors were higher in cryopreserved samples.

Dehydration and Low-Temperature Vacuum Evaporation

Air or heat can be utilised to remove the moisture and dehydrate the tissue. Dehydrated amniotic membrane does not have the issues related to lyophilised or cryopreserved amnion, as it does not involve a step where the tissue is frozen. Gamma irradiation is used to sterilise the tissue.

This evaporation process uses a sugar protectant, such as trehalose,⁵⁸ before undergoing a low-temperature vacuum process to remove any water content from the tissue in a controlled process. Sugar protectants such as trehalose replace intracellular water during dehydration or freezing to form a glassy matrix, therefore preventing the major disruption of internal cell organelles, keeping the tissue viable.^{56,59} Similar to dehydrated amnion, this process does not include any freezing steps throughout. Some authors suggest that this method provides a superior substrate compared to conventional cryopreserved AM,⁵⁶ although there are some conflicting reports.⁵⁴ In addition, this product is stable allowing it to be transported globally for use in clinical and military sectors.⁵⁶

Application Methods

The application method for transplantation will depend on the aetiology of the disease. The depth and size of the wound and the area of the ocular or mucosal surface that has been affected, are all contributing factors. Publications available from within the literature have excellent images detailing the different forms of transplant methods.⁶⁰ In addition, please see [Figure 2](#).

Inlay Transplantation (Graft)

Inlay transplantation involves the amnion being grafted into the damaged ocular surface after the defective tissue has been removed from the site. Amnion acts a replacement for the lost tissue. A graft is permanently incorporated and remodelled into the host corneal matrix over time. Dependent on the depth of the wound, single or multilayer grafts may be used. Amnion's ability to integrate into the corneal stroma is possible due to the formation of hemidesmosomes and desmosomes.⁶¹ These keratinocytes provide both stability and anchorage, which allow for amnion to help improve the structural quality of the tissue.^{62,63} Amnion is placed epithelial side up, as the membrane is able to act as

a substrate for epithelial regeneration. Usually, a rim of epithelium is removed from the periphery of the stromal defect to ensure that no overlapping epithelium remains, reducing the chances of proliferation underneath the graft. This helps the epithelium to grow over the inlay graft, acting as a basement membrane.⁶⁰ At times, residual membrane may remain visible as wavy white lines or superficial "scar" tissue has been incorporated into the cornea.

Onlay Transplantation (Patch)

Onlay or "patch" amnion transplantation is the addition of the tissue epithelial side down over the periphery of a superficial wound.^{8,55} The transplant acts as a temporary biological dressing, which is able to protect the wound by providing a physical barrier against: environmental damage; the formation of symblepharon and ankyloblepharon; and any further physical insult. Proteins are secreted from the amniotic membrane onto the ocular surface. These proteins limit fibrosis and scarring, allowing for an environment for effective wound healing. Onlay transplantations will remain on the surface of the eye until removed or the product self-degrades. The transplant is not intended to become integrated into the cornea.

Combinatorial (Sandwich) Transplantation

Combinatorial transplantation utilises both the inlay and onlay methodologies of transplantation. The graft provides structural integrity, whilst the patch allows for the protection of the graft.^{1,8} Both of the transplants are able to deliver anti-inflammatory and pro-epithelisation factors.⁶¹ The epithelium is expected to grow between the two layers⁸ if the orientation of the graft (epithelial side up) and patch (epithelial side down) is used in this manner.

Ocular Surface Reconstruction: Graft

Corneal Ulceration and Persistent Epithelial Defects

AMT can be incorporated into the treatment of corneal ulcers by any of the methods of application mentioned above: i) Inlay, ii) Onlay, iii) Combinatorial Technique. The chosen method of application will depend on the depth of the ulceration, desired effect from AMT and surgeon preference.

Schuerch et al⁶⁴ 's retrospective analysis studying non-epithelialising corneal ulcers refractory to standard medical

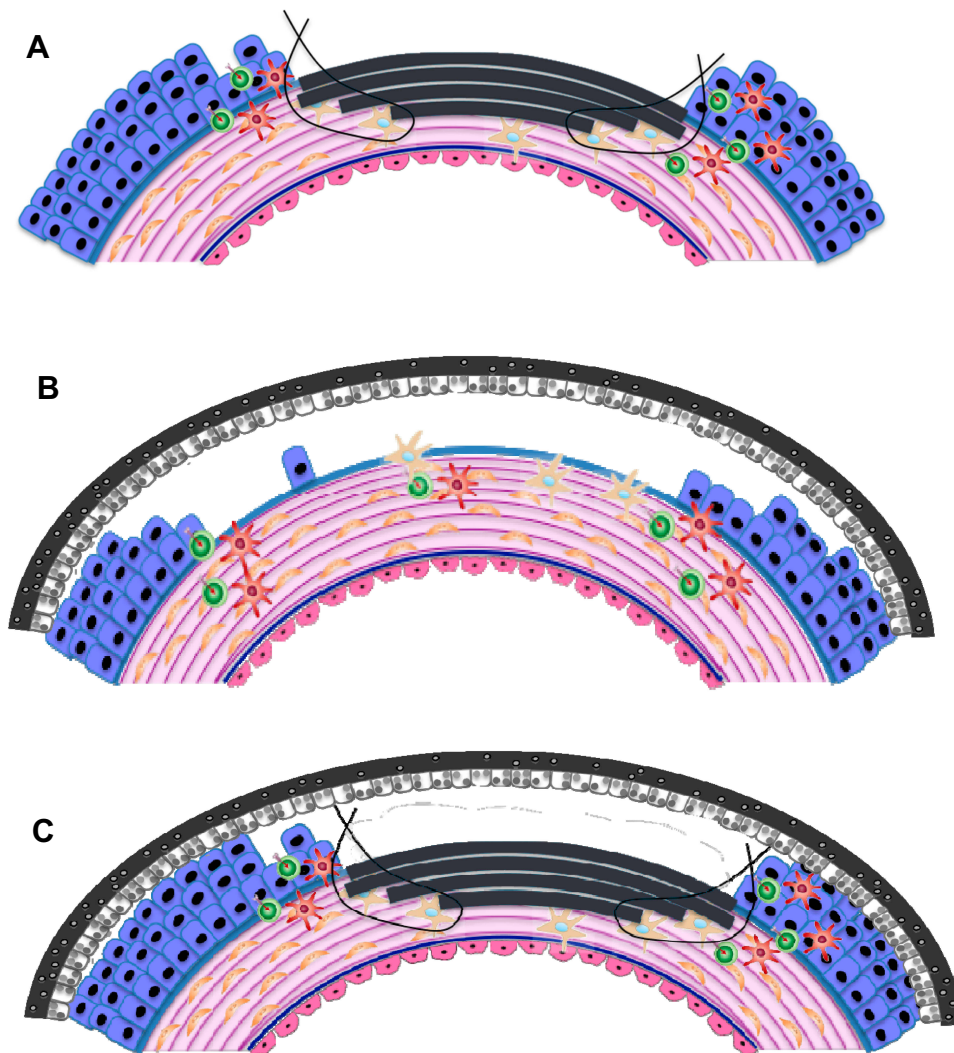


Figure 2 Schematic depicting potential applications and orientation of AMT (depicted in grey) on the ocular surface. **(A)** Inlay (graft) amnion transplantation. Epithelial-side-up: amnion replaces lost stromal tissue, up to the basement membrane. **(B)** Onlay (patch) transplantation where amnion is placed epithelial-side-down over the wound periphery as a temporary biological dressing. **(C)** Combinatorial/Sandwich AMT.

therapy included 149 eyes. It is important to note that a variety of ulcer aetiologies were included, with the majority being herpetic infections or patients that had undergone previous penetrating keratoplasty. In brief, an amniotic membrane was placed with the epithelium up within the corneal epithelial defect and fixed using nylon 10–0 interrupted sutures. A second amniotic membrane with the epithelium down was placed overlapping the first layer and fixed with a continuous nylon 10–0 suture to the conjunctiva. The mean duration from the diagnosis of the corneal ulcer to AMT was 42 (range 6–46 days).⁶⁴

Ulcers due to bullous keratopathy, bacterial ulcers, herpetic ulcers and neurotrophic ulcers had the highest overall closure rates (79%, 80%, 85%, and 93%, respectively) and achieved epithelial closure mainly within the

first 3 months after AMT. Of note, those ulcers related to rheumatic disease only epithelialised in 52.5% of cases.⁶⁴

A meta-analysis by Lui et al⁶⁵ studied three different methodologies for the application of amniotic membrane in ulcer treatment (as mentioned above). The meta-analysis pooled 18 eligible studies and found the highest rate of epithelial healing was amongst the “sandwich application” group, although this technique resulted in the smallest visual improvement outcomes, making technique selection difficult.⁶⁵

Tabatabaei et al³⁵ presented the largest of the trials, studying 99 eyes, all of which were diagnosed with bacterial keratitis. After 2–5 days of topical antibiotic treatment, AMT was performed in the treatment group and standard care was continued in both groups. The tissue transplantation was

deemed safe and showed better outcomes in regard to visual acuity at 6 months ($p < 0.001$). Other studies show favourable outcomes in terms of pain management and epithelial healing when early AMT intervention (at 48 hours) is combined with topical steroid application (at 72 hours).^{66,68}

Further evidence of AMT efficacy is detailed by the findings of Fuchsluger et al⁶⁹ and Khokhar et al,⁷⁰ the latter specifically examining the use of AMT in corneal ulcers relating to neurotrophic keratopathy in a randomised control trial. AMT was found to be as effective as conventional tarsorrhaphy or bandage contact lens placement for refractory neurotrophic corneal ulcers.

Similarly, other authors have shown that usage for symptomatic, painful bullous keratopathy can improve pain scores and epithelialisation,⁷¹ although it has been suggested that given the ease and reduced cost of anterior stromal puncture techniques, these may be preferred in certain scenarios to AMT.⁷² Similar findings are seen when used in conjunction with the surgical removal of band keratopathy.⁷³ It should be noted that these studies all have relatively small patient numbers and a variety of methodologies utilised amongst them, making direct comparison of outcomes difficult.

It is also worth noting that AMT can be used in eyes that have undergone penetrating keratoplasty to treat PEDs. Seventy percent of eyes showed successful epithelial closure within 4 weeks of AMT and, interestingly, the success rate appeared to be inversely proportional to the number of previous transplants.⁷⁴

Limbal Stem Cell Deficiency (LSCD)

Progenitor stem cells for the conjunctiva and cornea have been shown to reside in the conjunctival fornices and limbal area, respectively, they then migrate onto the ocular surface and differentiate into daughter cells that continuously regenerate into the conjunctival and corneal surface epithelia. Corneal epithelial cells have been shown to migrate rapidly when limbal explants are placed on AM denuded of amniotic epithelial cells but with an intact basement membrane. Interestingly, they migrate relatively slowly when the amniotic epithelium is left intact, and at their slowest when they are grown on the stromal surface. Culturing limbal explants on an intact AM with devitalized epithelium has been shown to be conducive to the expansion of an epithelial phenotype that closely resembles limbal stem cells.⁷⁵

Amnion can be used in conjunction with limbal stem cell transplantation (LSCT) for the treatment of LSCD. Two differing in-vivo expansion surgical procedures have been developed to tackle the issue regarding the conjunctival-

cornea epithelial cell admixture that forms following LSCT procedures. Currently, sector sequential conjunctival epitheliectomy (SSCE) is used to mechanically remove any conjunctival epithelial cells which are migrating onto the cornea.⁷⁶ However, this procedure requires multiple clinic appointments following surgery and is unpleasant for patients. Both of the in-vivo stem cell expansion techniques aim to prevent conjunctival epithelial admixture contamination and therefore increase the success of LSCT.

Simple Limbal Epithelial Transplantation (SLET)

In 2012, Sangwan et al⁷⁷ reported a novel surgical technique for the treatment of limbal stem cell deficiency. Simple limbal epithelial transplantation technique involves harvesting limbal stem cells from a donor area of 2x2 mm from the superior limbus using sub-conjunctival dissection. In the recipient eye, a 360° peritomy is performed, and any vascular pannus removed. A human amnion graft was placed over the bare ocular surface and tucked under the conjunctiva, then secured in place with fibrin glue. The donor tissue was cut into small pieces and these explants placed epithelial side up on top of the amniotic membrane in a circular manner around the cornea. This technique has been further explored by a number of studies, such as Shanbhag et al⁷⁸ and Borroni et al.⁷⁹ Both these studies show SLET surgery to be an effective and safe surgical technique. One retrospective multicentre study using 68 eyes showed the success of SLET in 57 cases (83.8%) with a survival probability of greater than 80% at one-year post operatively.⁸⁰

Amnion-Assisted Conjunctival Epithelial Redirection (ACER)

ACER utilises an amnion patch to redirect the conjunctival cells and allows for the corneal epithelial cells to regenerate with potentially less dilution from any invading conjunctival epithelium. Dua et al⁸¹ reported the surgical procedure using a 360° peritomy, with donor conjunctivo-kerato-limbal grafts sutured at the six and twelve positions with an inlay amnion graft sutured into the wound bed. Following this, a large AMT is tucked under the edge of the recessed conjunctiva between the ends of the limbal explants. This outer AMT patch is held in place through the use of fibrin glue and is large enough to cover the cornea and adjacent sclera.

The aim is to ensure the conjunctival epithelial cells are redirected to only grow over the amnion, meaning the conjunctival cells are theoretically prevented from mixing with the limbal explant-derived epithelial cells; conjunctival

cells expand over the outer amnion, whilst the regeneration of the corneal epithelial surface is nurtured beneath, unhindered. Authors have shown that patients undergoing ACER require less outpatient appointments and can hopefully avoid the painful SSCE procedures.⁸¹

Cultivated Stem Cell Transplantation

In situations where there is significant bilateral limbal damage without residual LSCs, or if there is not enough healthy limbal tissue in an unaffected eye to harvest sufficient LSCs, one must consider the transplantation of ex vivo cultured and expanded cells. The usual source of cells is usually human limbal⁸² (CLET) or oral epithelium⁸³ (COMET). The cells can be taken either from the patient (autologous), a living relative or cadaver (allogenic). The reported advantage is that less than 1mm² of donor tissue is required for transplantation.^{84,85}

AM is used as described as in other conditions to act as a basement membrane scaffold for cultured cells and as a cell carrier substrate in CLET or COMET procedures. Although both de-epithelialized and intact AM has been used, de-epithelialized AM is said to be superior to intact AM because as it preserves the properties of LSCs whilst promoting the migration of LSCs.⁸⁶

Indeed, there is some evidence that using intact AM allows some LSCs to undergo epithelial–mesenchymal transition and invade the limbal stroma.^{87,88} AM has been shown to preserve limbal epithelial cells in an undifferentiated state, maintaining its naturally occurring slow cycling.^{88,91} Evidence suggests that AM provides a unique stromal microenvironment beneficial for LSC survival and expansion, whilst acting as an IL-1 antagonist to prevent cell apoptosis.⁹² Many authors show CLET to be successful, with grafts remaining stable one year post operatively with low rejection rates.^{93,100}

It is important to note however that many variables exist within the different reported studies, with success rates depending on confounding factors such as age, donor source, and cell quality.^{85,88,98,101} Fibrin glue techniques have been shown to be just as effective, although AM has wider accessibility in many countries.⁸⁸

COMET procedures have been shown to have good outcomes two years post operatively.^{102,108} There currently exists no comparative trial comparing CLET and COMET procedures so it is difficult to directly compare the clinical outcomes from different studies, although some reports show substrate-free oral mucosal cell sheet transplants to have higher success rates.^{88,106,107} Some authors would

dispute this as although a stable phenotype is achieved post operatively with this method, CK12 the corneal epithelial marker and the PAX6 eye specific transcription factor, is not expressed in transplanted oral mucosal cells,¹⁰⁹ indicating that they do not undergo a true cellular transdifferentiation.⁸⁸

Glaucoma

AMT may be used in conjunction with bleb revision for persistent leaks following trabeculectomy surgery or aqueous shunt revision. The amnion can be grafted onto the epithelial surface over the bare sclera to replace lost or damaged conjunctiva.

In 2012, Bochmann et al¹¹⁰ published a meta-analysis examining various interventions involving AMT for late-onset bleb leaks. The meta-analysis searched for a range of techniques but only a single study by Budenz et al¹¹¹ met the required criteria. In this review, amnion was not shown as an effective alternative to conjunctival advancement for reducing bleb leaks. Other reports from the literature agree with this finding.¹¹² Authors also report success from using AMT to repair bleb leaks^{113,115} across a range of post operative time points, incorporating both early and late post operative bleb leaks.

Published meta-analysis data¹¹⁶ suggest that that amnion usage intraoperatively was effective at reducing IOP when compared with trabeculectomy alone. Amnion application during trabeculectomy is the most well-documented indication in glaucoma patients, and Sheha et al¹¹⁷ report that amnion combined with mitomycin-c increased the surgical success rate of secondary trabeculectomies in refractory surgical cases (93.7%). The authors describe the technique in their publication, using amnion sutured stromal side down under the trabeculectomy flap. AMT augmented trabeculectomies have been shown to increase success in primary trabeculectomy surgery.¹¹⁷ There are reports to suggest it can be used as a patch graft during drainage device insertion, providing good tectonic support and allowing direct visualisation of the tube,¹¹⁸ despite not improving clinical success.^{119,120} AMT has also been used to repair conjunctival defects causing bleb leaks and hypotony following GDDs and MIGS device insertion.^{121,122}

Neoplasia

Amnion is used to act as a substrate for conjunctival migration and reconstruction following excision of both malignant and benign tumours. Qin et al¹²³ studied 24 eyes with intraepithelial epithelioma in a randomised trial,

assessing whether a concave-convex (sandwich technique) AMT had better post operative outcomes when compared with standard AMT. Epithelialisation rates were similar in each group, although the tumour recurrence rate at one year was significantly lower in the concave-convex AMT treated group ($p < 0.05$).

Similarly, Agraval et al¹²⁴ report improved local surgical outcomes following conjunctival melanoma excision combined with AMT improved conjunctival healing, resulting in minimal symblepharon, granuloma or scar formation. Other authors have also commented that the transparency of amniotic membrane allows for monitoring of tumour recurrence in deeper tissues, and may also provide a superior cosmesis when compared with thicker (for example, buccal) mucous membrane grafts.¹²⁵

Although the anti-neoplastic mechanism of amnion is not well understood,¹⁰ it is attributed to the secretion of anti-angiogenic, pro-apoptotic and immune-modulatory factors.^{11,126,129} Amnion contains interleukins (IL-2, IL-3 and IL-4) and can express cytotoxic cytokines, these are known to enhance the cytotoxicity of natural killer cells, which are able to attack mitotic cancer cells.¹¹

Oculoplastics

As mentioned briefly above, AMT has been suggested as a potential alternative to mucosal membrane transplantation in lid revision, orbital linings or symblepharolysis. Reports exist describing forniceal reconstruction utilising AM,^{130,132} with other authors stating that AM can be a viable alternative to established mucous membrane grafting, causing less patient morbidity, faster recovery times and better prosthesis fitting in anophthalmic-contracted sockets.^{132,134} It can also be particularly useful if a patient has an insufficient amount of mucosal membrane available, producing effective results when combined with antimetabolites such as MMC.¹³⁵

Cicatricial eyelid abnormalities can be difficult to treat as tissue loss needs to be overcome. Good outcomes have been reported using a gray line lid split procedure with vertical anterior lamella repositioning, in patients with moderate to severe cicatricial entropion.¹³⁶ AMT was used to cover the bare tarsus up to the lid margin and secured with 7–0 Vicryl sutures. Good cosmetic outcomes were reported, with rapid epithelialisation of the previously bare tarsus. No lashes were abrading the globe in 88% of cases 12 months post operatively. In addition, it has been used following conjunctival reconstruction in advanced mucous membrane pemphigoid. After scar tissue was carefully excised, AMT was placed over the cornea, bulbar and tarsal conjunctiva, and

secured with 8–0 Vicryl sutures to the conjunctival edges and the deep fornices with double-armed 6–0 silk sutures.¹³⁷ Immunosuppressive systemic therapy and topical steroids were administered to all patients for at least 6 months following surgery. Post operatively the forniceal depth was significantly improved up to 28 weeks following surgery, although the effect was said to deteriorate over time.¹³⁷ Comparable outcomes have been shown in Stevens–Johnson Syndrome patients, using a similar surgical technique.¹³⁸

There are reports of authors using AMT in conjunction with an Hughes procedure to restore tissue loss after excision of conjunctival melanoma involving the fornix. In addition, despite being a rare condition, AMT has been used effectively to manage cases of cryptophthalmos. One centre reports surgical success in terms of both acceptable functional and cosmetic outcomes in 20 of 24 patients receiving repair procedures from a single centre over a 12-year period. The authors conclude that a one-stage reconstruction of both the eyelid and fornix with scleral and amniotic grafts is an effective strategy to correct abortive cryptophthalmos.¹³⁹

Pterygium

The use of AMT in pterygium is one of the most well-documented indications. However, it is also one of the most controversial areas for its usage, with the current treatment standard for pterygium excision being a repair of the defect with a conjunctival autograft. A Cochrane systematic meta-analysis review¹⁴⁰ compared the use of autograft with AMT following pterygium excision. Conjunctival autograft was associated with a lower risk of recurrence at six months' following surgery than AMT. Participants with recurrent pterygia, in particular, were found to have a lower risk of recurrence when they received conjunctival autografts. The obvious advantage AMT has in this setting is no donor site defect is created. There are few studies comparing the two techniques with respect to visual acuity outcomes, and no studies report on vision-related quality of life or direct or indirect costs.¹⁴⁰ Unfortunately, an insufficient number of studies have used adjunctive mitomycin C to be able to draw conclusions on the effects on pterygium recurrence following conjunctival autograft or AMT.

Prajna et al¹⁴¹ studied double pterygium excision (combined nasal and temporal) comparing autograft to AMT. Again, the autograft group was shown to have statistically significant lower recurrence rates than AMT, which has also been reported by other studies.¹⁴²

Strabismus

Cryopreserved AMT has been utilised during strabismus surgery either to cover defects or to reduce muscle fibrosis and adhesion. Kassem et al¹⁴³ reported a randomised controlled study of revisional strabismus patients, where one group received amnion wrapped around the rectus muscle. Although no adverse events were reported from the amnion group, the authors concluded that no clinical benefits were shown from this technique. The patients in the treatment group were followed up on a long-term basis (up to 85 months) in a further study,¹⁴⁴ with the conclusion that the effect of amniotic membrane transplantation on the success of strabismus reoperations was moderate in terms of ocular alignment, but more pronounced in terms of ocular motility range, likely due to a reduction in fibrosis and subsequent muscle restriction.^{143,145}

There are also reports of AMT usage in complex strabismus cases, with successful outcomes in patients that suffer diplopia following vitreoretinal surgery.¹⁴⁶ It has also been used with adjunctive MMC in cases with congenital fibrosis of the extraocular muscles.¹⁴⁷

Fresh human AMT has been used successfully in secondary strabismus cases, where authors report the placement of two AM sheets, one between the operated muscle and tenon's capsule, with the stromal side facing tenon's capsule. The other AMT is placed between the muscle and sclera with the stroma facing the sclera. Areas of bare sclera were covered using AMT with the stroma against the sclera. The authors concluded that AMT placement around the extraocular muscle improved ductions and reduced the residual deviation angle due to less post operative scar formation.¹⁴⁸ This was attributed to the prevention of adhesions by the AMT as it formed a temporary biological barrier between the layers of perimuscular connective tissue. Despite these outcomes, the use of fresh AMT is discouraged due to the risk of communicable diseases, which is significantly reduced in other forms of AMT. Interestingly, dried AMT has resulted in poor outcomes in strabismus cases^{145,149,150} apart from one case report.¹⁵¹

The orientation of AMT varies throughout these studies and conclusions are hard to draw from the outcomes. One histopathological study using rabbits compared three groups; one with stroma orientated towards the muscle, another with the epithelium towards the muscle, and one with folded AM where the epithelium was in contact with muscle and sclera. The authors concluded that any AMT

orientation was effective in preventing adhesions, with no advantage seen in either group.¹⁵² Although there is limited evidence within the literature to support a sutured or sutureless technique, one review article recommends the use of a sutureless technique as it induces less of an inflammatory reaction and results in a shorter operating time.¹⁴⁵

Ocular Surface Wound Healing: Patch Chemical/Thermal Injury

Amnion has a range of biological properties that make it attractive for use in the treatment of chemical burns, such as its epitheliotropic; anti-inflammatory and anti-neovascular effects.¹⁵³ As well as offering increased oxygen permeation and reducing mechanical epithelial trauma from eyelid friction,⁸ as previously discussed, it can reduce pain whilst increasing patient comfort.^{8,154}

As mentioned above, AMT can be utilised in LSCD, which can occur as a sequelae of chemical and thermal injuries. However, AMT has a role to play in the treatment of the acute phase of these injuries. Tandon et al³⁶ presented the first randomised controlled trial, where amnion was transplanted epithelial side down within the first seven days of injury for chemical injuries of Roper Hall grading II–IV.¹⁵⁵ The study recruited 100 patients, split between moderate (grade II–III) and severe (grade IV) burns. AMT significantly increased the rate of epithelial healing in the moderate burns patients ($p = 0.0004$). However, no difference was seen in the secondary long-term outcome measures, such as final visual acuity, symblepharon formation, corneal clarity or neovascularisation. Patients with severe burns showed no improved rate of epithelial healing. In 2012, Clare et al¹⁵⁶ published a meta-analysis, which analysed only the Tandon et al paper as this was the only available randomised control trial. It concluded that the evidence for amnion use in chemical burns is equivocal.

Sharma et al¹⁷ compared three treatment groups: standard care (SC) alone, SC with amniotic membrane transplantation and SC with umbilical cord serum. Both the umbilical cord serum group and amniotic membrane transplantation group promoted epithelisation faster than SC. However, at three months' there was no difference between the three groups in terms of visual outcome, symblepharon formation, tear film status, and lid abnormalities. The AMT and serum group saw a reduction of pain

for patients at day seven of treatment, although the serum group had the largest reduction in pain scores at all measured time-points.

Most recently, Eslani et al¹⁵⁷ enrolled 60 eyes with grade IV Roper Hall chemical injuries. Patients were randomised to receive medical management or AMT in conjunction with medical management. No significant difference was found between the rates of corneal epithelialisation between the two groups ($p=0.610$), with the authors concluding that medical therapy with AMT does not accelerate corneal epithelialisation or improve final visual acuity in patients with severe chemical injuries. Although the authors suggest that in milder cases AMT may be beneficial based on the outcomes of other studies, it may not actually be a necessary treatment. It is suggested that the LSC function may be so poor in these severe injuries that the anti-inflammatory properties of AMT are not able to overcome the extensive damage. Moreover, its anti-angiogenic effect may reduce the effect of the recovering LSCs.

The current data suggests that the success of amnion transplantation in chemical burns is dependent on the severity of the burn, especially when considering the rate of epithelialisation. However, other outcome measures, such as reduction of pain and inflammation, can be improved with amnion usage, with most of the studies indicating the need to apply the AMT within the first week of any injury.

Dry Eye Disease (DED)

The DEWS II report¹⁵⁸ proposes the use of AMT for use in severe dry eye, as a 'step 4' therapeutic intervention. Reports from within the literature suggest that sutureless AMT (PROKERA[®]) can result in a sustained symptomatic improvement for four months in dry eye subjects when worn for approximately five days on average,¹⁵⁹ demonstrating reduced corneal and conjunctival staining and improved visual acuity. Other studies show similar findings.^{160,161} One retrospective review by Macdonald et al¹⁶² applied AMT for 5.4 (± 2.8 days) on average with a sustained reduction in the DED marker (3.25 ± 0.5 to 1.47 ± 0.6) three months post operatively with improvement in both patient reported symptoms and clinical signs. Finally, other authors report how corneal nerve density can be significantly improved following AMT application,¹⁶³ potentially accelerating the recovery of the ocular surface health in patients with DED.

Cicatrising Conjunctivitis – Steven's Johnson Syndrome (SJS), Toxic Epidermal Necrolysis (TEN), Graft versus Host Disease and Pemphigoid

The only published randomised controlled trial examining AMT in SJS patients, comparing medical management and AMT with solely medical management, is by Sharma et al.¹⁵⁴ In terms of outcomes, the AMT groups showed significantly improved visual outcomes, longer tear break up times and improved Schirmer test outcomes. Importantly, no case in the AMT group demonstrated corneal haze, limbal stem cell deficiency, symblepharon, ankyloblepharon, or lid-related complications. Other authors have shown amnion to be safe and effective in paediatric populations with similar conditions.¹⁶⁴

Ma et al¹⁶⁵ published a novel technique for amnion application in SJS and TEN patients, which involved the use of 10cm x 5cm amnion rectangle combined with a custom-made forniceal ring to provide coverage of the full mucosal surface and eyelids. Amnion is placed on the upper eyelid and secured with two nylon sutures, laid across the ocular surface, and the forniceal ring is placed onto the eye. The technique minimises the manipulation of ocular tissues and decreases surgical time.

Following Ma's study, Shanbhag et al¹⁶⁶ published data using cyanoacrylate glue instead of suturing the AMT into position, making it easier to perform at a patient's bedside, providing clinicians with the potential to avoid the risk of visiting theatre with a medically unstable patient.

Recurrent Corneal Erosion (RCE)

RCE has been highlighted as a therapeutic indication in which amniotic membrane could be utilised. In a case series by Huang et al,¹⁶⁷ 11 eyes of 9 patients, each treated with epithelial debridement followed by sutureless AMT. During the follow-up period (average 12 months), only one eye suffered symptoms of recurrent erosions. A comprehensive review by Miller et al¹⁶⁸ in 2019 listed amnion as an effective treatment for acute RCE attacks and suggested its use once conservative treatment of topical lubrication and punctal occlusion has failed, instead of inserting a bandage contact lens.

Vitreoretinal – Amnion Plugs

Following Pars Plana Vitrectomy: Macular Holes and Tears

Amnion plugs can be implanted in the subretinal space with the chorion layer facing the RPE in an attempt to close

macular holes.¹⁶⁹ Evidence suggests that human retinal pigmented epithelial cells seed over amnion within 24 hours of implantation. Moreover, these cells maintain epithelial features and can proliferate over epithelium-free amnion, resulting in a tight monolayer with well-defined intercellular and cell–substrate interactions, secreting several growth factors important for maintaining retinal homeostasis.¹⁷⁰ Recently, Caporossi et al, 2019¹⁶⁹ studied 16 eyes of 16 patients with recurrent macular holes in a prospective case series of highly myopic eyes. All patients underwent a 23-gauge par plana vitrectomy with AMT implantation, with either 20% SF6 or air tamponade. Mean post operative BCVA was 0.94±0.24 logMAR, which improved to 0.67±0.26 logMAR post operatively. All patients experienced complete closure anatomically, although one hole reopened, requiring a repeat amniotic membrane implant two weeks post operatively.

Similarly, Caporossi et al¹⁷¹ presented a case series of two eyes of two patients with retinal detachment and large macular tears. Pars plana vitrectomy was performed in conjunction with an AMT, and standard silicone oil tamponade. For both patients, BCVA improved from light perception to 1.3 logMAR. At three months, both patients' optical coherence tomography showed neuroretinal ingrowth over the amniotic membrane plug.¹⁷¹

The use of amnion in vitreoretinal surgery is a novel and innovative technique that requires greater understanding and research but certainly appears encouraging.

Potential Risks of Amniotic Membrane Transplantation

As amnion is an allogenic tissue from a single donor, there will be an implicit risk of acquiring infectious diseases from its usage. Adequate donor screening, testing, handling, processing and storage, should be employed in order to minimize this risk. Legislation should stipulate that HIV, hepatitis B, C, and HTLV tests are undertaken on the donor serum at the time of membrane procurement, with a repeated HIV test 6 months later to cover the latent infectious period of the virus. In order to safely achieve this, the membrane is quarantined for 6 months. Additionally, as with any human-derived product, the risk of prion infection must also be considered. Very few complications have been reported despite AMT's use in a wide range of clinical applications. Hypopyon formation has been reported in one case following repeated applications to a neurotrophic ulcer.¹⁷² This was resolved with

topical steroid treatment. Haematomas may form post operatively, which may be need to be drained if they cause discomfort or dislodge the transplant. Granulomas can also form around sutured membranes, and dislocated membranes can be frustrating. The authors also report persistent subepithelial membranes that are thought to be from thicker membranes harvested near the umbilical cord. This can reduce the visual potential if they reside on the visual axis.⁸

Conclusion

We have shown the wide-ranging applications of AMT that exist within ophthalmic settings, alongside a discussion of the relevant literature. We hope this review gives the reader greater understanding of the clinical scenarios in which AMT may provide benefit. Given its widespread use, there are likely to be scenarios where usage will be beneficial, but similarly, there will be times when it is not required. Our understanding of AMT is not yet complete, but it is improving. It is clear that AMT is beneficial in some conditions, and, as discussed above, offers a good option in some challenging situations. With time, our understanding will improve, along with clarifying the clinical scenarios for which it is required.

Abbreviations

AM, amniotic membrane; AMT, amniotic membrane transplant; LSC, limbal stem cell; LSCD, limbal stem cell deficiency; SLET, simple limbal epithelial transplantation; CLET, cultivated limbal epithelial transplantation; COMET, cultivated oral mucosal epithelial transplantation; ACER, amnion-assisted conjunctival epithelial redirection; SSCE, sector sequential conjunctival epitheliectomy.

Disclosure

The author reports no conflicts of interest in this work.

References

1. Meller D, Pauklin M, Thomasen H, Westekemper H, Steuhl KP. Amniotic membrane transplantation in the human eye. *Dtsch Arztebl Int.* 2011;108(14):243–248. doi:10.3238/arztebl.2011.0243
2. Tseng SC, Espana EM, Kawakita T, et al. How does amniotic membrane work? *Ocul Surf.* 2004;2(3):177–187.
3. Davis JS II. Skin grafting at the Johns Hopkins hospital. *Ann Surg.* 1909;50(3):542–549. doi:10.1097/00000658-190909000-00002
4. Karnitschnigg H. [Amniotic membrane in surgical therapy of adhesion ileus and adhesion complications]. *Wien Med Wochenschr.* 1950;100(29–30):502–503.
5. Schrimpf WJ. Repair of tympanic membrane perforations with human amniotic membrane; report of fifty-three cases. *Ann Otol Rhinol Laryngol.* 1954;63(1):101–115. doi:10.1177/000348945406300109

6. Ashworth MF, Morton KE, Dewhurst J, Lilford RJ, Bates RG. Vaginoplasty using amnion. *Obstet Gynecol.* 1986;67(3):443–446.
7. Brandt FT, Albuquerque CD, Lorenzato FR. Female urethral reconstruction with amnion grafts. *Int J Surg Investig.* 2000;1(5):409–414.
8. Dua HS, Gomes JA, King AJ, Maharajan VS. The amniotic membrane in ophthalmology. *Surv Ophthalmol.* 2004;49(1):51–77. doi:10.1016/j.survophthal.2003.10.004
9. Tejwani S, Kolari RS, Sangwan VS, Rao GN. Role of amniotic membrane graft for ocular chemical and thermal injuries. *Cornea.* 2007;26(1):21–26.
10. Hossain L, Siddika A, Adnan MH, Diba F, Hasan Z, Asaduzzaman SM. Human Amniotic Membrane and Its Anti-cancer Mechanism: a Good Hope for Cancer Therapy. *SN Compr Clin Med.* 2019;1(7):487–495. doi:10.1007/s42399-019-00090-5
11. Niknejad H, Yazdanpanah G. Anticancer effects of human amniotic membrane and its epithelial cells. *Med Hypotheses.* 2014;82(4):488–489. doi:10.1016/j.mehy.2014.01.034
12. Tseng SC, Li DQ, Ma X. Suppression of transforming growth factor-beta isoforms, TGF-beta receptor type II, and myofibroblast differentiation in cultured human corneal and limbal fibroblasts by amniotic membrane matrix. *J Cell Physiol.* 1999;179(3):325–335. doi:10.1002/(SICI)1097-4652(199906)179:3<325::AID-JCP10>3.0.CO;2-X
13. Hao Y, Ma DH, Hwang DG, Kim WS, Zhang F. Identification of antiangiogenic and antiinflammatory proteins in human amniotic membrane. *Cornea.* 2000;19(3):348–352. doi:10.1097/00003226-200005000-00018
14. Ogawa Y, He H, Mukai S, et al. Heavy Chain-hyaluronan/pentraxin 3 from amniotic membrane suppresses inflammation and scarring in murine lacrimal gland and conjunctiva of chronic graft-versus-host disease. *Sci Rep.* 2017;7(1):42195.
15. Meller D, Pires RT, Mack RJ, et al. Amniotic membrane transplantation for acute chemical or thermal burns. *Ophthalmology.* 2000;107(5):980–989.
16. Tamhane A, Vajpayee RB, Biswas NR, et al. Evaluation of amniotic membrane transplantation as an adjunct to medical therapy as compared with medical therapy alone in acute ocular burns. *Ophthalmology.* 2005;112(11):1963–1969. doi:10.1016/j.ophtha.2005.05.022
17. Sharma N, Singh D, Maharana PK, et al. Comparison of Amniotic Membrane Transplantation and Umbilical Cord Serum in Acute Ocular Chemical Burns: a Randomized Controlled Trial. *Am J Ophthalmol.* 2016;168:157–163. doi:10.1016/j.ajo.2016.05.010
18. Jensen OL, Gluud BS. Bacterial growth in the conjunctival sac and the local defense of the outer eye. *Acta Ophthalmol Suppl.* 1985;173:80–82. doi:10.1111/j.1755-3768.1985.tb06849.x
19. Sotozono C, Inagaki K, Fujita A, et al. Methicillin-resistant Staphylococcus aureus and methicillin-resistant Staphylococcus epidermidis infections in the cornea. *Cornea.* 2002;21(7 Suppl):S94–S101. doi:10.1097/01.icc.0000263127.84015.3f
20. Goodman DF, Gottsch JD. Methicillin-resistant Staphylococcus epidermidis keratitis treated with vancomycin. *Arch Ophthalmol.* 1988;106(11):1570–1571. doi:10.1001/archoph.1988.01060140738046
21. de ROTH A. PLASTIC REPAIR OF CONJUNCTIVAL DEFECTS WITH FETAL MEMBRANES. *Arch Ophthalmol.* 1940;23(3):522–525. doi:10.1001/archoph.1940.00860130586006
22. Rao TV, Chandrasekharam V. Use of Dry Human and Bovine Amnion as a Biological Dressing. *Arch Surg.* 1981;116(7):891–896. doi:10.1001/archsurg.1981.01380190029007
23. McLaren J, Malak TM, Bell SC. Structural characteristics of term human fetal membranes prior to labour: Identification of an area of altered morphology overlying the cervix. *Hum Reprod.* 1999;14(1):237–241. doi:10.1093/humrep/14.1.237
24. McParland P, Bell SC. THE FETAL MEMBRANES AND MECHANISMS UNDERLYING THEIR LABOUR-ASSOCIATED AND PRE-LABOUR RUPTURE DURING PREGNANCY. *Fetal Matern Med Rev.* 2004;15(1):73–108. doi:10.1017/S0965539504001238
25. Karteris E, Grammatopoulos D, Dai Y, et al. The human placenta and fetal membranes express the corticotropin-releasing hormone receptor 1alpha (CRH-1alpha) and the CRH-C variant receptor. *J Clin Endocrinol Metab.* 1998;83(4):1376–1379. doi:10.1210/jcem.83.4.4705
26. Wu ZY, Hui GZ. Materials for neuro-transplantation and the amnion. *Chin Med J (Engl).* 2006;119(16):1323–1326. doi:10.1097/00029330-200608020-00001
27. Tseng SCG, Espana EM, Kawakita T, et al. How Does Amniotic Membrane Work? *Ocul Surf.* 2004;2(3):177–187. doi:10.1016/S1542-0124(12)70059-9
28. Fukuda K, Chikama T, Nakamura M, Nishida T. Differential distribution of subchains of the basement membrane components type iv collagen and laminin among the amniotic membrane, cornea, and Conjunctiva. *Cornea.* 1999;18(1):73–79. doi:10.1097/00003226-199901000-00013
29. Hopkinson A, Shanmuganathan VA, Gray T, et al. Optimization of Amniotic Membrane (AM) Denuding for Tissue Engineering. *Tissue Eng Part C Methods.* 2008;14(4):371–381. doi:10.1089/ten.tec.2008.0315
30. Bourne GL. The microscopic anatomy of the human amnion and chorion. *Am J Obstet Gynecol.* 1960;79(6):1070–1073. doi:10.1016/0002-9378(60)90512-3
31. Danforth D, Hull RW. The microscopic anatomy of the fetal membranes with particular reference to the detailed structure of the amnion. *Am J Obstet Gynecol.* 1958;75(3):536–547. doi:10.1016/0002-9378(58)90610-0
32. Trelford JD, Trelford-Sauder M. The amnion in surgery, past and present. *Am J Obstet Gynecol.* 1979;134(7):833–845. doi:10.1016/0002-9378(79)90957-8
33. Matthews RN, Faulk WP, Bennett JP. A review of the role of amniotic membranes in surgical practice. *Obstet Gynecol Annu.* 1982;11:31–58.
34. van Herendael BJ, Oberti C, Brosens I. Microanatomy of the human amniotic membranes. A light microscopic, transmission, and scanning electron microscopic study. *Am J Obstet Gynecol.* 1978;131(8):872–880. doi:10.1016/S0002-9378(16)33135-0
35. Tabatabaei SA, Soleimani M, Behrouz MJ, Torkashvand A, Anvari P, Yasari M. A randomized clinical trial to evaluate the usefulness of amniotic membrane transplantation in bacterial keratitis healing. *Ocul Surf.* 2017;15(2):218–226. doi:10.1016/j.jtos.2017.01.004
36. Tandon R, Gupta N, Kalaivani M, Sharma N, Titiyal JS, Vajpayee RB. Amniotic membrane transplantation as an adjunct to medical therapy in acute ocular burns. *Br J Ophthalmol.* 2011;95(2):199–204. doi:10.1136/bjo.2009.173716
37. He H, Kuriyan AE, Su CW, et al. Inhibition of proliferation and epithelial mesenchymal transition in retinal pigment epithelial cells by heavy chain-hyaluronan/pentraxin 3. *Sci Rep.* 2017;7(1):43736. doi:10.1038/srep43736
38. Ogawa Y, He H, Mukai S, et al. Heavy chain-hyaluronan/pentraxin 3 from amniotic membrane suppresses inflammation and scarring in murine lacrimal gland and conjunctiva of chronic graft-versus-host disease. *Sci Rep.* 2017;7(1):42195. doi:10.1038/srep42195
39. Shay E, He H, Sakurai S, Tseng SC. Inhibition of angiogenesis by HC.HA, a complex of hyaluronan and the heavy chain of inter-alpha-inhibitor, purified from human amniotic membrane. *Invest Ophthalmol Vis Sci.* 2011;52(5):2669–2678. doi:10.1167/iovs.10-5888

40. Wang J, Chen D, Sullivan DA, Xie H, Li Y, Liu Y. Expression of Lubricin in the Human Amniotic Membrane. *Cornea*. 2020;39(1):118–121. doi:10.1097/ICO.0000000000002151
41. Kjaergaard N, Hein M, Hyttel L, et al. Antibacterial properties of human amnion and chorion in vitro. *Eur J Obstet Gynecol Reprod Biol*. 2001;94(2):224–229. doi:10.1016/S0301-2115(00)00345-6
42. Kjaergaard N, Helmig RB, Schonheyder HC, Ulbjerg N, Hansen ES, Madsen H. Chorioamniotic membranes constitute a competent barrier to group b streptococcus in vitro. *Eur J Obstet Gynecol Reprod Biol*. 1999;83(2):165–169. doi:10.1016/S0301-2115(99)00009-3
43. Gabric N, Mravcic I, Dekaris I, Karaman Z, Mitrovic S. Human amniotic membrane in the reconstruction of the ocular surface. *Doc Ophthalmol*. 1999;98(3):273–283. doi:10.1023/A:1002423621010
44. Sangwan VS, Basu S. Antimicrobial properties of amniotic membrane. *Br J Ophthalmol*. 2011;95(1):1. doi:10.1136/bjo.2010.184259
45. Rinastiti M, Santoso ALS, Sosroseno W. Histological evaluation of rabbit gingival wound healing transplanted with human amniotic membrane. *Int J Oral Maxillofac Surg*. 2006;35(3):247–251. doi:10.1016/j.ijom.2005.09.012
46. Niknejad H, Peirovi H, Jorjani M, Ahmadiani A, Ghanavi J, Seifalian AM. Properties of the amniotic membrane for potential use in tissue engineering. *Eur Cell Mater*. 2008;15:88–99. doi:10.22203/eCM.v015a07
47. Meller D, Pires RT, Tseng SC. Ex vivo preservation and expansion of human limbal epithelial stem cells on amniotic membrane cultures. *Br J Ophthalmol*. 2002;86(4):463–471. doi:10.1136/bjo.86.4.463
48. Meller D, Tseng SC. Conjunctival epithelial cell differentiation on amniotic membrane. *Invest Ophthalmol Vis Sci*. 1999;40(5):878–886.
49. Keene DR, Sakai LY, Lunstrum GP, Morris NP, Burgeson RE. Type VII collagen forms an extended network of anchoring fibrils. *J Cell Biol*. 1987;104(3):611–621. doi:10.1083/jcb.104.3.611
50. Streuli CH, Bailey N, Bissell MJ. Control of mammary epithelial differentiation: basement membrane induces tissue-specific gene expression in the absence of cell-cell interaction and morphological polarity. *J Cell Biol*. 1991;115(5):1383–1395. doi:10.1083/jcb.115.5.1383
51. Kurpakus MA, Stock EL, Jones JC. The role of the basement membrane in differential expression of keratin proteins in epithelial cells. *Dev Biol*. 1992;150(2):243–255. doi:10.1016/0012-1606(92)90239-D
52. Boudreau N, Simpson CJ, Werb Z, Bissell MJ. Suppression of ICE and apoptosis in mammary epithelial cells by extracellular matrix. *Science*. 1995;267(5199):891–893. doi:10.1126/science.7531366
53. Boudreau N, Werb Z, Bissell MJ. Suppression of apoptosis by basement membrane requires three-dimensional tissue organization and withdrawal from the cell cycle. *Proc Natl Acad Sci U S A*. 1996;93(8):3509–3513. doi:10.1073/pnas.93.8.3509
54. Cooke M, Tan EK, Mandrycky C, He H, O'Connell J, Tseng SC. Comparison of cryopreserved amniotic membrane and umbilical cord tissue with dehydrated amniotic membrane/chorion tissue. *J Wound Care*. 2014;23(10):465–74, 476. doi:10.12968/jowc.2014.23.10.465
55. Malhotra C, Jain AK. Human amniotic membrane transplantation: different modalities of its use in ophthalmology. *World J Transplant*. 2014;4(2):111–121. doi:10.5500/wjt.v4.i2.111
56. Allen CL, Clare G, Stewart EA, et al. Augmented dried versus cryopreserved amniotic membrane as an ocular surface dressing. *PLoS One*. 2013;8(10):e78441. doi:10.1371/journal.pone.0078441
57. Rodriguez-Ares MT, Lopez-Valladares MJ, Tourino R, et al. Effects of lyophilization on human amniotic membrane. *Acta Ophthalmol*. 2009;87(4):396–403. doi:10.1111/j.1755-3768.2008.01261.x
58. Nakamura T, Yoshitani M, Rigby H, et al. Sterilized, freeze-dried amniotic membrane: a useful substrate for ocular surface reconstruction. *Invest Ophthalmol Vis Sci*. 2004;45(1):93–99. doi:10.1167/iovs.03-0752
59. Wolkers WF, Tablin F, Crowe JH. From anhydrobiosis to freeze-drying of eukaryotic cells. *Comp Biochem Physiol A Mol Integr Physiol*. 2002;131(3):535–543. doi:10.1016/S1095-6433(01)00505-0
60. Rock T, Bartz-Schmidt KU, Landenberger J, Bramkamp M, Rock D. Amniotic membrane transplantation in reconstructive and regenerative ophthalmology. *Ann Transplant*. 2018;23:160–165. doi:10.12659/AOT.906856
61. Jirsova K, Jones GLA. Amniotic membrane in ophthalmology: properties, preparation, storage and indications for grafting—a review. *Cell Tissue Bank*. 2017;18(2):193–204.
62. Jirsova K, Jones GLA. Amniotic membrane in ophthalmology: properties, preparation, storage and indications for grafting. A review. *Cell Tissue Bank*. 2017;18(2):193–204. doi:10.1007/s10561-017-9618-5
63. Resch MD, Schlotzer-Schrehardt U, Hofmann-Rummelt C, et al. Adhesion structures of amniotic membranes integrated into human corneas. *Invest Ophthalmol Vis Sci*. 2006;47(5):1853–1861. doi:10.1167/iovs.05-0983
64. Schuerch K, Baeriswyl A, Frueh BE, Tappeiner C. Efficacy of Amniotic Membrane Transplantation for the Treatment of Corneal Ulcers. *Cornea*. 2019;39:479.
65. Liu J, Li L, Li X. Effectiveness of Cryopreserved Amniotic Membrane Transplantation in Corneal Ulceration: a Meta-Analysis. *Cornea*. 2019;38(4):454–462. doi:10.1097/ICO.0000000000001866
66. Gicquel JJ, Bejjani RA, Ellies P, Mercie M, Dighiero P. Amniotic membrane transplantation in severe bacterial keratitis. *Cornea*. 2007;26(1):27–33. doi:10.1097/ICO.0b013e31802b28df
67. Abdulhalim BE, Wagih MM, Gad AA, Boghdadi G, Nagy RR. Amniotic membrane graft to conjunctival flap in treatment of non-viral resistant infectious keratitis: a randomised clinical study. *Br J Ophthalmol*. 2015;99(1):59–63. doi:10.1136/bjophthalmol-2014-305224
68. Lee SH, Tseng SC. Amniotic membrane transplantation for persistent epithelial defects with ulceration. *Am J Ophthalmol*. 1997;123(3):303–312.
69. Fuchsluger T, Tuerkeli E, Westekemper H, Esser J, Steuhl KP, Meller D. Rate of epithelialisation and re-operations in corneal ulcers treated with amniotic membrane transplantation combined with botulinum toxin-induced ptosis. *Graefes Arch Clin Exp Ophthalmol*. 2007;245(7):955–964. doi:10.1007/s00417-006-0493-1
70. Khokhar S, Natung T, Sony P, Sharma N, Agarwal N, Vajpayee RB. Amniotic membrane transplantation in refractory neurotrophic corneal ulcers: a randomized, controlled clinical trial. *Cornea*. 2005;24(6):654–660. doi:10.1097/01.icc.0000153102.19776.80
71. Altiparmak UE, Ofu Y, Yildiz EH, et al. Prospective comparison of two suturing techniques of amniotic membrane transplantation for symptomatic bullous keratopathy. *Am J Ophthalmol*. 2009;147(3):442–446.e1. doi:10.1016/j.ajo.2008.08.036
72. Paris Fdos S, Goncalves ED, Campos MS, Sato EH, Dua HS, Gomes JA. Amniotic membrane transplantation versus anterior stromal puncture in bullous keratopathy: a comparative study. *Br J Ophthalmol*. 2013;97(8):980–984. doi:10.1136/bjophthalmol-2013-303081
73. Anderson DF, Prabhawat P, Alfonso E, Tseng SC. Amniotic membrane transplantation after the primary surgical management of band keratopathy. *Cornea*. 2001;20(4):354–361. doi:10.1097/00003226-200105000-00004
74. Seitz B, Das S, Sauer R, Mena D, Hofmann-Rummelt C. Amniotic membrane transplantation for persistent corneal epithelial defects in eyes after penetrating keratoplasty. *Eye (Lond)*. 2009;23(4):840–848. doi:10.1038/eye.2008.140
75. Maharajan VS, Shanmuganathan V, Currie A, Hopkinson A, Powell-Richards A, Dua HS. Amniotic membrane transplantation for ocular surface reconstruction: indications and outcomes. *Clin Exp Ophthalmol*. 2007;35(2):140–147. doi:10.1111/j.1442-9071.2006.01408.x

76. Dua HS. Sequential Sectoral Conjunctival Epitheliectomy (SSCE). In: Holland EJ, Mannis MJ, editors. *Ocular Surface Disease Medical and Surgical Management*. New York: Springer New York; 2002:168–174.
77. Sangwan VS, Basu S, MacNeil S, Balasubramanian D. Simple limbal epithelial transplantation (SLET): a novel surgical technique for the treatment of unilateral limbal stem cell deficiency. *Br J Ophthalmol*. 2012;96(7):931. doi:10.1136/bjophthalmol-2011-301164
78. Shanbhag S, Patel C, Goyal R, Donthineni P, Singh V, Basu S. Simple limbal epithelial transplantation (SLET): review of indications, surgical technique, mechanism, outcomes, limitations, and impact. *Indian J Ophthalmol*. 2019;67(8):1265–1277. doi:10.4103/ijjo.IJO_117_19
79. Borroni D, Wowra B, Romano V, et al. Simple limbal epithelial transplantation: a review on current approach and future directions. *Surv Ophthalmol*. 2018;63(6):869–874. doi:10.1016/j.survophthal.2018.05.003
80. Vazirani J, Ali MH, Sharma N, et al. Autologous simple limbal epithelial transplantation for unilateral limbal stem cell deficiency: multicentre results. *Br J Ophthalmol*. 2016;100(10):1416–1420. doi:10.1136/bjophthalmol-2015-307348
81. Dua HS, Miri A, Elalfy MS, Lencova A, Said DG. Amnion-assisted conjunctival epithelial redirection in limbal stem cell grafting. *Br J Ophthalmol*. 2017;101(7):913–919. doi:10.1136/bjophthalmol-2015-307935
82. Tsai RJ, Li L, Chen J. Reconstruction of damaged corneas by transplantation of autologous limbal epithelial cells(1). *Am J Ophthalmol*. 2000;130(4):543. doi:10.1016/S0002-9394(00)00746-7
83. Nakamura T, Inatomi T, Sotozono C, Amemiya T, Kanamura N, Kinoshita S. Transplantation of cultivated autologous oral mucosal epithelial cells in patients with severe ocular surface disorders. *Br J Ophthalmol*. 2004;88(10):1280–1284.
84. Kethiri AR, Basu S, Shukla S, Sangwan VS, Singh V. Optimizing the role of limbal explant size and source in determining the outcomes of limbal transplantation: an in vitro study. *PLoS One*. 2017;12(9):e0185623. doi:10.1371/journal.pone.0185623
85. Rama P, Matuska S, Paganoni G, Spinelli A, De Luca M, Pellegrini G. Limbal stem-cell therapy and long-term corneal regeneration. *N Engl J Med*. 2010;363(2):147–155.
86. Shortt AJ, Secker GA, Lomas RJ, et al. The effect of amniotic membrane preparation method on its ability to serve as a substrate for the ex-vivo expansion of limbal epithelial cells. *Biomaterials*. 2009;30(6):1056–1065.
87. Li W, Hayashida Y, He H, Kuo CL, Tseng SC. The fate of limbal epithelial progenitor cells during explant culture on intact amniotic membrane. *Invest Ophthalmol Vis Sci*. 2007;48(2):605–613.
88. Le Q, Deng SX. The application of human amniotic membrane in the surgical management of limbal stem cell deficiency. *Ocul Surf*. 2019;17(2):221–229.
89. Grueterich M, Tseng SC. Human limbal progenitor cells expanded on intact amniotic membrane ex vivo. *Arch Ophthalmol*. 2002;120(6):783–790.
90. Harkin DG, Barnard Z, Gillies P, Ainscough SL, Apel AJ. Analysis of p63 and cytokeratin expression in a cultivated limbal autograft used in the treatment of limbal stem cell deficiency. *Br J Ophthalmol*. 2004;88(9):1154–1158.
91. Pathak M, Olstad OK, Drolsum L, et al. The effect of culture medium and carrier on explant culture of human limbal epithelium: a comparison of ultrastructure, keratin profile and gene expression. *Exp Eye Res*. 2016;153:122–132.
92. Sun CC, Su Pang JH, Cheng CY, et al. Interleukin-1 receptor antagonist (IL-1RA) prevents apoptosis in ex vivo expansion of human limbal epithelial cells cultivated on human amniotic membrane. *Stem Cells*. 2006;24(9):2130–2139.
93. Schwab IR, Reyes M, Isseroff RR. Successful transplantation of bioengineered tissue replacements in patients with ocular surface disease(1). *Am J Ophthalmol*. 2000;130(4):543–544.
94. Sangwan VS, Matalia HP, Vemuganti GK, et al. Clinical outcome of autologous cultivated limbal epithelium transplantation. *Indian J Ophthalmol*. 2006;54(1):29–34.
95. Parihar JKS, Parihar AS, Jain VK, Kaushik J, Nath P. Allogenic cultivated limbal stem cell transplantation versus cadaveric keratolimbal allograft in ocular surface disorder: 1-year outcome. *Int Ophthalmol*. 2017;37(6):1323–1331.
96. Shimazaki J, Higa K, Morito F, et al. Factors influencing outcomes in cultivated limbal epithelial transplantation for chronic cicatricial ocular surface disorders. *Am J Ophthalmol*. 2007;143(6):945–953.
97. Zakaria N, Possemiers T, Dhuhghaill SN, et al. Results of a Phase I/II clinical trial: standardized, non-xenogenic, cultivated limbal stem cell transplantation. *J Transl Med*. 2014;12:58.
98. Sangwan VS, Basu S, Vemuganti GK, et al. Clinical outcomes of xeno-free autologous cultivated limbal epithelial transplantation: a 10-year study. *Br J Ophthalmol*. 2011;95(11):1525–1529.
99. Basu S, Ali H, Sangwan VS. Clinical outcomes of repeat autologous cultivated limbal epithelial transplantation for ocular surface burns. *Am J Ophthalmol*. 2012;153(4):643–650.
100. Basu S, Fernandez MM, Das S, Gaddipati S, Vemuganti GK, Sangwan VS. Clinical outcomes of xeno-free allogeneic cultivated limbal epithelial transplantation for bilateral limbal stem cell deficiency. *Br J Ophthalmol*. 2012;96(12):1504–1509. doi:10.1136/bjophthalmol-2012-301869
101. Pauklin M, Fuchsluger TA, Westekemper H, Steuhl KP, Meller D. Midterm results of cultivated autologous and allogeneic limbal epithelial transplantation in limbal stem cell deficiency. *Dev Ophthalmol*. 2010;45:57–70.
102. Dobrowolski D, Orzechowska-Wylegala B, Wowra B, et al. Cultivated oral mucosa epithelium in ocular surface reconstruction in aniridia patients. *Biomed Res Int*. 2015;2015:281870. doi:10.1155/2015/281870
103. Nakamura T, Takeda K, Inatomi T, Sotozono C, Kinoshita S. Long-term results of autologous cultivated oral mucosal epithelial transplantation in the scar phase of severe ocular surface disorders. *Br J Ophthalmol*. 2011;95(7):942–946. doi:10.1136/bjo.2010.188714
104. Prabhawati P, Ekpo P, Uiprasertkul M, et al. Long-term result of autologous cultivated oral mucosal epithelial transplantation for severe ocular surface disease. *Cell Tissue Bank*. 2016;17(3):491–503. doi:10.1007/s10561-016-9575-4
105. Satake Y, Higa K, Tsubota K, Shimazaki J. Long-term outcome of cultivated oral mucosal epithelial sheet transplantation in treatment of total limbal stem cell deficiency. *Ophthalmology*. 2011;118(8):1524–1530. doi:10.1016/j.ophtha.2011.01.039
106. Kim YJ, Lee HJ, Ryu JS, et al. Prospective clinical trial of corneal reconstruction with biomaterial-free cultured oral mucosal epithelial cell sheets. *Cornea*. 2018;37(1):76–83. doi:10.1097/ICO.0000000000001409
107. Hirayama M, Satake Y, Higa K, Yamaguchi T, Shimazaki J. Transplantation of cultivated oral mucosal epithelium prepared in fibrin-coated culture dishes. *Invest Ophthalmol Vis Sci*. 2012;53(3):1602–1609. doi:10.1167/iovs.11-7847
108. Inatomi T, Nakamura T, Kojo M, Koizumi N, Sotozono C, Kinoshita S. Ocular surface reconstruction with combination of cultivated autologous oral mucosal epithelial transplantation and penetrating keratoplasty. *Am J Ophthalmol*. 2006;142(5):757–764. doi:10.1016/j.ajo.2006.06.004
109. Madhira SL, Vemuganti G, Bhaduri A, Gaddipati S, Sangwan VS, Ghanekar Y. Culture and characterization of oral mucosal epithelial cells on human amniotic membrane for ocular surface reconstruction. *Mol Vis*. 2008;14:189–196.
110. Bochmann F, Azuara-Blanco A. Interventions for late trabeculectomy bleb leak. *Cochrane Database Syst Rev*. 2012;9:CD006769.

111. Budenz DL, Barton K, Tseng SC. Amniotic membrane transplantation for repair of leaking glaucoma filtering blebs. *Am J Ophthalmol.* 2000;130(5):580–588. doi:10.1016/S0002-9394(00)00600-0
112. Kiuchi Y, Yanagi M, Nakamura T. Efficacy of amniotic membrane-assisted bleb revision for elevated intraocular pressure after filtering surgery. *Clin Ophthalmol.* 2010;4:839–843. doi:10.2147/OPHTH.S12311
113. Sethi P, Patel RN, Goldhardt R, Ayyala RS. Conjunctival advancement with subconjunctival amniotic membrane draping technique for leaking cystic blebs. *J Glaucoma.* 2016;25(2):188–192. doi:10.1097/IJG.0000000000000098
114. Kitagawa K, Yanagisawa S, Watanabe K, et al. A hyperdry amniotic membrane patch using a tissue adhesive for corneal perforations and bleb leaks. *Am J Ophthalmol.* 2009;148(3):383–389. doi:10.1016/j.ajo.2009.03.030
115. Nagai-Kusuhara A, Nakamura M, Fujioka M, Negi A. Long-term results of amniotic membrane transplantation-assisted bleb revision for leaking blebs. *Graefes Arch Clin Exp Ophthalmol.* 2008;246(4):567–571. doi:10.1007/s00417-007-0727-x
116. Wang X, Khan R, Coleman A. Device-modified trabeculectomy for glaucoma. *Cochrane Database Syst Rev.* 2015;12:CD010472.
117. Sheha H, Kheirkhah A, Taha H. Amniotic membrane transplantation in trabeculectomy with mitomycin C for refractory glaucoma. *J Glaucoma.* 2008;17(4):303–307. doi:10.1097/IJG.0b013e31815c3a47
118. Anand A, Sheha H, Teng CC, Liebmann JM, Ritch R, Tello C. Use of amniotic membrane graft in glaucoma shunt surgery. *Ophthalmic Surg Lasers Imaging.* 2011;42(3):184–189. doi:10.3928/15428877-20110426-01
119. Yazdani S, Mahboobipour H, Pakravan M, Doozandeh A, Ghahari E. Adjunctive mitomycin c or amniotic membrane transplantation for ahmed glaucoma valve implantation: a randomized clinical trial. *J Glaucoma.* 2016;25(5):415–421. doi:10.1097/IJG.0000000000000256
120. Eliezer RN, Kasahara N, Caixeta-Umbelino C, Pinheiro RK, Mandia C Jr, Malta RF. Use of amniotic membrane in trabeculectomy for the treatment of glaucoma: a pilot study. *Arq Bras Oftalmol.* 2006;69(3):309–312. doi:10.1590/S0004-27492006000300005
121. Fea A, Cannizzo PM, Consolandi G, Lavia CA, Pignata G, Grignolo FM. Managing drawbacks in unconventional successful glaucoma surgery: a case report of stent exposure. *Case Rep Ophthalmol Med.* 2015;2015:847439.
122. Arnould L, Theillac V, Moran S, Gatinel D, Grise-Dulac A. Recurrent Exposure of XEN Gel Stent Implant and Conjunctival Erosion. *J Glaucoma.* 2019;28(3):e37–e40. doi:10.1097/IJG.0000000000001146
123. Qin H. Excision combined with concavity-convex amniotic membrane transplantation in the treatment of intraepithelial epithelioma. *Int J Ophthalmol.* 2017;17:404–408.
124. Agraval U, Rundle P, Rennie IG, Salvi S. Fresh frozen amniotic membrane for conjunctival reconstruction after excision of neoplastic and presumed neoplastic conjunctival lesions. *Eye (Lond).* 2017;31(6):884–889. doi:10.1038/eye.2016.322
125. Paridaens D, Beekhuis H, van Den Bosch W, Remeyer L, Melles G. Amniotic membrane transplantation in the management of conjunctival malignant melanoma and primary acquired melanosis with atypia. *Br J Ophthalmol.* 2001;85(6):658–661. doi:10.1136/bjo.85.6.658
126. Niknejad H, Yazdanpanah G, Ahmadiani A. Induction of apoptosis, stimulation of cell-cycle arrest and inhibition of angiogenesis make human amnion-derived cells promising sources for cell therapy of cancer. *Cell Tissue Res.* 2016;363(3):599–608. doi:10.1007/s00441-016-2364-3
127. Niknejad H, Khayat-Khoei M, Peirovi H, Abolghasemi H. Human amniotic epithelial cells induce apoptosis of cancer cells: a new anti-tumor therapeutic strategy. *Cytotherapy.* 2014;16(1):33–40. doi:10.1016/j.jcyt.2013.07.005
128. Niknejad H, Yazdanpanah G, Mirmasoumi M, Abolghasemi H, Peirovi H, Ahmadiani A. Inhibition of HSP90 could be possible mechanism for anti-cancer property of amniotic membrane. *Med Hypotheses.* 2013;81(5):862–865. doi:10.1016/j.mehy.2013.08.018
129. Kamiya K, Wang M, Uchida S, et al. Topical application of culture supernatant from human amniotic epithelial cells suppresses inflammatory reactions in cornea. *Exp Eye Res.* 2005;80(5):671–679. doi:10.1016/j.exer.2004.11.018
130. Oliphant H, Rajak SN. Dried amniotic membrane in fornix reconstruction. *Clin Exp Ophthalmol.* 2019;47(8):1090–1091. doi:10.1111/ceo.13566
131. Kheirkhah A, Ghaffari R, Kaghazkanani R, Hashemi H, Behrouz MJ, Raju VK. A combined approach of amniotic membrane and oral mucosa transplantation for fornix reconstruction in severe symblepharon. *Cornea.* 2013;32(2):155–160. doi:10.1097/ICO.0b013e318247983d
132. Thatte S, Jain J. Fornix reconstruction with amniotic membrane transplantation: a cosmetic remedy for blind patients. *J Ophthalmic Vis Res.* 2016;11(2):193–197. doi:10.4103/2008-322X.183916
133. Kumar S, Sugandhi P, Arora R, Pandey PK. Amniotic membrane transplantation versus mucous membrane grafting in anophthalmic contracted socket. *Orbit.* 2006;25(3):195–203. doi:10.1080/01676830600575527
134. Bajaj MS, Pushker N, Singh KK, Chandra M, Ghose S. Evaluation of amniotic membrane grafting in the reconstruction of contracted socket. *Ophthalmic Plast Reconstr Surg.* 2006;22(2):116–120. doi:10.1097/01.iop.0000200887.26015.d4
135. Tseng SC, Di Pascuale MA, Liu DT, Gao YY, Baradaran-Rafii A. Intraoperative mitomycin C and amniotic membrane transplantation for fornix reconstruction in severe cicatricial ocular surface diseases. *Ophthalmology.* 2005;112(5):896–903. doi:10.1016/j.ophtha.2004.11.041
136. Ti SE, Tow SL, Chee SP. Amniotic membrane transplantation in entropion surgery. *Ophthalmology.* 2001;108(7):1209–1217. doi:10.1016/S0161-6420(01)00599-1
137. Barabino S, Rolando M, Bentivoglio G, et al. Role of amniotic membrane transplantation for conjunctival reconstruction in ocular-cicatricial pemphigoid. *Ophthalmology.* 2003;110(3):474–480. doi:10.1016/S0161-6420(02)01892-4
138. Honavar SG, Bansal AK, Sangwan VS, Rao GN. Amniotic membrane transplantation for ocular surface reconstruction in Stevens-Johnson syndrome. *Ophthalmology.* 2000;107(5):975–979. doi:10.1016/S0161-6420(00)00026-9
139. Ding J, Hou Z, Li Y, Lu N, Li D. Eyelid and fornix reconstruction in abortive cryptophthalmos: a single-center experience over 12 years. *Eye (Lond).* 2017;31(11):1576–1581. doi:10.1038/eye.2017.94
140. Clearfield E, Muthappan V, Wang X, Kuo IC, Johnston V. Conjunctival autograft for pterygium. *Cochrane Database Syst Rev.* 2016;2:CD011349. doi:10.1002/14651858.CD004158.pub3
141. Prajna NV, Devi L, Seeniraj SK, Keenan JD. Conjunctival autograft versus amniotic membrane transplantation after double pterygium excision: a randomized trial. *Cornea.* 2016;35(6):823–826. doi:10.1097/ICO.0000000000000812
142. Akbari M, Soltani-Moghadam R, Elmi R, Kazemnejad E. Comparison of free conjunctival autograft versus amniotic membrane transplantation for pterygium surgery. *J Curr Ophthalmol.* 2017;29(4):282–286. doi:10.1016/j.joco.2017.08.003
143. Kassem RR, Kamal AM, El-Mofty RMA, Elhilali HM. A controlled study of the role of cryopreserved amniotic membrane transplant during strabismus reoperations. *J AAPOS.* 2017;21(2):97–102 e1. doi:10.1016/j.jaapos.2017.03.002
144. Kassem RR, Kamal AM, El-Mofty RMA, Elhilali HM. Long-term follow-up of cryopreserved amniotic membrane transplant during strabismus reoperations: up 85 months' follow-up. *Eur J Ophthalmol.* 2018;28(4):365–371. doi:10.1177/1120672118757432

145. Kassem RR, El-Mofty RMA. Amniotic Membrane Transplantation in Strabismus Surgery. *Curr Eye Res.* 2019;44(5):451–464. doi:10.1080/02713683.2018.1562555
146. Yamada M, Shinoda K, Hatakeyama A, Nishina S, Mashima Y. Fat adherence syndrome after retinal surgery treated with amniotic membrane transplantation. *Am J Ophthalmol.* 2001;132(2):280–282. doi:10.1016/S0002-9394(01)00930-8
147. Kersey JP, Vivian AJ. Mitomycin and amniotic membrane: a new method of reducing adhesions and fibrosis in strabismus surgery. *Strabismus.* 2008;16(3):116–118. doi:10.1080/09273970802405493
148. Tugcu B, Helvacioğlu F, Yuzbasioglu E, Gurez C, Yigit U. Amniotic membrane in the management of strabismus reoperations. *Jpn J Ophthalmol.* 2013;57(2):239–244. doi:10.1007/s10384-012-0217-5
149. Kassem RR, Abdel-Hamid MA, Khodeir MM. Effect of lyophilized amniotic membrane on the development of adhesions and fibrosis after extraocular muscle surgery in rabbits. *Curr Eye Res.* 2011;36(11):1020–1027. doi:10.3109/02713683.2011.601842
150. Chun BY, Kim HK, Shin JP. Dried human amniotic membrane does not alleviate inflammation and fibrosis in experimental strabismus surgery. *J Ophthalmol.* 2013;2013:369126. doi:10.1155/2013/369126
151. Mehendale RA, Dagi LR. Amniotic membrane implantation to reduce extraocular muscle adhesions to a titanium implant. *J AAPOS.* 2011;15(4):404–406. doi:10.1016/j.jaaapos.2011.05.001
152. Kassem RR, El-Mofty RMA, Khodeir MM, Hamza WM. A comparative study of different amniotic membrane orientations during extraocular muscle surgery in rabbits. *Curr Eye Res.* 2018;43(3):325–332. doi:10.1080/02713683.2017.1401645
153. Meller D, Pires RTF, Mack RJS, et al. Amniotic membrane transplantation for acute chemical or thermal burns. *Ophthalmology.* 2000;107(5):980–989. doi:10.1016/S0161-6420(00)00024-5
154. Sharma N, Thenarasun SA, Kaur M, et al. Adjuvant Role of amniotic membrane transplantation in acute ocular Stevens-Johnson syndrome: a randomized control trial. *Ophthalmology.* 2016;123(3):484–491. doi:10.1016/j.ophtha.2015.10.027
155. Roper-Hall MJ. Thermal and chemical burns. *Trans Ophthalmol Soc U K.* 1965;85:631–653.
156. Clare G, Suleman H, Bunce C, Dua H. Amniotic membrane transplantation for acute ocular burns. *Cochrane Database Syst Rev.* 2012;9.
157. Eslani M, Baradaran-Rafii A, Cheung AY, et al. Amniotic membrane transplantation in acute severe ocular chemical injury: a randomized clinical trial. *Am J Ophthalmol.* 2019;199:209–215. doi:10.1016/j.ajo.2018.11.001
158. Craig JP, Nelson JD, Azar DT, et al. TFOS DEWS II Report Executive Summary. *Ocul Surf.* 2017;15(4):802–812. doi:10.1016/j.jtos.2017.08.003
159. Cheng AM, Zhao D, Chen R, et al. Accelerated restoration of ocular surface health in dry eye disease by self-retained cryopreserved amniotic membrane. *Ocul Surf.* 2016;14(1):56–63. doi:10.1016/j.jtos.2015.07.003
160. Suri K, Kosker M, Raber IM, et al. Sutureless amniotic membrane ProKera for ocular surface disorders: short-term results. *Eye Contact Lens.* 2013;39(5):341–347. doi:10.1097/ICL.0b013e3182a2f8fa
161. Kolomeyer AM, Do BK, Tu Y, Chu DS. Placement of ProKera in the management of ocular manifestations of acute Stevens-Johnson syndrome in an outpatient. *Eye Contact Lens.* 2013;39(3):e7–e11. doi:10.1097/ICL.0b013e318255124f
162. McDonald MB, Sheha H, Tighe S, et al. Treatment outcomes in the DRy Eye Amniotic Membrane (DREAM) study. *Clin Ophthalmol.* 2018;12:677–681. doi:10.2147/OPHTH.S162203
163. John T, Tighe S, Sheha H, et al. Corneal Nerve Regeneration after Self-Retained Cryopreserved Amniotic Membrane in Dry Eye Disease. *J Ophthalmol.* 2017;2017:6404918. doi:10.1155/2017/6404918
164. Wildes MT, Cherof AM, Cerda AM, Lynch AM, Wagner BD, Gregory DG. Outcomes of amniotic membrane transplantation for treatment of Stevens-Johnson syndrome in the pediatric population: a retrospective review. *J Am Assoc Pediatr Ophthalmol Strabismus.* 2016;20(4):e24–e25. doi:10.1016/j.jaaapos.2016.07.093
165. Ma KN, Thanos A, Chodosh J, Shah AS, Mantagos IS. A Novel technique for amniotic membrane transplantation in patients with acute Stevens-Johnson syndrome. *Ocul Surf.* 2016;14(1):31–36. doi:10.1016/j.jtos.2015.07.002
166. Shanbhag SS, Chodosh J, Saeed HN. Sutureless amniotic membrane transplantation with cyanoacrylate glue for acute Stevens-Johnson syndrome/toxic epidermal necrolysis. *Ocul Surf.* 2019;17(3):560–564. doi:10.1016/j.jtos.2019.03.001
167. Huang Y, Tseng SH. SCG, Self-retained amniotic membrane for recurrent corneal erosion. *J Clin Exp Ophthalmol.* 2013;4:272.
168. Miller DD, Hasan SA, Simmons NL, Stewart MW. Recurrent corneal erosion: a comprehensive review. *Clin Ophthalmol.* 2019;13:325–335. doi:10.2147/OPHTH.S157430
169. Caporossi T, Pacini B, De Angelis L, Barca F, Peiretti E, Rizzo S. Human amniotic membrane to close recurrent, high myopic macular holes in pathologic myopia with axial length OF \geq 30 mm. *Retina.* 2019; Publish Ahead of Print. doi:10.1097/IAE.0000000002699
170. Ohno-Matsui K, Ichinose S, Nakahama K, et al. The effects of amniotic membrane on retinal pigment epithelial cell differentiation. *Mol Vis.* 2005;11:1–10.
171. Caporossi T, Tartaro R, De Angelis L, Pacini B, Rizzo S. A human amniotic membrane plug to repair retinal detachment associated with large macular tear. *Acta Ophthalmol.* 2019;97(8):821–823. doi:10.1111/aos.14109
172. Gabler B, Lohmann CP. Hypopyon after repeated transplantation of human amniotic membrane onto the corneal surface. *Ophthalmology.* 2000;107(7):1344–1346. doi:10.1016/S0161-6420(00)00167-6

Clinical Ophthalmology

Publish your work in this journal

Clinical Ophthalmology is an international, peer-reviewed journal covering all subspecialties within ophthalmology. Key topics include: Optometry; Visual science; Pharmacology and drug therapy in eye diseases; Basic Sciences; Primary and Secondary eye care; Patient Safety and Quality of Care Improvements. This journal is indexed on PubMed

Submit your manuscript here: <https://www.dovepress.com/clinical-ophthalmology-journal>

Dovepress

Central and CAS, and is the official journal of The Society of Clinical Ophthalmology (SCO). The manuscript management system is completely online and includes a very quick and fair peer-review system, which is all easy to use. Visit <http://www.dovepress.com/testimonials.php> to read real quotes from published authors.