

Pseudomembranous Colitis in Four Ethiopian Patients: A Case Series

This article was published in the following Dove Press journal:
International Medical Case Reports Journal

Yohannes Birhanu 
Wondwossen Amogne
Abdulsemed Mohammed
Mesfin Asefa
Fithanegest Teferra
Muhaba Yasin

¹College of Health Sciences, Addis Ababa University, Addis Ababa, Ethiopia; ²St. Paul's Hospital, Millennium Medical College, Addis Ababa, Ethiopia; ³Girum General Hospital, Addis Ababa, Ethiopia

Abstract: We present a series of four patients who had been admitted to two hospitals in Addis Ababa after presenting with persistent and chronic diarrhoea. All patients were subsequently diagnosed to have *Clostridioides difficile*-associated pseudomembranous colitis, a disease that has long been regarded as a rare diagnosis in sub-Saharan Africa, and which has not yet been reported in Ethiopia. This case series is believed to create a much-needed awareness among physicians on the existence of this treatable but potentially fatal disease.

Keywords: *Clostridioides difficile*, pseudomembranous colitis

Introduction

Clostridioides difficile infection (CDI) is a disease mainly associated with the use of antibiotics.¹ Not all patients develop symptoms after colonization, but in those with symptoms, the disease can vary from mild diarrhoea to life-threatening colitis. Rare manifestations of CDI like bacteraemia and peritonitis have also been reported.^{2,3} Colonization of the intestinal tract follows exposure through feco-oral route and disease develops from the subsequent alteration of the normal intestinal flora.

According to the Centre for Disease Control and Prevention (CDC), *C. difficile* infection is among the top public health threats associated with the use of antimicrobial agents.⁴ In the United States (US) alone, CDI resulted in 500,000 infections and 29,000 deaths in 2011.¹ The annual health care-associated cost of CDI in the US is reported to be over \$4 billion.⁵

Recent observations have shown an increase in the incidence of community-acquired CDI resulting in disease in patients who were in the past thought to be at low risk.⁶

Antibiotic use is the most common risk factor for CDI. Other factors associated with increased risk of the disease include recent hospitalization, old age, gastric acid suppression, gastrointestinal surgery, chemotherapy and hematopoietic stem cell transplantation.^{7,8}

The diagnosis of CDI depends on clinical and laboratory findings. Infectious Diseases Society of America (IDSA) guidelines recommend making the diagnosis of CDI when the following criteria are met:

1. symptoms of diarrhoea, defined as 3 or more loose stools in 24 hours and
2. a stool test positive for *C. difficile* or its toxins, or colonoscopy or pathology findings consistent with pseudomembranous colitis.^{9,10}

Correspondence: Yohannes Birhanu
Email yohannesbrhn@gmail.com

Management of CDI includes; prompt discontinuation of offending drugs, supportive care and use of antibiotics including metronidazole and oral vancomycin.¹¹

Case 1

A 67-year-old male patient from Dire Dawa, who gave a history of repeated intake of different oral antibiotics (ciprofloxacin, trimethoprim–sulfamethoxazole and tinidazole) for a presumed gastrointestinal and urinary tract infections (UTI) in the prior 3 months, presented with diarrhoea, abdominal pain and fever of 4 weeks duration.

The patient was febrile and tachycardic on presentation and investigations revealed a white cell count of 36,000 cells/mm³ (N= 95%) with a Hgb of 8.9 gm/dl. BUN was 74.58 mg/dl and his creatinine was 4.8 mg/dl. Limited colonoscopy revealed extensive mucosal oedema and erythema with pseudomembranes in the rectum and sigmoid colon suggesting possible *Clostridioides difficile*-associated pseudomembranous colitis (Figure 1).

The colonic biopsy subsequently revealed chronic active colitis most likely pseudomembranous colitis and stool *Clostridioides difficile* DNA real-time PCR turned out to be positive.

With the above evidences, the patient was started on oral vancomycin, IV metronidazole and supportive care and he demonstrated marked improvement with the disappearance of fever and diarrhoea. He was subsequently discharged from hospital after 1 week of stay.

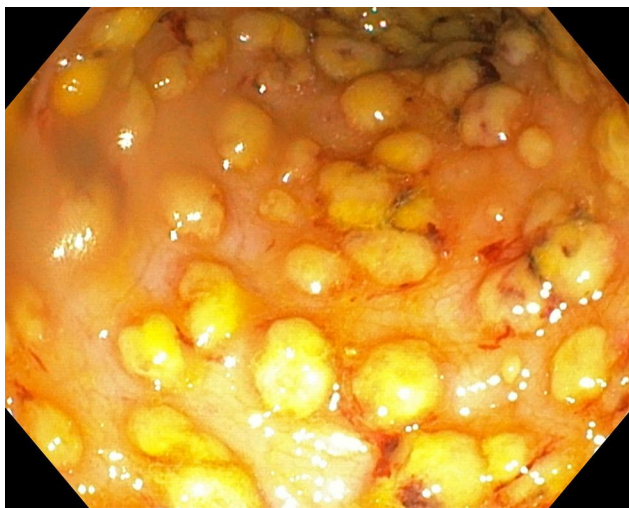

Figure 1 Colonoscopy picture (sigmoid colon) from case No. 1.

Case 2

A 70-year-old male patient with longstanding Type 2 diabetes mellitus (DM), hypertension, and end-stage renal disease, who was on oral cefuroxime and norfloxacin for 5 days for a presumed UTI, presented with fever and diarrhoea of 3 weeks duration. The patient was seen at a local clinic for the diarrhoea and after stool examination, he was put on IV ceftriaxone for five more days. But his symptoms persisted despite the change in antibiotics.

His physical examination was remarkable for tachycardia and lower abdominal tenderness. Investigations revealed neutrophil predominant leucocytosis and many PMN cells with few RBCs were seen on stool microscopy. An abdominal ultrasound showed left-sided colonic wall thickening and subsequent sigmoidoscopy revealed diffuse mucosal erythema with numerous patchy exudates suggestive of pseudomembranes (Figures 2 and 3).

Biopsy from the colon revealed mucosal tissue fragments that had explosive necro-inflammatory pseudomembranous exudate on the surface of ulcerated mucosal fragments. Variably dilated crypts partly filled with mucus and neutrophils, with superficial epithelial loss and variably expanded lamina propria were also seen (Figure 4).

Stool *C. difficile* toxin assay was planned but the patient could not afford the test. So, with a presumptive diagnosis of pseudomembranous colitis, he was put on oral vancomycin and he was discharged from hospital after 7 days of treatment with complete resolution of the diarrhoea.

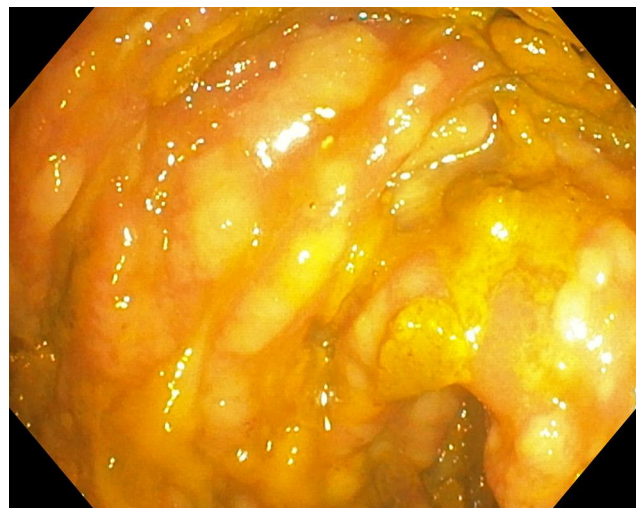


Figure 2 Colonoscopy images from case no. 2.

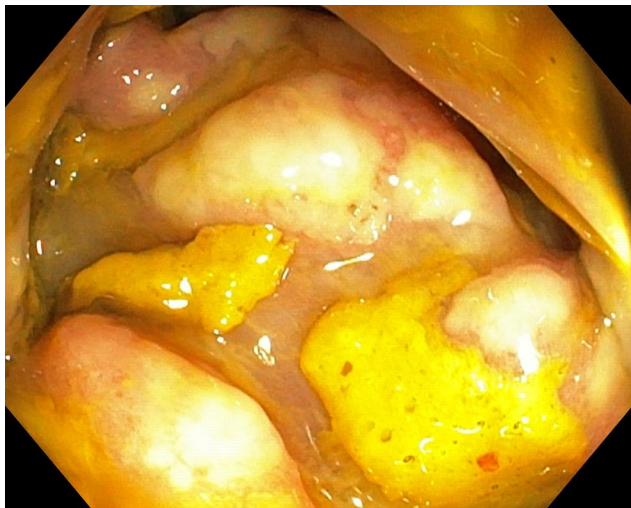

Figure 3 Additional Colonoscopy images from case no. 2.

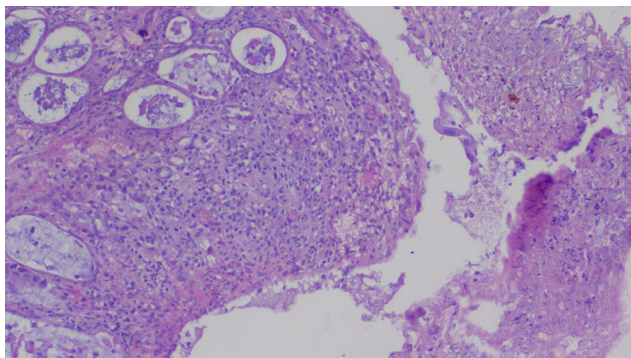


Figure 4 Mucosal histopathology pictures from case No. 2.

Case 3

A 73-year-old male who had prostatectomy 7 weeks back and who was on ceftriaxone IV post-operatively developed frequent watery diarrhoea on the 6th post-operative day, which persisted for 6 weeks. Physical examination revealed an acutely sick patient with a fever of 38°C and the patient had a protuberant abdomen with mild generalized abdominal tenderness.

Investigation showed a WBC count of 26,800 cells/mm³ (neutrophils 83%), with normal Hgb and organ function tests. Given the abdominal tenderness, peritonitis was suspected. Abdominal CT subsequently revealed colonic and rectal wall thickening with minimal peritoneal fluid collection. So, urgent colonoscopy was performed and it revealed extensive mucosal oedema and erythema with overlying patchy exudates in the rectum and sigmoid, consistent with pseudomembranous colitis (Figure 5).

Colonic mucosal biopsy revealed mucosal fragments with expanded lamina propria and marked lympho-poly-morphonuclear infiltrates associated with variably dilated crypts filled with mucus and neutrophils. In addition, surface ulceration with necro-inflammatory pseudomembranous exudate mixed with mucus was seen and these histopathological findings were suggestive of pseudomembranous colitis (Figures 6 and 7).

Given the patients' financial constraints, stool CDI toxin assay could not be performed. So, he was admitted and started on oral vancomycin, IV metronidazole and supportive care. He showed marked improvement and he was discharged from hospital after 8 days of stay.

Case 4

A 25-year-old male patient with acute myeloid leukaemia (AML), who recently completed chemotherapy and who was on cefepime, meropenem and ciprofloxacin for neu-

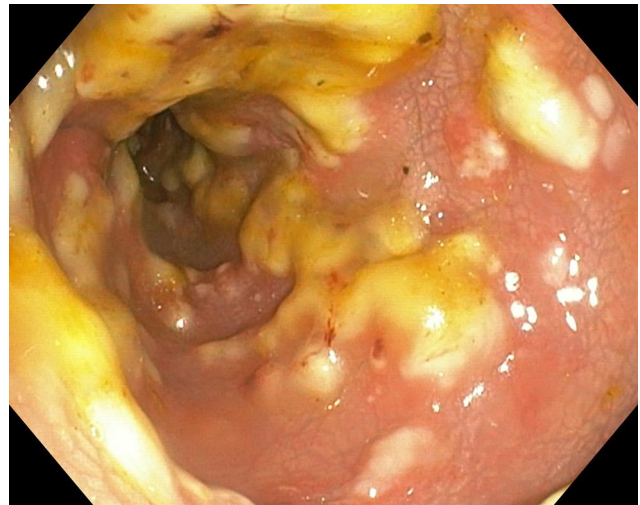


Figure 5 Colonoscopy image of case No. 3.

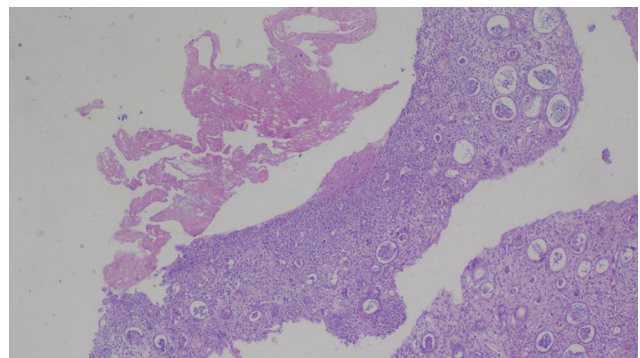


Figure 6 Mucosal histopathology pictures from case no. 3.

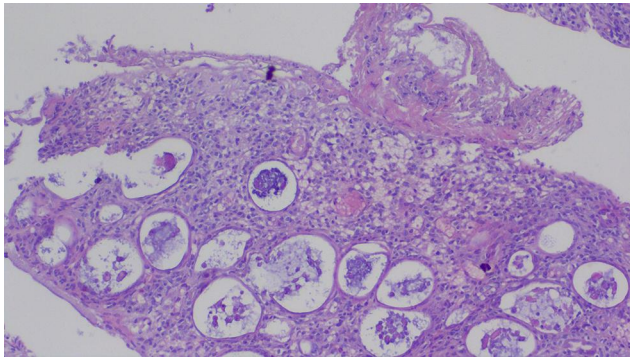


Figure 7 Additional histopathology pictures from case no. 3.

tropenic fever, developed non-bloody diarrhoea, fever and abdominal pain of 15 days duration.

Physical examination was remarkable for fever of 38–39°C, tachycardia, and lower abdominal tenderness.

Investigation revealed WBC count of 400 cells/mm³ with an absolute neutrophil count being 60 cells/mm³, a haemoglobin of 9 g/dl, and a platelet count of 14,000/microliter.

Stool microscopy showed many PMN cells but the patient's renal and liver function tests were normal.

Abdominal CT scan showed diffuse large bowel wall thickening suggesting possible infectious pan-colitis (Figure 8). Subsequent sigmoidoscopy revealed diffuse mucosal erythema with pseudomembranes (Figure 9).

Determining stool *Clostridioides difficile* toxin assay was not possible due to financial reasons. So, the patient was given oral vancomycin and his symptoms completely subsided.

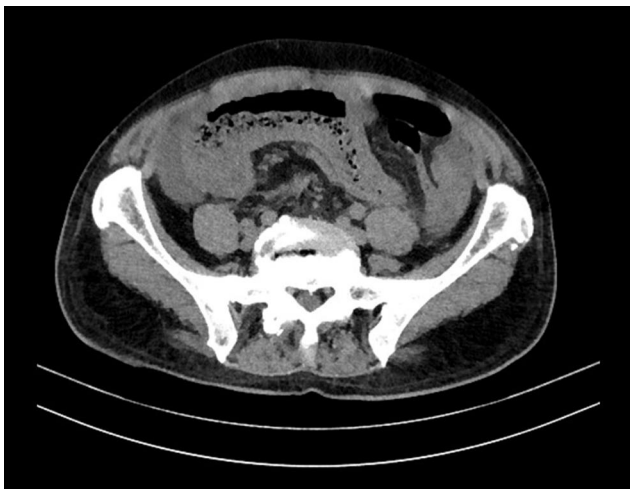

Figure 8 Abdominal CT of case no. 4.

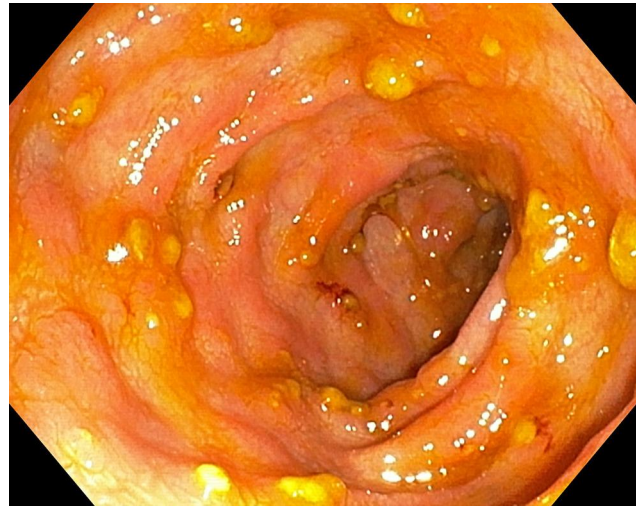


Figure 9 Colonoscopy pictures from case no. 4.

Discussion

The clinical cases presented above demonstrate that CDI can affect a variety of patient populations with different comorbidities (Table 1). Although most of the patients in this series were aged 67 years and above, younger patients can also be affected by the disease (as was the case in the last patient). In addition to age, the presence of comorbidities like end-stage kidney disease, diabetes, hematologic malignancy and chemotherapy may have contributed to the risk of developing CDI.^{7,8}

Antibiotic exposure is a major risk factor for the development of pseudomembranous colitis and numerous groups of antibiotics including cephalosporins, penicillin, fluoroquinolones, clindamycin, macrolides, folic acid inhibitors and tetracyclines have been implicated in the development of CDI.⁴

The above described four patients have been exposed to multiple antibiotics including ceftriaxone, cefuroxime, ciprofloxacin, norfloxacin, co-trimoxazole, carbapenems and tinidazole and most of them actually took multiple antibiotics which were prescribed empirically. Lack of proper microbiology laboratory facility often results in uncertain etiologic diagnosis of infectious diseases, thereby resulting in empiric therapy using multiple antibiotics, which increases the risk of developing pseudomembranous colitis.

Although there are many epidemiologic studies in Europe, America and Asia, the prevalence of CDI in Sub-Saharan African countries is largely unknown. In fact, no single study or case report is available in the literature on CDI in Ethiopia.

Table 1 Summary of the Cases

	Case 1	Case 2	Case 3	Case 4
Age (years)	67	70	73	25
Sex	Male	Male	Male	Male
Duration of diarrhea	4 weeks	3 weeks	6 weeks	2 weeks
Antibiotics used	Ciprofloxacin Co-trimoxazole Tinidazole	Cefuroxime Norfloxacin	Ceftriaxone	Cefepime, Meropenem Ciprofloxacin
Comorbidities	None –	ESRD, Diabetes Hypertension	Surgery	AML Chemotherapy
Diagnosis by	Colonoscopy, Stool toxin assay Histopathology	Colonoscopy, CT scan Histopathology	Colonoscopy, CT scan Histopathology	Colonoscopy, CT scan Histopathology
Treatment	PO vancomycin + IV metronidazole started and other antibiotics discontinued	PO vancomycin started and other antibiotics discontinued	PO vancomycin + IV metronidazole started and other antibiotics discontinued	PO vancomycin started and other antibiotics discontinued
Outcome	Improved	Improved	Improved	Improved

Given the lack of strong antibiotic stewardship in most of our hospitals and the wide use of empiric antibiotic therapy in Ethiopia, it is fair to assume that we actually have the disease in our setups and the identification of these cases should alert the medical community on the need for improving the rational use of antibiotics.

The diagnosis of CDI was made after a significant delay in all the above-reported cases and most of the diagnosis was made indirectly using a combination of clinical evidence, imaging and colonoscopy findings, and histopathology.

Though a variety of disorders including infection with other enteric pathogens, drugs, intra-abdominal sepsis, ischemic colitis and idiopathic inflammatory bowel disease can have similar manifestations as CDI, the prompt response to discontinuation of offending antibiotics and initiation of oral vancomycin seen in all of the reported patients strongly supports the diagnosis.¹²

The lack of diagnostic tests like stool toxin assays in most facilities in Ethiopia is believed to contribute to the delay in diagnosis and efforts need to be put forward to improve access to these important tests.

By presenting this case series, we hope to create awareness among clinicians and the public health community on the existence of this treatable but potentially life-

threatening disease and we recommend further studies to investigate the incidence, prevalence, risk factors, management and possible outcomes of the disease in hospitals in Ethiopia.

Ethical Approval

According to the Institutional Review Board guidelines of Addis Ababa University, a case series does not necessarily require IRB submission and ethical approval for publication, as long as the necessary informed consent is acquired from all the involved subjects and as long as the study complies with the Declaration of Helsinki, criteria which are both fulfilled by this case series. But if documentation of exemption from IRB is required, we are willing to request the IRB board and provide one.

Consent

Written informed consent was obtained from all four patients for publication of this case series and accompanying images. All the investigations performed for all patients were done as part of their clinical care and all were done with full approval by the patients. All four patients also gave consent for the use of all their investigation results in this case series.

Disclosure

The authors report no conflicts of interest in this work.

References

1. Lessa FC, Mu Y, Bamberg WM, et al. Burden of *Clostridium difficile* infection in the United States. *N Engl J Med*. 2015;372(9):825–834.
2. Antibiotic resistance threats in the United States. Centers for Disease Control; 2013 [cited September 9, 2018]. Available from: <https://www.cdc.gov/drugresistance/threat-report-2013/index.html>. Accessed September 2, 2020
3. Dubberke ER, Olsen MA. Burden of *Clostridium difficile* on the healthcare system. *Clin Infect Dis*. 2012;55(Suppl 2):S88–S92. doi:10.1093/cid/cis335
4. Chitnis AS, Holzbauer SM, Belflower RM, et al. Epidemiology of community-associated *Clostridium difficile* infection, 2009 through 2011. *JAMA Intern Med*. 2013;173(14):1359–1367. doi:10.1001/jamainternmed.2013.7056
5. Leffler DA, Lamont JT. *Clostridium difficile* infection. *N Engl J Med*. 2015;373(3):287–288.
6. Barbut F, Corthier G, Charpak Y. Prevalence and pathogenicity of *Clostridium difficile* in hospitalized patients: a French multicenter study. *Arch Intern Med*. 1996;156:1449–1454. doi:10.1001/archinte.1996.00440120107012
7. Johnson S, Gerding DN. *Clostridium difficile*-associated diarrhea. *Clin Infect Dis*. 1998;26:1027–1036. doi:10.1086/520276
8. Bartlett JG. Clinical practice. Antibiotic-associated diarrhea. *N Engl J Med*. 2002;346:334–339. doi:10.1056/NEJMcp011603
9. Kelly CP, Pothoulakis C, LaMonte JT. *Clostridium difficile* colitis. *N Engl J Med*. 1994;330:257–262. doi:10.1056/NEJM199401273300406
10. Bartlett JG. Narrative review: the new epidemic of *Clostridium difficile*-associated enteric disease. *Ann Intern Med*. 2006;145:758.
11. Sartelli M, Di Bella S, McFarland LV, et al. 2019 update of the WSES guidelines for management of *Clostridioides (Clostridium) difficile* infection in surgical patients. *World J Emerg Surg*. 2019;14(8).
12. Bartlett JG, Gerding DN. Clinical recognition and diagnosis of *Clostridium difficile* infection. *Clin Infect Dis*. 2008;46 (Supplement_1):S12–S18. doi:10.1086/521863

International Medical Case Reports Journal

Dovepress

Publish your work in this journal

The International Medical Case Reports Journal is an international, peer-reviewed open-access journal publishing original case reports from all medical specialties. Previously unpublished medical posters are also accepted relating to any area of clinical or preclinical science. Submissions should not normally exceed 2,000 words or 4

published pages including figures, diagrams and references. The manuscript management system is completely online and includes a very quick and fair peer-review system, which is all easy to use. Visit <http://www.dovepress.com/testimonials.php> to read real quotes from published authors.

Submit your manuscript here: <https://www.dovepress.com/international-medical-case-reports-journal-journal>