

# Sixth Cranial Nerve Palsy as the Presenting Sign of Metastatic Cholangiocarcinoma

This article was published in the following Dove Press journal:  
*International Medical Case Reports Journal*

Benjamin J Fowler  
Byron L Lam

Department of Ophthalmology, Bascom  
Palmer Eye Institute/University of Miami,  
Miller School of Medicine, Miami,  
FL, USA

**Background:** Cholangiocarcinoma is a locally invasive, poorly treatable malignancy of the biliary tract that uncommonly metastasizes to the brain and rarely causes neuro-ophthalmologic complications.

**Case Presentation:** A 34-year-old woman with an isolated sixth cranial nerve palsy underwent brain neuroimaging and was found to have a large sellar/suprasellar mass invading the cavernous sinus. Gross total resection was performed with improvement in the sixth cranial nerve palsy. Next-generation sequencing and histology studies revealed an adenocarcinoma with a fibroblast growth factor receptor (*FGFR*)2-*BICC1* gene mutation. Positron emission tomography/computed tomography scan demonstrated a large hypermetabolic partially necrotic hepatic mass with local invasion, and liver biopsy confirmed a diagnosis of cholangiocarcinoma. At three weeks after resection, the brain lesion recurred and the patient developed worsening diplopia. The patient then received stereotactic radiotherapy applied to the brain lesion and began treatment with gemcitabine and cisplatin. The patient was transitioned to *FGFR*-targeted therapy with pemigatinib, and the patient was alive at last follow-up, 49 weeks after diagnosis.

**Conclusion:** To our knowledge, this is the first report of cholangiocarcinoma presenting as a neuro-ophthalmologic finding, consisting of an isolated sixth cranial nerve palsy, which was the harbinger of a brain metastatic sellar/suprasellar mass. The case highlights the importance of prompt neuroimaging in isolated cranial nerve palsies, particularly in younger patients, and consideration of rare aggressive metastasis to the sellar region, where prompt surgery and pathology are critical in identifying the primary carcinoma and to instituting expedited therapy.

**Keywords:** cholangiocarcinoma, sixth cranial nerve palsy, diplopia, metastasis, sellar mass, pemigatinib

## Introduction

Cholangiocarcinoma is a locally invasive, poorly treatable primary malignancy of the biliary tract. Distant metastasis is uncommon, and the incidence of brain metastasis was 0.15%, 0.47% and 1.4% in three large case series of cholangiocarcinoma.<sup>1-3</sup> Even more rare are neuro-ophthalmologic and ocular presentations of cholangiocarcinoma, with only eight such cases in the literature.<sup>4-6</sup> We report a woman with isolated sixth cranial nerve palsy from an invasive brain metastatic sellar/suprasellar mass as the presenting feature of cholangiocarcinoma, which to our knowledge has not been previously reported.

## Case Presentation

A 34-year-old woman presented with two weeks of diplopia. Her medical history included obesity, myopia treated with laser in situ keratomileusis (LASIK) treatment in

Correspondence: Byron L Lam  
Department of Ophthalmology, Bascom  
Palmer Eye Institute/University of Miami,  
Miller School of Medicine, 900 NW 17th  
Street, Miami, FL 33136, USA  
Tel +1 305 326-6021  
Fax +1 305-482-5144  
Email blam@med.miami.edu

both eyes, and pilonidal cyst removal. The patient was evaluated in the ophthalmic emergency room with binocular horizontal diplopia and moderate-to-severe headache of one week duration. She denied trauma, recent illness, pain with eye movement, numbness, weakness, change in menstrual cycle or recent weight changes. On examination, she had an 8-prism diopter right esotropia in primary gaze with a -2 abduction deficit of the right eye. The remainder of the cranial nerve exam was normal. A complete neurologic and systemic physical exam was performed and was otherwise normal. The visual acuity was 20/20 in each eye, and the remainder of the ophthalmic examination (intraocular pressure, pupillary exam, slit lamp and fundus examinations) was normal. The findings were consistent with an acute isolated sixth cranial nerve palsy. Magnetic resonance imaging (MRI) of the brain and orbits revealed a  $2.2 \times 3.0 \times 2.5$  cm sellar/suprasellar mass with internal cystic necrotic component and abutment of the cavernous sinuses (Figure 1A and B). The pituitary stalk was thickened and deviated to the left. The mass extended into the right sphenoid sinus, dorsum sellae, and clivus. Prolactin, adrenocorticotrophic hormone, cortisol, follicle stimulating hormone and luteinizing hormone were within normal limits. Gross total resection was achieved via an endoscopic transnasal transsphenoidal approach, as confirmed on post-operative MRI. Pathology of the clival lesion revealed a moderately differentiated adenocarcinoma. The lesion was also sent for next-generation sequencing of DNA/RNA and immunohistochemistry (Claris Life Sciences).

At three weeks after the resection, her sixth cranial nerve palsy improved; she was no longer diplopic in primary gaze, although she had a residual 6-diopter right esotropia on right gaze. Humphrey visual field testing, retinal nerve fiber layer and ganglion cell layer optical coherence tomography were normal, which is consistent with radiographic findings that there was no compression of the optic chiasm or nerve.

At five weeks after resection, the patient developed new onset horizontal diplopia in primary gaze with a worsened (-4) abduction deficit of the right eye. An MRI at that time revealed recurrence of a mass centered in the sphenoid sinus with new bulging into the right cavernous sinus and involvement of right Dorello's canal (Figure 1C and D). Positron emission tomography/computed tomography (PET/CT) scan at that time demonstrated a large hypermetabolic partially necrotic mass in the right hepatic lobe extending to the caudate lobe. There was also a hypermetabolic left hepatic lobe mass and

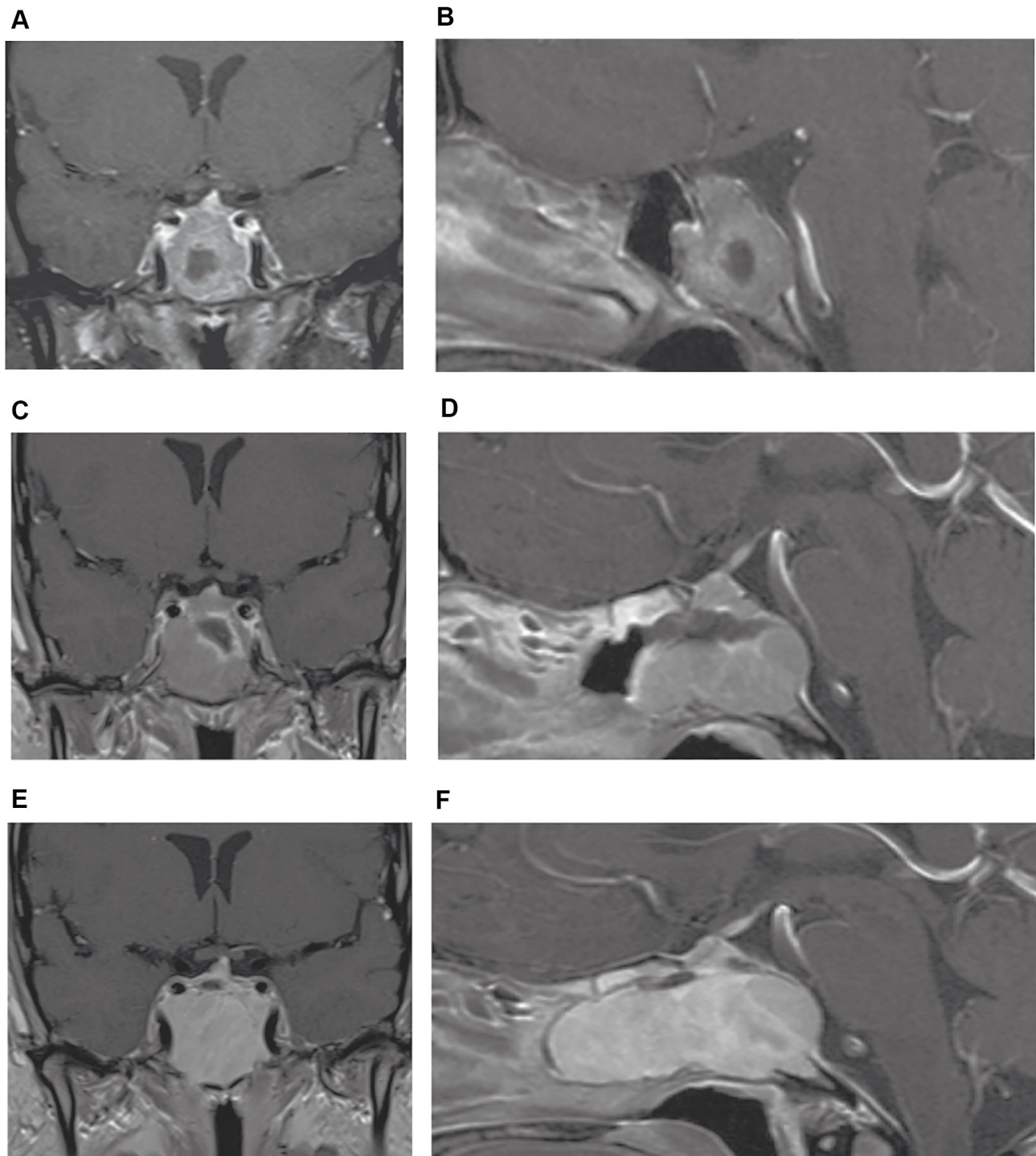
hypermetabolic portocaval lymph node suspicious for metastasis.

The liver lesions were biopsied and histology revealed a moderate to poorly differentiated adenocarcinoma, consistent with cholangiocarcinoma, with immunostains positive for cytokeratin (CK)7, CK20, and CK19. Immunostaining of the metastatic clival lesion was also positive for CK7 and CK20. Alkaline phosphatase (169 U/L), aspartate aminotransferase (AST; 34 U/L) and alanine aminotransferase (ALT; 68 U/L) were mildly elevated, whereas total bilirubin levels were normal. Cancer antigen 19-9 (CA 19-9) at the time of diagnosis was 164 U/mL. Next generation RNA whole transcriptome sequencing of the metastatic tissue revealed an *FGFR2-BICC1* gene fusion (exon 17 of *FGFR2* joined in-frame to exon 3 of *BICC1*), which has been described in a molecular subtype of cholangiocarcinoma patients and has been shown to drive cell proliferation.<sup>7</sup> Next generation sequencing of DNA from the metastatic lesion also revealed a pathogenic variant in exon 2 of the cell cycle regulator gene *CDKN2A* (c.238C>T).

At seven weeks after resection, the patient received stereotactic radiotherapy applied to the brain lesion (30 Gy in five fractions) and then began treatment with gemcitabine and cisplatin. At 13 weeks after resection, MRI of the brain revealed an interval increase in size of the clival lesion with further invasion of the cavernous sinus and dural extension (Figure 1E and F). The patient continued gemcitabine and cisplatin treatment for eight cycles with a partial metabolic improvement in her multiple liver lesions on PET/CT, and slightly decreased size of the clival lesion on MRI. Then, at 33 weeks after resection, treatment was changed to pemigatinib, a kinase inhibitor approved by the FDA for the patients with cholangiocarcinoma harboring fibroblast growth factor receptor (*FGFR2*) gene fusions or rearrangements.<sup>8</sup> Ten weeks after starting pemigatinib, there was again a slightly decreased size of the clival lesion on MRI brain. CA 19-9 levels prior to starting chemotherapy, after eight cycles of gemcitabine and cisplatin, and with ongoing pemigatinib monotherapy (at 45 weeks after resection) were 260, 161, and 28 U/mL, respectively. The patient was alive at 49 weeks after initial presentation.

## Discussion

To our knowledge, this case is unique as the first report of cholangiocarcinoma presenting as a neuro-ophthalmic finding, consisting of an isolated sixth cranial nerve palsy, which was the harbinger of a brain metastatic sellar/suprasellar



**Figure 1** T1-weighted MRI with gadolinium contrast of the metastatic lesion. At presentation, coronal (**A**) and sagittal (**B**) views showing expanded sella with thick-walled sellar/suprasellar mass with extension into the right sphenoid sinus, dorsum sellae, and clivus. At one month after resection, coronal (**C**) and sagittal (**D**) views showing recurrence and of the enhancing mass centered in the sphenoid sinus with locoregional involvement, new bulging into the right cavernous sinus and involvement of right Dorello's canal. At three months after resection, coronal (**E**) and sagittal (**F**) views showing significant increase in size of the mass. The lesion involved the sphenoid sinus and posterior ethmoid air cells, elevating the sellar floor and displacing the pituitary gland superiorly. The lesion extended to the cavernous sinus and abutted the cavernous carotid arteries, with erosion of the posterior cortex of the clivus, mild retroclival extension with dural involvement, and partial encasement of the basilar artery.

mass. The five previously reported neuro-ophthalmologic presentations of cholangiocarcinoma include one case of a clival mass and sixth cranial nerve palsy, one case of

metastasis to the medial rectus muscle and diplopia, two cases of metastasis to the occipital lobe and homonymous hemianopia, and one case of a hypercoagulable state-related

stroke and homonymous hemianopia.<sup>4</sup> There have also been two reports of cholangiocarcinoma metastasizing to the orbit presenting with eye pain,<sup>5</sup> and one report of a combined hepatocellular carcinoma/cholangiocarcinoma metastasizing to the retina and vitreous.<sup>6</sup>

This case is also distinctive because the patient had normal bilirubin levels and no other abnormal physical examination findings or subjective complaints other than mildly elevated liver enzymes, sixth cranial nerve palsy, and diplopia. The most common presenting symptoms of cholangiocarcinoma are jaundice, pruritis, abdominal pain, weight loss, malaise, or night sweats.<sup>9</sup> Liver enzyme abnormalities are also common findings at presentation, especially with more advanced disease.

The diagnosis of cholangiocarcinoma is typically made at advanced stages, which confers an unfavorable prognosis. The median survival after diagnosis of brain metastasis from cholangiocarcinoma ranges from 9.5 weeks to 16 weeks.<sup>1–3</sup> Therefore, the outcome in this case was particularly successful, as the patient was alive at last follow-up, 49 weeks after diagnosis.

In this case, the initial invasion of the cavernous and sphenoid sinuses at presentation, and the recurrence and marked enlargement of the mass after resection, highlight the aggressive nature of cholangiocarcinoma. Radiation therapy is beneficial in some cases of intrahepatic or perihilar cholangiocarcinoma,<sup>10</sup> however the role of radiation in brain metastasis from cholangiocarcinoma is less clear. Only a few cases of cholangiocarcinoma with brain metastasis have been treated with post-operative radiation, and there is a lack of evidence regarding the efficacy and most appropriate timing of radiotherapy in these instances. Moreover, when the primary source of metastasis is unknown, radiation is typically deferred until a definitive diagnosis is made;<sup>11</sup> thus, in this patient, radiation therapy was not performed immediately after resection. Importantly, radiosurgery to the sellar/parasellar region is limited by its potential for iatrogenic damage to surrounding neurovascular structures including the optic nerve, pituitary gland, and cranial nerves.

Cholangiocarcinoma metastasis is rare, and only 26 cases of solid CNS metastasis from cholangiocarcinoma have been reported.<sup>10,12</sup> A 2010–2015 review of the US population revealed that the brain was the site of metastasis in 1.6% of patients with stage IV intrahepatic cholangiocarcinoma.<sup>13</sup> The most common primary malignancies that metastasize to the sellar/suprasellar region are breast and lung cancer.<sup>11,14</sup> Other important tumors in this

anatomic region are pituitary adenomas and the much rarer invasive primary pituitary carcinoma. The unique presentation of our case reveals the importance of considering atypical causes of aggressive metastasis to the sellar/suprasellar region, including cholangiocarcinoma, where prompt surgery and pathology are critical in identifying the primary carcinoma and to instituting expedited therapy.

## Ethics Approval and Consent to Participate

The patient provided written consent for this study and for allowing the use of clinical images and information for the purposes of publication. This study of de-identified case report was exempt from ethical approval by the Institutional Review Board of the University of Miami.

## Disclosure

The authors report no conflicts of interest in this work.

## References

- Chindaprasit J, Sookprasert A, Sawanyawisuth K, Limpawattana P, Tiangkao S. Brain metastases from cholangiocarcinoma: a first case series in Thailand. *Asian Pac J Cancer Prev*. 2012;13(5):1995–1997. doi:10.7314/APJCP.2012.13.5.1995
- D'Andrea MR, Gill CM, Umphlett M, et al. Brain metastases from biliary tract cancers: a case series and review of the literature in the genomic era. *Oncologist*. 2020;25(5):447–453. doi:10.1634/theoncologist.2019-0306
- Frega G, Garajova I, Palloni A, et al. Brain metastases from biliary tract cancer: a monocentric retrospective analysis of 450 patients. *Oncology*. 2018;94(1):7–11. doi:10.1159/000479929
- Rico G, Smith SV, Siddiqui Y, Whyte A, Gombos D, Lee AG. Neuro-ophthalmologic manifestations of cholangiocarcinoma: a case series. *Eye (Lond)*. 2017;31(8):1245–1248. doi:10.1038/eye.2017.77
- Fujimoto K, Kuroda J, Makino K, Hasegawa Y, Kuratsu J. Skull metastasis from intrahepatic cholangiocarcinoma: report of 3 cases and review of the literature. *Neurol Med Chir (Tokyo)*. 2013;53(10):717–721. doi:10.2176/nmc.cr2012-0237
- Praidou A, Jacob S, Irion L, et al. Retinal and vitreous metastases from hepatocellular carcinoma. *BMC Cancer*. 2017;17(1):430. doi:10.1186/s12885-017-3429-8
- Arai Y, Totoki Y, Hosoda F, et al. Fibroblast growth factor receptor 2 tyrosine kinase fusions define a unique molecular subtype of cholangiocarcinoma. *Hepatology*. 2014;59(4):1427–1434. doi:10.1002/hep.26890
- Abou-Alfa GK, Sahai V, Hollebecque A, et al. Pemigatinib for previously treated, locally advanced or metastatic cholangiocarcinoma: a multicentre, open-label, Phase 2 study. *Lancet Oncol*. 2020;21(5):671–684. doi:10.1016/S1470-2045(20)30109-1
- Forner A, Vidili G, Rengo M, Bujanda L, Ponz-Sarvisse M, Lamarca A. Clinical presentation, diagnosis and staging of cholangiocarcinoma. *Liver Int*. 2019;39(Suppl 1):98–107. doi:10.1111/liv.14086
- Novogno F, Umana G, Granaroli P, Borri F, Orlandi A, Lunardi P. Current management of central nervous system metastasis from cholangiocarcinoma: the neurosurgical perspective. Literature review. *Br J Neurosurg*. 2019;1–9.

11. Altay T, Krisht KM, Couldwell WT. Sellar and parasellar metastatic tumors. *Int J Surg Oncol.* 2012;2012:647256.
12. Tan SK, Luther E, Eichberg D, et al. Complete regression of a solitary cholangiocarcinoma brain metastasis following laser interstitial thermal therapy. *World Neurosurg.* 2020;144:94–98. doi:10.1016/j.wneu.2020.08.122
13. Yan X, Wang P, Zhu Z, et al. Site-specific metastases of intrahepatic cholangiocarcinoma and its impact on survival: a population-based study. *Future Oncol.* 2019;15(18):2125–2137. doi:10.2217/fon-2018-0846
14. Morita A, Meyer FB, Laws ER Jr. Symptomatic pituitary metastases. *J Neurosurg.* 1998;89(1):69–73. doi:10.3171/jns.1998.89.1.0069

### International Medical Case Reports Journal

Dovepress

### Publish your work in this journal

The International Medical Case Reports Journal is an international, peer-reviewed open-access journal publishing original case reports from all medical specialties. Previously unpublished medical posters are also accepted relating to any area of clinical or preclinical science. Submissions should not normally exceed 2,000 words or 4

published pages including figures, diagrams and references. The manuscript management system is completely online and includes a very quick and fair peer-review system, which is all easy to use. Visit <http://www.dovepress.com/testimonials.php> to read real quotes from published authors.

Submit your manuscript here: <https://www.dovepress.com/international-medical-case-reports-journal-journal>