

Voretigene Neparvovec and Gene Therapy for Leber's Congenital Amaurosis: Review of Evidence to Date

This article was published in the following Dove Press journal:
The Application of Clinical Genetics

Srikanta Kumar Padhy¹
Brijesh Takkar^{2,3}
Raja Narayanan²
Pradeep Venkatesh⁴
Subhadra Jalali^{2,5}

¹Vitreoretina and Uveitis Services, L V Prasad Eye Institute, Mithu Tuli Chanrai Campus, Bhubaneswar, India; ²Srimati Kanuri Santhamma Center for Vitreoretinal Diseases, Kallam Anji Reddy Campus, L.V. Prasad Eye Institute, Hyderabad, India; ³Center of Excellence for Rare Eye Diseases, Kallam Anji Reddy Campus, L V Prasad Eye Institute, Hyderabad, India; ⁴Dr RP Centre for Ophthalmic Sciences, All India Institute of Medical Sciences, New Delhi, India; ⁵Jasti V. Ramanamma Childrens' Eye Care Centre, Kallam Anji Reddy Campus, L V Prasad Eye Institute, Hyderabad, India

Abstract: Gene therapy has now evolved as the upcoming modality for management of many disorders, both inheritable and non-inheritable. Knowledge of genetics pertaining to a disease has therefore become paramount for physicians across most specialities. Inheritable retinal dystrophies (IRDs) are notorious for progressive and relentless vision loss, frequently culminating in complete blindness in both eyes. Leber's congenital amaurosis (LCA) is a typical example of an IRD that manifests very early in childhood. Research in gene therapy has led to the development and approval of voretigene neparvovec (VN) for use in patients of LCA with a deficient biallelic *RPE65* gene. The procedure involves delivery of a recombinant virus vector that carries the *RPE65* gene in the subretinal space. This comprehensive review reports the evidence thus far in support of gene therapy for LCA. We explore and compare the various gene targets including but not limited to *RPE65*, and discuss the choice of vector and method for ocular delivery. The review details the evolution of gene therapy with VN in a phased manner, concluding with the challenges that lie ahead for its translation for use in communities that differ much both genetically and economically. **Keywords:** gene therapy, voretigene neparvovec, Luxturna, Leber's congenital amaurosis, retinal dystrophy

Introduction

Inherited retinal dystrophies (IRD) include a diverse group of bilateral and often progressive retinal diseases which cause functional loss of vision and may subsequently progress to legal blindness. IRDs encompass both non-syndromic conditions like Leber's congenital amaurosis (LCA), retinitis pigmentosa (RP), etc., as well as syndromic conditions involving multiple organs in addition to the eye such as Usher syndrome, Bardet-Biedel syndrome, etc.¹ Before the detection of gene defects, IRDs were classified according to clinical features, age of onset, and Mendelian inheritance pattern. With the leap forward in the field of genetics and subsequent identification of causative genes and mutations over the past three decades, a much better understanding of disease pathologies in IRD is now present. The current approach is now towards classifying IRDs on the basis of genotype and not phenotype.²

In 1869, German ophthalmologist Dr Theodor Leber first described LCA.^{3,4} He mentioned the progressive course of retinal degeneration in his initial description of young children with LCA, but later noted non-progressive variants too.^{5,6} Treatment of both RP and LCA has long been controversial, with poor outcomes

Correspondence: Brijesh Takkar
Srimati Kanuri Santhamma Center for Vitreoretinal Diseases, Kallam Anji Reddy Campus, L.V. Prasad Eye Institute, L V Prasad Marg, Banjara Hills, Hyderabad 500034, Telangana, India
Tel +91-9868092215
Fax +91-40-23548271
Email britak.aiims@gmail.com

marked by relentless disease progression and not uncommonly, though not universally, an eventual complete blindness. Varied therapies had been attempted, including pharmacological, surgical, electrical, ozone therapy, and stem cells, before LCA became the first eye disorder successfully treated with gene therapy.

Anderson et al⁷ launched human gene therapy in 1990 by treating a child suffering from severe combined immunodeficiency. The triumph of that gene therapy was short-lived, but acknowledged by significant media coverage. The gene therapy did not completely cure the patient's condition and she had to continue previous forms of therapy. As further clinical trials of gene therapy were launched, the potential risks involved with such were revealed, including immune mechanisms driven mortality and neoplasia,⁸ necessitating more research and refinement. Based on the cell targeted, gene therapy can be classified into

Somatic cell gene therapy (SCGT); in which therapeutic genes are transferred to somatic cells which are not inherited to future generations and germline gene therapy (GGT); here therapeutic genes are introduced into germ cells, therefore the changes are heritable and passes to later generations.^{9–11}

The vehicles used for transfer of desired genes to target cells are called vectors, broadly classified into viral and non-viral types. The essential features of an ideal vector comprise cellular specificity (induction of only targeted cells), large cloning specificity, low immunogenicity, and the feasibility of being produced at a high titre.¹² Different viruses have been used as vectors in humans, and adeno-associated viruses (AAV) are the most common and most widely used.^{12–15} Gene therapy for LCA with voretigene neparovec (VN) (LUXTURN A, Novartis AG, Basel, Switzerland) is SCGT based and dependent on an AAV vector, and is the first such therapy approved for IRD by the US-FDA in 2017 following publications from Phase III trials (NCT00999609). It was developed by Spark Therapeutics as AAV2-hRPE65v2.¹⁶ Other similar developments in earlier phases of research include rAAV2-CB-hRPE65 by Applied Genetic Technologies Corporation (5 year results of Phase I/II trial published, NCT00749957), and AAV2/5-OPTIRPE65 by MeiraGTx (Phase I/II study completed in December 2018, NCT02781480). The latter two are not yet approved for human use.

With approval of VN, the targets are now shifting to other human diseases – from rare ones with no available therapy to common disorders with many other therapeutic options. Gene therapies not only signify a successful alternative in potentially curative medicine, but they pose the next affordability dilemma too. For example, gene therapy with VN currently costs around US\$ 850,000. However, in some situations a one-time gene therapy may be useful in the longer run.¹⁷ This review focuses on the evolution and evidence of gene therapy for LCA especially with VN, bringing out the challenges physicians might face towards its application to population at large.

Exploring Gene Targets in LCA

LCA is a genetically heterogeneous ocular condition where the primary mode of inheritance is autosomal recessive, though a few dominant traits are also reported. There are as many as 28 genes implicated in the pathogenesis of the disease. Mutation in these genes account for almost 75% of the cases.¹⁸ The more common and well characterized ones, where attempts at gene therapy have been made, are discussed below (Table 1).

GUCY2D Gene (LCA1 Locus)

GUCY2D mutation (located on chromosome 17) accounts for 10–20% of cases of autosomal recessive LCA and 40% cases of autosomal dominant cone rod dystrophy.¹⁹ The *GUCY2D* gene is expressed in both types of photoreceptors (rods and cones), predominant in disc membranes of cone receptor outer segments. The gene codes a protein, retinyl guanylate cyclase 1 (GC-1) that is important for the synthesis of c-GMP. This c-GMP, the intracellular messenger of photoreceptor excitation, in turn regulates intracellular calcium levels, a vital step in phototransduction (conversion of light to neuronal signals) in the recovery phase. It allows the resurrection of cGMP-gated channels by replenishing cGMP stores within the cell, thus regaining the resting depolarized state after the activation stimulus.²⁰ Mutation of *GUCY2D* leads to a state which is comparable to chronic light exposure. *GUCY2D*-associated LCA patients usually show marked vision loss, photophobia, hyperopia, nystagmus, and defective ERG since early childhood.^{21,22} Regardless of the severe vision loss, clinical retinal changes are minimal.

Animal model gene therapy for *GUCY2D* mutants has used both AAV and lentiviral vectors. Preserved ellipsoid zone integrity on OCT, despite damaged receptor functions, opens the door for gene therapy trials.^{23–25}

Table 1 Targets of Gene Therapy for Leber's Congenital Amaurosis

Gene	Chromosome	LCA Locus	% of LCA Cases	Mode of Inheritance	Protein Affected (pathway)	Location and Visual Cycle Effect	Phenotype -Specific Aspects	Prominent OCT Features	Progress in Gene Therapy
<i>GUCY2D</i> ¹⁹⁻²⁴	17p13.1	LCA 1	10-20%	Autosomal recessive	Retinal guanylyl cyclase 1 (GCI) (Phototransduction)	Persistent closure of the cGMP-gated channels leading to a state equivalent to chronic light exposure	Marked vision loss Nystagmus Hyperopia Photophobia Reduced, or extinguished ERG Since early childhood Retinal fundus remains normal	Relatively preserved outer retinal/photoreceptor structure Foveal cone outer segment abnormalities and foveal cone loss	Reported therapeutic success using AAV and lentiviral vectors in animal models
<i>RPE-specific protein 65</i> ⁶⁰⁻⁶²	1p31.3-p31.2	LCA 2	3-16%	Autosomal recessive	Retinoid isomerohydrolase enzyme (Retinoid visual cycle)	Responsible for retinol isomerization and converts all-trans retinyl ester to 11- <i>cis</i> retinol in phototransduction	Severe profound vision loss in infancy with mild nystagmus; Early stage of the disease shows Bull's maculopathy, while atrophic lesions, dot like diffuse hyperpigmentation, pigment clumping generally appears late in the course	Relatively normal retinal thickness in some patients; with more commonly a central macular area of relatively preserved retina with a ring of thinning or more widespread retinal loss	Voretigene neparvovec first FDA approved gene therapy based on an AAV (see Table 2)

(Continued)

Table 1 (Continued).

Gene	Chromosome	LCA Locus	% of LCA Cases	Mode of Inheritance	Protein Affected (pathway)	Location and Visual Cycle Effect	Phenotype -Specific Aspects	Prominent OCT Features	Progress in Gene Therapy
SPATA7 ⁷⁴⁻¹²⁴⁻¹²⁶	14q31.3	LCA 3	1.7%	Autosomal recessive	Spermatogenesis associated protein 7 (Photoreceptor ciliary transport)	Affects vesicular transport Required for correct cellular translocation of RGRIP1 protein in the retina	Transient photophobia in first year of life, nyctalopia by 3 years; Visual acuity becomes stable by 1st decade of life; Fundus appears typically that of retinitis pigmentosa	Preservation of foveal architecture early in the disease	Long-term improvement of photoreceptor function by AAV8 (Y733F)-introduced Spata7 expression in a mouse model
AIPL1 ²⁶⁻³²	17p13.1	LCA 4	4-8%	Autosomal recessive	Aryl-hydrocarbon -interacting protein-like 1 (Phototransduction and protein biosynthesis)	Mutation prevents assembly of PDE6 holoenzyme leading to an increase in intracellular cGMP resulting in prolonged opening of the cyclic nucleotide-gated channels and excessive influx of Ca ²⁺	Pigmentary changes and maculopathy at an early age Maculopathy that is specific for drusen-like deposits and variable pigmentary atrophic changes with patches of hypopigmentation and pigmentary clumping Photophobia, light gazing and night blindness Nystagmus, keratoconus, hyperopia, extinguished ERG and cataract	A relative preservation of central outer retinal structure	Gene replacement therapy using an AAV2/8 vector in an AIPL1 knock-out mouse model has shown promising results in restoration of cellular function

LCA 5 ¹²⁷⁻¹³⁰	6q14	LCA 5	1-2%	Autosomal recessive	Lebercillin (Photoreceptor ciliary transport)	Located at the cilium between the inner and outer segments of photoreceptors Inactivation results in photoreceptor degeneration due to failure in outer segment formation	Nystagmus, high hypermetropia, oculodigital sign, severe visual dysfunction at birth, extensive peripheral field loss Fundus: Widespread retinal and RPE atrophy, macula normal, rarely atypical macular coloboma	Macular atrophy, disruption of retinal lamination and presence of hyporeflective well preserved area in the outer nuclear layer with a hyperreflective border	LCA5-LCA patients may benefit from gene augmentation therapies despite early-onset and uniquely severe retinal degeneration-results obtained from mice experiments
RPGRIPI ²¹⁻³³⁻³⁷	14q11	LCA 6	5%	Autosomal recessive	Retinitis pigmentosa GTPase regulator-interacting protein 1 (Photoreceptor ciliary transport)	Helps in anchoring RPGR at the connecting cilia between the inner and outer segments of photoreceptor cells Photoreceptor ciliary transport	Relatively non-progressive, following an initial rapid decline in visual function	Preserved central foveal outer retinal structures surrounded by retinal laminar disorganization	RPGRIPI knock-out mouse and RPGRIPI deficient mouse and dog models have been characterized and have provided models for preclinical gene replacement studies
CRX ¹³¹⁻¹³⁵	19q13.3	LCA 7	1-3%	Autosomal recessive, Rare Autosomal dominant LCA	Cone-rod homeobox (Photoreceptor morphogenesis)	Transcription factor essential for both photoreceptor outer segment elongation and phototransduction cascade	Severe relatively stable vision loss in the first few months of life, high hyperopia, Photodysphoria, Keratoconus, Cataract Diffuse pigmentary retinal changes and colobomatous-like atrophic macular changes	OCT shows macular atrophy without noticeable signal of the junction between inner and outer segments	-

(Continued)

Table 1 (Continued).

Gene	Chromosome	LCA Locus	% of LCA Cases	Mode of Inheritance	Protein Affected (pathway)	Location and Visual Cycle Effect	Phenotype -Specific Aspects	Prominent OCT Features	Progress in Gene Therapy
<i>CRB1</i> ³⁸⁻⁴²	1q31-q32.1	LCA 8	7-17%	Autosomal recessive	Protein crumbs homolog 1 (Photoreceptor morphogenesis)	Implicated in cellular adhesion, apico-basal polarity and intracellular communication Critical for photoreceptor morphogenesis and function	Variable VA with possible mild temporary improvement followed by noticeable decline High hypermetropia Late-onset maculopathy, isolated AR foveal retinoschisis. Fundus: Nummular pigmentation maculopathy with preservation of the para-arteriolar RPE	Relative para-arteriolar preservation of the RPE with retinal thickening with loss of lamination (unlaminated thickened retina)	
<i>NMNAT1</i> ^{43,136}	1p36.22	LCA 9	Unknown	Autosomal recessive	Nicotinamide/nicotinic acid mononucleotide adenyl transferase 1 (Coenzyme NAD biosynthesis)	Rate limiting step of NAD biosynthesis and is essential for cell survival	Severe form of hereditary retinal degeneration Mainly atrophic lesion. Macular pseudocoloboma, Retinal pigmentary changes. Nystagmus, severe vision loss	Overall thinned retina	Mouse models has shown promising results
<i>CEP290</i> ^{43-49,137}	12q21-q22	LCA 10	15-20%	Autosomal recessive	Centrosomal protein Cep290 (Photoreceptor ciliary transport)	Centrosomal protein which is a part of cilium connecting inner and outer segments of photoreceptor Mutation leads to ciliopathies	Typically suffer early onset of marked visual loss with corresponding receptor dysfunction	Profound cone dysfunction, foveal outer nuclear layer is well preserved up to fourth decade of life	See Table 3

<i>IMPDH1</i> ^{138,139}	7q32.1	LCA 11	5–8%	Autosomal recessive	Inosine 5' monophosphate dehydrogenase 1 (Guanine synthesis)	Denovo synthesis of de guanine nucleotide	Nystagmus with no fixation to light. Retina showing diffuse RPE mottling. No pigmentary deposits	-	-
<i>RD3</i> ^{51,–140–142}	1q32.3	LCA 12	<1%	Autosomal recessive	Retinal degeneration 3 (Protein trafficking)	RD3 is a chaperone protein required for the exit of guanylate cyclase from the endoplasmic reticulum of photoreceptors during outer segments trafficking	Poor vision with progressive decrease Initial hypermetropia progressing to myopia over the course of the disease Nystagmus Atrophic macular lesions possibly progressing to a bull's-eye pattern with central yellow pigmentation	Disorganization of all retinal layers	-

(Continued)

Table 1 (Continued).

Gene	Chromosome	LCA Locus	% of LCA Cases	Mode of Inheritance	Protein Affected (pathway)	Location and Visual Cycle Effect	Phenotype -Specific Aspects	Prominent OCT Features	Progress in Gene Therapy
Retinol dehydrogenase 12 ⁴⁴⁻⁵¹⁻⁵⁶	14q23.3-q24.1	LCA 13	4-5%	Autosomal recessive	Retinol dehydrogenase 12 (Retinoid visual cycle)	Localized to the photoreceptor inner segment of rods and cones Has reductase activity which reduces all trans retinal to all trans retinol	Severe yet progressive in nature, early onset visual dysfunction, night blindness, early macular atrophy However, no hyperopia and photophobia Loss of normal foveal architecture and macular thinning. Predominantly affects rods and cones at the central retina with relative preservation of peripheral rod responses Coats like exudative vasculopathy	Severely disorganized retinal architecture corresponding to macular excavation with variable thinning or thickening of retinal layers	Promising results of AAV2/8-vector-mediated RDH12 gene replacement therapy in Rdh12 knock-out mice
Lectin: retinol Acyltransferase ²	4q32.1	LCA 14	<1%	Autosomal recessive	Lectin retinol acyltransferase (Retinoid visual cycle)	Esterification of all-trans-retinol in RPE	Since early childhood nyctalopia, poor vision, and nystagmus Photophobia rarely	Preservation of central retinal structure, including outer photoreceptor layers in some cases, few other cases relatively well-preserved outer retinas until late	Intraocular injection of rAAV carrying the LRAT gene, restoration of ERG responses in all treated mice to ~50% of wild-type levels No human gene therapy available till date

<i>TULP1</i> ^{143,144}	6p21.31	LCA 15	<1%	Autosomal recessive	Tubby-like protein I (Photoreceptor ciliary transport)	<i>TULP1</i> contributes to rhodopsin transport between the inner and outer segments of photoreceptor cells ⁷⁴ and stimulates the phagocytosis of RPE cells	Reading vision in early stages Nystagmus, hemeralopia, mild myopia; no photophobia, severely disturbed color vision, moderate to severely affected visual field Fundus: normal at early age, progressing to indistinct foveolar reflex and pronounced salt-and-pepper maculopathy later on with midperipheral RPE atrophy	Preserved central island of ONL that decreases in thickness eccentrically with normal or reduced foveal ONL peak	A small central island of impaired vision would seem to be an unlikely target for a subretinal surgical procedure The restricted central islands of cone structure may be approachable by an intravitreal gene delivery
<i>KCNJ13</i> ⁵⁷⁻⁵⁹	2q37.1	LCA 16	Unknown	Autosomal recessive	Kir7 inwardly rectifying potassium channel (Phototransduction)	<i>KCNJ13</i> , which is expressed in the apical microvilli of retinal pigment epithelia, is a potassium channel involved in maintaining the resting membrane potential near the potassium equilibrium potential	Poor night and reading visual function at an early age. Progressive visual deterioration affecting both peripheral and central vision Fundus: Severe retinopathy with nummular pigment and retinal degeneration and thinning	Loss of outer retinal structures with RPE/Bruch membrane thinning	In vivo use Lentivirus mediated gene therapy treatments suggested that 25% of normal protein expression within a population of RPE cells restores membrane potential with variable recovery in current amplitude

(Continued)

Table 1 (Continued).

Gene	Chromosome	LCA Locus	% of LCA Cases	Mode of Inheritance	Protein Affected (pathway)	Location and Visual Cycle Effect	Phenotype -Specific Aspects	Prominent OCT Features	Progress in Gene Therapy
<i>GDf6</i> ^{145,146}	8q22.1	LCA 17	Unknown	Autosomal recessive	Grow differentiation factor 6	Codes for a widely expressed growth factor TGF-β pathway specifying the dorsal-ventral retinal axis	Severely affected vision – up to hand motion detection	–	–
<i>PPRH2</i> ¹⁴⁷⁻¹⁴⁹	6p21.1	Phenotype not described	Unknown	Autosomal recessive	Peripherin (Photoreceptor morphogenesis)	Peripherin 2 localizes to the photoreceptor outer segment, where it serves as an adhesion molecule to stabilize the segment	Variable visual acuity Fundus: Peripheral and macular pigment deposits with central atrophic and chorioretinal sclerosis	Foveal globular lesions	–

Abbreviations: LCA, Leber's congenital amaurosis; OCT, optical coherence tomography; RPE, retinal pigment epithelium; AAV, adeno-associated virus; ERG, electroretinogram; FDA, Food and Drug Administration.

AIPL1 Gene (LCA 4 Locus)

Mutation of *AIPL1* gene (Aryl-hydrocarbon-interacting-protein-like 1, chromosome 17) accounts for 4–8% cases of recessive LCA.^{26,27} It exclusively expresses in rod, cone photoreceptors, and the pineal gland. *AIPL1* acts as a photoreceptor-specific co-chaperone of phosphodiesterase 6, a crucial enzyme effector in the phototransduction pathway.²⁸ So, a mutation in *AIPL1* gene prevents assembly of the PDE6 holoenzyme. This results in an upsurge in intracellular cGMP leading to a prolonged opening of the cyclic nucleotide-gated channels. These patients develop pigmentary changes and maculopathy at an early age.^{29–31} In addition to photophobia, light gazing, and night blindness, they are also commonly affected with nystagmus, keratoconus, hyperopia, extinguished ERG, and cataract.³² Fascinatingly, hand-held OCT imaging of four patients (all of them of age less than 4 years) showed a relative preservation of central outer retinal structure, making them candidates for gene therapy.²¹ Replacement of the *AIPL1* gene with an AAV vector in a mouse model has revealed promising results in terms of restoring cellular function. The *AIPL1* sequence is small in size (~1.2 kb) so it can be proficiently packaged. Due to the rapid progression and early onset, there is only a narrow window period to intervene in order to rescue this form of retinopathy.³¹

RPGRIP1 (LCA 6 Locus)

Mutation of *RPGRIP1* gene (chromosome 14q11) accounts for 5% of cases of LCA.³³ *RPGRIP1* encodes a 1287 amino acid protein that binds with retinitis pigmentosa GTPase regulator (RPGR) and anchors it to connecting cilia present between the two segments of photoreceptors.^{34,35} In contrast to other variants, *RPGRIP1*-LCA trails a relatively non-progressive course after an initial rapid deterioration of visual acuity. In addition, the photoreceptors in the central retina remain preserved for a longer period of time following visual deterioration (which later progress to pigmentary retinopathy), providing a wide window of opportunity for intervention.²¹ Studies have been done in *RPGRIP1* knock-out mice and canine models, showing improvement in both photoreceptor function and structure.^{36,37}

CRBI Gene (LCA 8 Locus)

CRBI is a “human homologue of the *Drosophila melanogaster* gene” responsible for the protein Crumbs. Mutations in it are associated with RP, LCA (7–17% of

Table 2 Outcome Measures and Results of Human Trials on Gene Therapy for LCA 2 (RPE65)

Trial Number	Sample Size	Date Initiated	Phase	Surgery Site	Primary Measure	Primary Result	Remarks	Publications
NCT00516477	12	October 2007	I/II	Consortium of CHOP, UPENN, TIGEM and SUN	Safety and tolerability of subretinal administration of AAV2-hRPE65v2 Promotor – CBA	Safe, efficacious and well tolerated	Allocation: N/A Intervention Model: Single Group Study type – Interventional Assignment Masking: None (Open Label) Primary Purpose: Treatment Intervention- Unilateral injection	Maguire et al 2008, 2009 Simonelli et al 2010 Testa et al 2013
NCT00481546	15 (8 years and older)	October 2007	I	UFL, UPENN	Primary safety endpoint - standard ocular examination Toxicity assessment by measurement of vision, hematology, and serum chemistries, assays for vector genomes Subretinal injection of rAAV2-CBSB-hRPE65 Promotor – CBA shortened	No serious ocular or systemic adverse events	Allocation: N/A Intervention Model: Single Group Study type – Interventional Assignment Masking: None (Open Label) Primary Purpose: Treatment One or two, unocular, subretinal injections; relative doses: 0.3X (Cohort 1), 0.6X (Cohort 2), 0.45X (Cohort 3), 0.9X (Cohorts 4 and 5)	Cideciyan et al 2008, 2009, 2013; Hauswirth et al 2008; Jacobson et al 2012

(Continued)

Table 2 (Continued).

Trial Number	Sample Size	Date Initiated	Phase	Surgery Site	Primary Measure	Primary Result	Remarks	Publications
NCT00821340	10	January 2009	I	Hadassah Hospital, Jerusalem, Israel	Primary outcome measures – ocular and systemic safety Secondary outcome measures – visual function, quantified before and after vector administration Subretinal injection of rAAV2-CBSB-hRPE65	An increase in vision was present in the treated area as early as 15 days after the intervention	Allocation: N/A Intervention Model: Single Group Study type – Interventional Assignment Masking: None (Open Label) Primary Purpose: Treatment	Banin et al 2010
NCT01496040	3 cohorts of 3 patients each (total 9, aged between 6–50 years)	September 2011	I/II	Nantes University Hospital, France	Safety evaluation Subretinal injection of rAAV2/4.RPE65 Promotor – RPE 65	rAAV2/4.RPE65 vector was well tolerated and safe. Visual function improvement varied between patients	Allocation: N/A Intervention Model: Single group Assignment Masking: None (Open Label) Primary Purpose: Treatment	Le Meur G et al 2018
NCT00749957	12 (6 years and older)	December 2008	I/II	Casey eye institute, Portland	Primary outcome measures – Ocular or Non-ocular Adverse Events Secondary outcome measures – Changes in Visual Fields, and Best Corrected Visual Acuity Subretinal injection of rAAV2-CB-hRPE65 Promotor – CBA	Not associated with serious adverse events improvement in one or more measures of visual function was observed in nine of 12 patients Greatest improvements in visual acuity were observed in younger patients with better baseline visual acuity	Allocation: N/A Intervention Model: Parallel Assignment Study type – Interventional Assignment Masking: None (Open Label) Primary Purpose: Treatment	Weleber et al 2016

NCT00643747	3		2007	I/II	Moorefield's, UCL, London, UK	<p>Primary outcome measures – intraocular inflammation</p> <p>Secondary outcome measures – Visual function (microperimetry and dark adapted perimetry)</p> <p>Subretinal injection of rAAV2/2.hrPE65p.Hrpe65</p> <p>Promotor – hrPE 65</p>	<p>No serious adverse events</p> <p>No clinically significant change in visual acuity or in peripheral visual fields on Goldmann perimetry in any of the three patients</p> <p>No change in retinal responses on electroretinography</p>	<p>Allocation: N/A</p> <p>Intervention Model: Single Group</p> <p>Study type – Interventional</p> <p>Assignment Masking: None (Open Label)</p> <p>Primary Purpose: Treatment</p> <p>SAFETY TRIAL</p>	<p>Bainbridge et al 2008 (Preliminary result of the trial)</p> <p>Bainbridge et al 2015 (Longterm outcome of above clinical trial at 3 years with additionally recruited patients)</p>
	12 (5 years to 30 years)		2007	I/II	Moorefield's, UCL, London, UK	<p>An Open-label Dose Escalation Study</p> <p>Four participants were administered a lower dose of the vector, and 8 were administered a higher dose</p> <p>Subretinal injection of rAAV2/2.hrPE65p.Hrpe65</p> <p>Promotor – hrPE 65</p>	<p>Varied extents of improvements in retinal sensitivity in six participants for up to 3 years (peak at 6 to 12 months after treatment and then declining)</p> <p>No associated improvement in retinal function (on ERG)</p> <p>Three participants had intraocular inflammation, and two had clinically significant deterioration of visual acuity</p>	<p>Allocation: N/A</p> <p>Intervention Model: Single Group</p> <p>Study type – Interventional</p> <p>Assignment Masking: None (Open Label)</p> <p>Primary Purpose: Treatment</p> <p>SAFETY AND EFFICACY TRIAL</p>	

(Continued)

Table 2 (Continued).

Trial Number	Sample Size	Date Initiated	Phase	Surgery Site	Primary Measure	Primary Result	Remarks	Publications
NCT01208389	12 (8 years and older)	September 2010	I/II Follow on	CHOP, UPENN	Adverse events as a measure of safety and tolerability Primary outcome measures: safety and tolerability Secondary outcome measures: changes in visual function as measured by subjective, psychophysical tests and by objective, physiologic tests subretinal administration of AAV2-hRPE65v2 Promotor – CBA	Results (through 6 months) including evaluations of immune response, retinal and visual function testing, and functional magnetic resonance imaging indicate that re-administration is both safe and efficacious after previous exposure to AAV2-hRPE65v2	Allocation: N/A Intervention Model: Single Group Study type – Interventional Assignment Masking: None (Open Label) Primary Purpose: Treatment One time, subretinal administration of vector in 300 microliters to the contralateral, previously uninjected eye	Bennett et al 2012
NCT00999609	31 (3 years or older)	November 2013	III	CHOP, UPENN, University of Iowa	Safety and Efficacy Study Primary outcome measures: Multi-luminance Mobility Testing – MLMT (Bilateral) Secondary outcome measures – Full-field Light Sensitivity Threshold (FST) Testing Multi-luminance Mobility Testing (Monocular) Visual Acuity	Functional vision improvement measured using MLMT, FST at 1 year	Allocation: Randomized Intervention Model: Parallel Assignment Study type – interventional Masking: None (Open Label) Primary Purpose: Treatment Study arms- Interventional: Subretinal voretigene neparvovec-rzy No Intervention: Control	Russel et al 2017

NCT03602820	41 participants	June 2015 Estimated completion March 2030	Observational study	University of Pennsylvania University of Iowa	Mobility testing, Bilateral	Subretinal delivery of voretigene neparvovec	Observational cohort, non-probability sample Individuals who received the subretinal administration of voretigene neparvovec-rzyl in the Phase 1 or Phase 3 clinical trials	Not published yet
NCT03597399	Active not recruiting	January 2019	Post authorization safety study	Children's Hospital of Los Angeles, Bascom Palmer Eye Institute, University of Iowa Hospitals & Clinics and six other centers	Collection of all Adverse Events and Serious Adverse Events Secondary outcome measures: Collection of Pregnancy Outcomes	Subretinal delivery of voretigene neparvovec	Observational study, Target follow up duration – 5 years, non-probability sample Individuals who received voretigene neparvovec-rzyl in at least one eye	Not published yet

Abbreviations: CHOP, Children's Hospital of Philadelphia; TIGEM, Telethon Institute of Genetics and Medicine; SUN, Second University of Naples; UFL, University of Florida; OHSU, Oregon Health Sciences University; U Iowa, University of Iowa; Iowa, UPort, University of Portland; Portland; UMass, University of Massachusetts, Worcester.

Table 3 Gene Cassettes Under Trials for LCA in Comparison to Voretigene Naparovec

Trial Number	Current Stage	Drug Name-Sponsor	Viral Capsid	Gene Copy	Technique	Route	Notable Difference with VN
NCT00999609	Drug approved	Voretigene Naparovec Spark Theapeutics	rAAV2/2	RPE65	Gene augmentation	Subretinal	–
NCT03140969 NCT03913143 NCT03913130	Phase I/II Completed Phase II/III Recruiting Phase I/II active not recruiting	Sepofarsen/QR-110 ProQR technology	RNA based gene therapy	CEP290	RNA antisense oligonucleotide	Intravitreal	Different gene therapy technique all together, different gene
NCT02946879	Dose escalation trial Recruiting	AAV OPTIRPE65 MeiraGTx UK II Ltd	rAAV2/5	RPE65	Gene augmentation	Subretinal	Different viral capsid, intron-codon optimized gene delivered
NCT03872479	Phase I/II Recruiting	Edit-101 Allergan/Editas Medicine Inc–	rAAV2/5	CEP290	Gene editing with CRISPR/Cas	Subretinal	Different gene therapy all together, different gene
NCT00481546 NCT00821340 NCT00749957	Phase I active not recruiting Phase I Completed Phase I/II Completed	AAV2-CBSB-RPE65 University of Pennsylvania, Hadassah Medical Organization, Applied Genetics Technology Corp.	rAAV2	RPE65	Gene augmentation	Subretinal	Different promoter
NCT03920007	Phase I/II active not recruiting	SAR439483 Sanofi – Genzyme	rAAV2/5	GUCY2D	Gene augmentation	Subretinal	Different gene and viral capsid
NCT00643747	Phase I/II Completed	tgAAG76-rAAV 2/2. hRPE65p. hRPE65) University College of London	rAAV2/2	RPE65	Gene augmentation	Subretinal	Different promoter
NCT01496040	Phase I/II Completed	rAAV2/4.hRPE65 Nantes university Hospital	rAAV2/4	RPE65	Gene augmentation	Subretinal	Different promoter and viral capsid

Abbreviations: LCA, Leber's congenital amaurosis; AAV, adeno-associated virus.

all cases), and some other IRDs.^{38–40} *CRBI* is implicated in cellular adhesion, maintenance of apico-basal polarization, and cellular communication. It is considered critical for the structure and function of photoreceptors.⁴¹ In the developing retina, these proteins are present at the apex of the RPE, Muller cell, and photoreceptor inner segments which will eventually result in the junction between receptor cells and glial cells, creating the external limiting membrane. Characteristic ocular findings comprise macular thinning, pigmentation, relative preservation of para-vascular retinal pigment epithelium with increased retinal thickness along with altered laminar organization and loss of external limiting membrane.^{38,39} The occurrence of *CRBI* mutation diverges considerably in different geographic regions (between specific populations) because of the founder effect of genetic variation or consanguinity, and ranges as high as 17% in Spain to possibly 0% (absent) in India.

Gene replacement therapy for *CRBI* related retinopathies is challenging because of its large size of cDNA which approaches the limits of packaging capacity of AAV. However, techniques like vector and codon optimizations have facilitated the packaging of *CRBI* cDNA in adeno viral vectors with in vivo expression. The other challenge in *CRBI* gene therapy is simultaneous expression of the therapeutic vector in dissimilar cell types that demand CRB function.⁴²

CEP290 Gene (LCA 10 Locus)

Of the LCA cases, 15–20% harbor *CEP290* gene mutation, making it the most common gene involved.⁴³ *CEP290* is a centrosomal protein present at the connecting cilium of photoreceptors, connecting its outer and inner segments. Mutation of genes encoding ciliary protein leads to a spectrum disorder called ciliopathies.^{44,45} In addition to other features, *CEP290*-associated LCA patients typically suffer early onset of marked visual loss with corresponding receptor dysfunction.⁴⁴ Studies using optical coherence tomography have revealed that, even with profound dysfunction of cones, the foveal outer nuclear layer remains preserved up to the fourth decade of life, though thinner as compared to the perifoveal region.^{46,47}

After the advent of *RPE65* based gene therapy for LCA, there has been a substantial curiosity and encouragement to devise effective gene transfer methods for the treatment of *CEP290*-related retinal dystrophy. However, the barrier to its AAV mediated delivery of *CEP290* is the

size of its cDNA (~8 kb), which surpasses the maximum capacity of traditional vectors (~4.7–4.9 kb). Hence, use of the lentivirus (having larger packaging limit of 8–10 kb) vector may be advantageous.²³ Other viable interventions which are currently under investigation are antisense oligonucleotide, minigene transfer (truncated *CEP290* domain – mini*CEP290*^{580–1180}) and CRISPR/Cas9-based techniques.^{48,49}

RDH 12 Gene (LCA 13 Locus)

RDH 12 gene mutation accounts for about 4–5% of recessive LCA. *RDH12* gene (approximately 12kb length) is localised to chromosome 14q and consists of seven exons which encode enzyme retinol dehydrogenase-12. The enzyme is present in the inner segment of photoreceptors and has reductase activity which reduces the all-trans retinal to all-trans retinol.^{50,51} These mutations lead to reduced expression and activity of the enzyme, in turn affecting photopigment regeneration (Figures 1 and 2). The enzyme naturally protects against excess build-up of retinaldehyde and subsequent cytotoxicity. Loss of function of the gene is highly detrimental early in life, particularly for the macula.^{52,53} Fundus shows extensive atrophy of the RPE and retina. The unique fundus picture in *RDH12* mutation is its watercolour like appearance, where there is a clear demarcation pattern at the boundary between the preserved and affected retina, which enlarges with the advancement of disease and becomes less apparent at the end stage of the dystrophy.⁴⁰ There is loss of macular autofluorescence and typical peripapillary sparing is clearly evident on autofluorescence. Spectral domain OCT shows loss of normal foveal architecture and macular thinning.^{44,54,55}

Thompson et al⁵⁶ reported AAV-vector mediated *RDH 12* gene therapy by evaluating outcomes in wild-type and *RDH12*-knockout mice. Subretinal injection of an AAV2/8 vector produced recombinant human *RDH12* at the desired location without disrupting the structural integrity.

KCNJ13 (LCA 16 Locus)

Mutation of the *KCNJ13* gene (chromosome 2q37) also accounts for cases of autosomal recessive LCA 16. Mutations in the *KCNJ13* gene which encode the inwardly rectifying potassium channel Kir7.1, causing snowflake vitreoretinal degeneration and LCA. In the retina, Kir7.1 is localized exclusively in the RPE apical processes, where it controls retinal function and health. Light activation of photoreceptors reduces the RPE extracellular K⁺

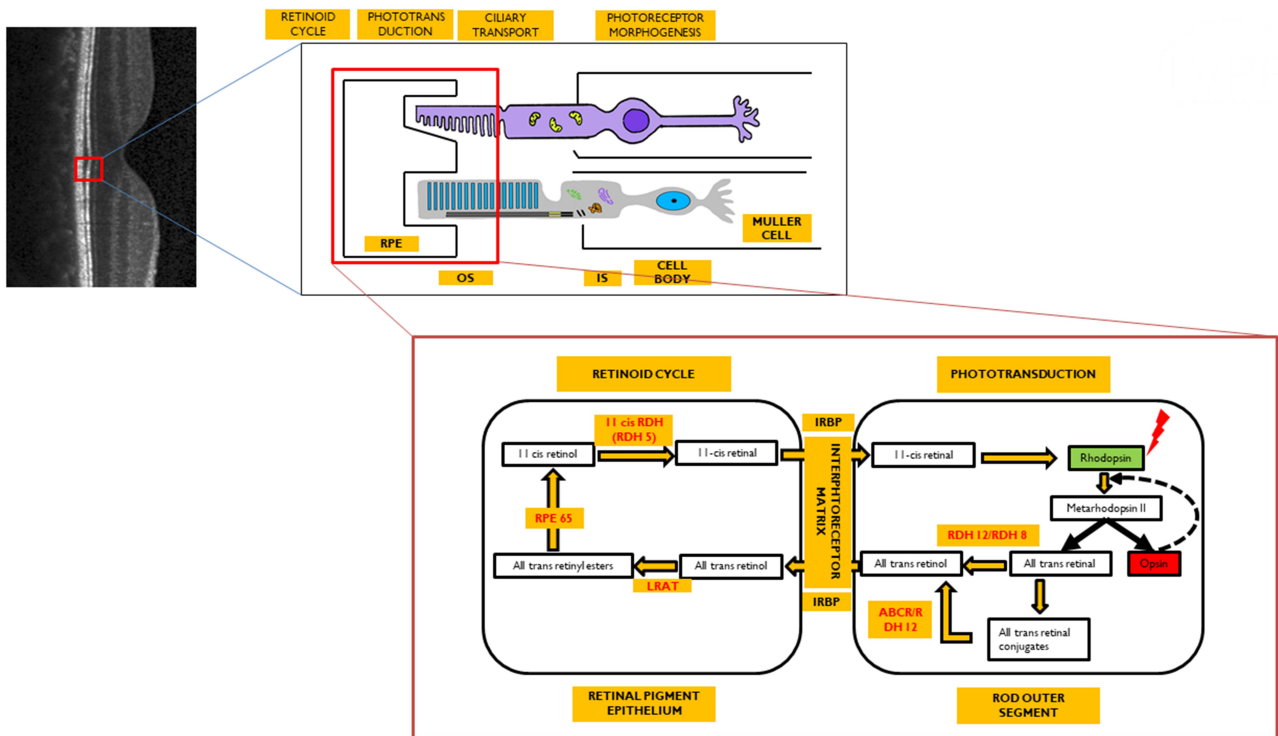


Figure 1 Image representing the visual cycle. Enzymes (in red) are localized to their site of action. Optical coherence tomography image (grey scale) represents normal structure of retina with its neural layers. Red colored square bracket is the localization of the retinal pigment epithelium (RPE)-photoreceptor complex within the retina which is further expanded to show that the photoreceptors (rods/cones) have two segments: outer segment (OS) and inner segment (IS) connected by a cilium. The OS interdigitates with the RPE, while the IS is connected to the cell body that relays further to the neural retina. The retinoid cycle occurs within the RPE cell, whereas the phototransduction occurs within the OS of the photoreceptor. Both of these are further expanded to reflect the sequential changes in the visual pigment after exposure to light.

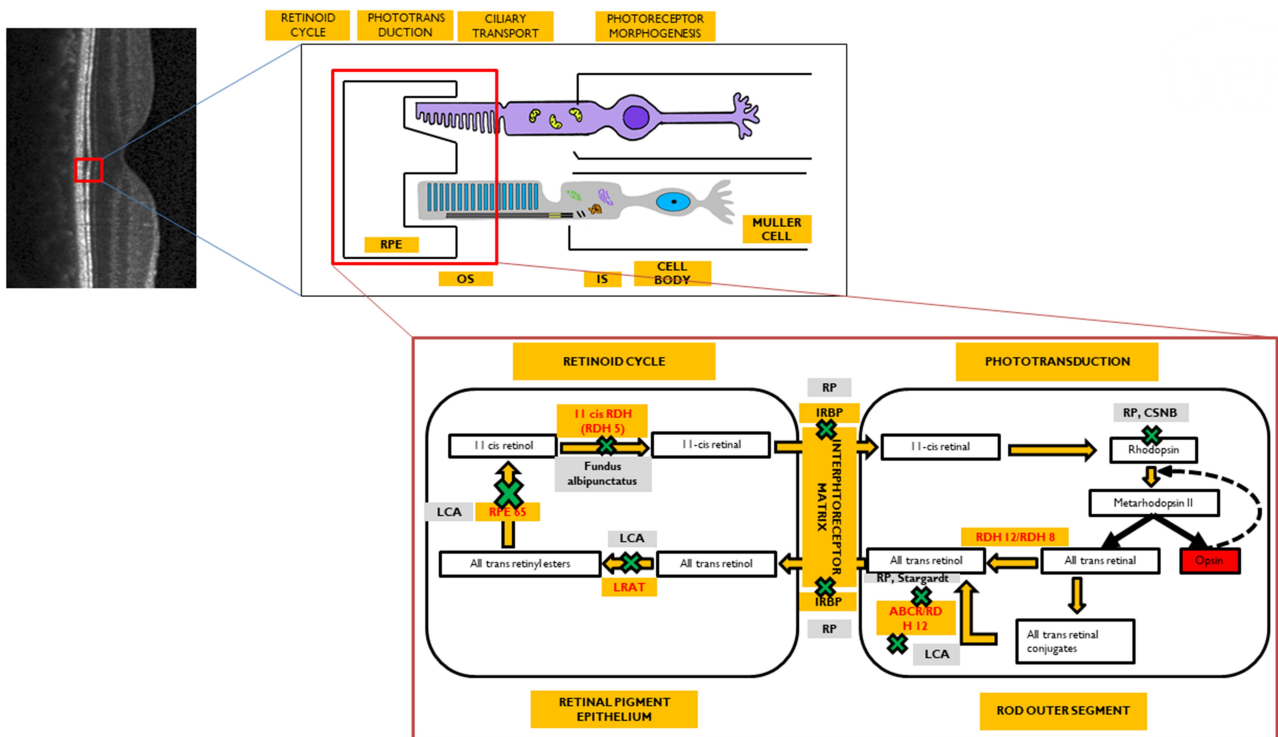


Figure 2 Phenotypic disorders corresponding to the enzyme defects shown in Figure 1. The various enzyme deficiencies can lead on to disorders like Leber's congenital amaurosis (LCA), Fundus Albipunctus, Retinitis pigmentosa (RP), Congenital stationary night blindness (CSNB), and Stargardt's disease, as indicated.

concentration. The conductance of the Kir7.1 channel increases when extracellular K^+ decreases and vice versa. Thus, KCNJ13 loss-of-function directly impacts K^+ buffering in the tight subretinal space and thereby alters photoreceptor function.⁵⁷ Retinal examination in these cases revealed arteriolar abnormalities, pigmentation of the retina in the macular region, and RPE abnormalities in one case,⁵⁸ along with visually significant cataract in another report.⁵⁹ In vivo studies for use of Lentivirus mediated gene therapy with this gene has suggested that membrane potential of RPE cells can be restored with 25% of normal protein expression. Accomplishing functional rescue in vivo could be less challenging, and residual mutant protein product is not expected to negatively influence functional outcomes.⁵⁷

RPE65 (LCA 2 Locus)

RPE65 mutation accounts for both LCA (3–16%) and recessive RP (~2%). The highest prevalence of *RPE65* variants is seen in Caucasian (16.5%) and Asian Indian populations (16%). These mutations are rarer in other populations. The gene is localized to chromosome 1p31 and consists of 31 exons. *RPE 65* codes for retinoid isomerohydrolase (65KD) expressed in RPE.⁶⁰ It is important for isomerization of photopigment and converts all-trans retinyl ester to 11-*cis* retinol in phototransduction (Figures 1 and 2). This isomerohydrolase along with LRAT (Lecithin: retinol acyl transferase) works continuously to regenerate visual pigments.⁶¹ Hence a mutation (*RPE65* deficiency) causes deficiency of 11 *cis*-retinal required for the beginning of a new visual cycle. Subsequently there is accumulation of pigment granules in RPE (Figures 1 and 2). The consequence is progressive retinal degeneration. *RPE65* mutation affects rod and cone photoreceptors differently. 11 *cis*-retinal deficiency in rod photoreceptors causes an early and profound nyctalopia. However, cone photoreceptors do have an alternate retinoid cycle pathway for generation of 11 *cis*-retinal which do not depend on *RPE65*, so cone mediated vision persists in younger patients.⁶² Generally, this mutation culminates in severe profound vision loss in infancy with mild, if any, nystagmus. Early stage of the disease shows bull's eye maculopathy, while atrophy, diffuse hyperpigmentation, and clumping of pigments generally appears very late in the course. Other associations include myopia and cataract. LRAT (a key enzyme in visual cycle, locus 14 LCA) deficiency also presents with similar phenotypes, though far less common compared to *RPE65*.²

Early Challenges for Gene Therapy with RPE 65 Gene

Seeing Light – From Mouse, Dog and Monkey to Man

Acland et al⁶³ reported success in gene replacement therapy in Briard dogs with retinopathy caused by a homozygous 4 base pairs deletion in *RPE65*. The authors used subretinal delivery of recombinant AAV2 vector that expressed the wild type canine *RPE65*cDNA regulated by the ubiquitous cytomegalovirus chicken beta actin promoter. Subretinal injection dose ranged from 1.5×10^8 to 4.5×10^{12} vector genomes (100–150 μ L). Injected eyes displayed a dramatically improved ERG response, pupillometry, and dark-adapted flash evoked cortical potentials. These results persisted up to 10 years following a single procedure.^{64,65} The results attained in the *Rpe65*^{-/-} Briard dogs produced deep exhilaration in the field of gene therapy owing to more human-like ocular anatomy and immune system of the animal subject. However, when examined serially over years, the outer photoreceptor nuclear layer showed progressive thinning in spite of gene therapy, indicating that the effects may be temporary. Further studies on dogs extended the usage of other serotypes of AAV like 1, 4, and 5.^{66–70} Afterward, both natural and knockout murine models were researched for gene replacement therapy with *RPE65* gene. The dose–response relationship was also demonstrated.^{71,72} Further, 17 normal cynomolgus monkeys, with human-like retina, were treated with single subretinal injection of rAAV2/2-CB^{SB}-*RPE65* vector. No systemic toxicity or grave ocular adverse effects on the retinal structure or function were noted, as confirmed at 3 weeks and 3 months post-treatment.

AAV2/2 mediated subretinal gene transfer in Briard dogs showed substantial morphological and functional salvage of photoreceptors, translating to improvement of functional ERG (around 20–30% of wildtype levels) and behavioral-based vision tests, particularly under photopic conditions.^{63,66,69} The stable and long-standing visual restoration was noted to be maintained at 4 years and even at 10 years of follow-up post-treatment in different studies.^{65,68,73,74}

Early Challenges for Humanizing the Progress in Gene Therapy

These early experimental trials were reassuring in terms of safety and efficacy, paving the way for human

intervention. Apart from dosage-related issues, a major challenge in humans was the heterogeneity of mutations; which obfuscated the genetic and visual correlation. Another noteworthy difference that later arose between the different human trials involved the promoter driving the expression of *RPE65*; a human *RPE65* promoter was used by one group,⁷⁵ whereas others used a CAG promoter (changed form of ubiquitous chicken β actin promoter).^{76–78} Though an ubiquitous promoter like CAG offers a more robust and stronger expression pattern, it shows a non-specific cell expression profile other than RPE cells. In contrast, the human *RPE65* promoter drives RPE-specific expressions of the transgene shown in pre-clinical studies. Even though the CAG promoter expresses genes stronger than the human *RPE65* promoter, enough transgene expression was driven by the latter to salvage the treated canine phenotypes.^{69,79} Robust outcomes were also reported after use of the CAG promoter in multiple parameters (discussed later).^{76,77,80,81} Although these trials (Table 2) established the stability, safety and efficacy persisting up to no less than 3 years following treatment, an age-dependent effect of the treatment remained contentious with contradictory conclusions.^{80–82} Cideciyan et al,⁸³ in their human study, concluded that, even with therapy, the outcomes followed the anticipated natural history. Surprisingly, they also showed dissimilarities between canine and human models, used for preclinical experiments. Cideciyan et al also reported that rod recovery in humans remained grossly impaired following *RPE65* gene therapy, despite improved visual sensitivity. Thus it is obvious that there were several variables which the early human trials needed to account for.⁸⁴

The Choice of Subretinal Delivery

Gene therapy can be employed for ocular usage for the following reasons: 1) The eye is an immune privileged site, 2) Miniscule quantities of vectors are required to achieve therapeutic targets, 3) It permits local treatment without the need of intravenous dosing, and 4) The safety and effect can be supervised by non-invasive tests. However, compared to other parts of the body, several barriers that shield the eye from toxicants (anatomically and physiologically) also make delivery of drugs difficult.^{85,86} For targeted retinal gene therapy, the possible routes could be intravitreal, suprachoroidal, or subretinal drug delivery (Figure 3). Subretinal drugs or genes have direct access to cell membranes of photoreceptors and RPE cells, making it a good location for drug delivery,

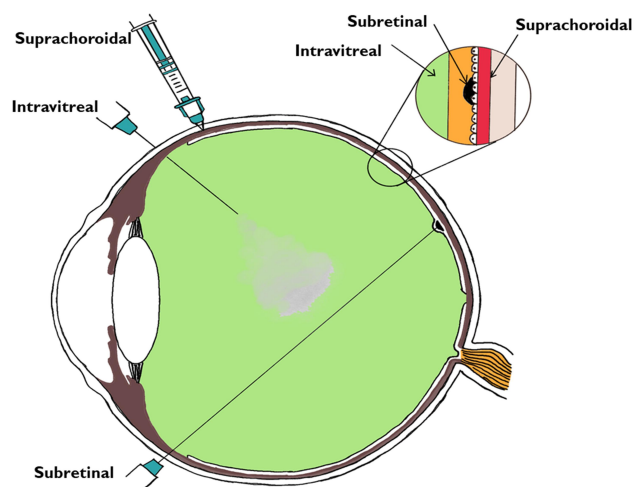


Figure 3 Various routes of vector delivery to the eye. The intravitreal, subretinal, and suprachoroidal spaces are shown in the magnified inset corresponding to the sites of the delivery of the drug.

exclusively in patients with diseases that mainly affect RPE cells and photoreceptors.⁸⁷ Intravitreal injections on the other hand face the whole neural retina as a potential barrier and are useful when the target for therapy lies in the inner retina or the ganglion cell layer. A higher dosage of drug will be needed while treating with intravitreal drug injection. However, in comparison to subretinal delivery, intravitreal injection is an office-based procedure with minimal requirement of training.⁸⁸ The subretinal route offers a direct route with more specific localization and a lower dose is needed. The subretinal space itself may be approached in multiple ways.^{88–91} AAV mediated subretinal delivery of genes has been found to be safe by a large number of studies,^{75,–76,–79,–80,–92–94} although procedure-related potential side-effects can occur. The complications reported with subretinal surgery include macular hole, retinal tears, retinal detachment, endophthalmitis, glaucoma, cataract, etc. There are also concerns regarding the limited locale of retina benefitting from gene therapy, with the improved area corresponding only to the area of the subretinal bleb formed during subretinal delivery. This has been confirmed using dark adapted perimetry. Another concern is photoreceptor degeneration due to a subfoveal bleb.⁹⁵

The other novel mode of drug delivery is the suprachoroidal approach. The suprachoroidal space (nominal thickness of 35 μm) is a potential space found between the sclera and choroid, and, under physiologic conditions (Figure 3), it is mostly collapsed due to the intraocular pressure and fibers that attach the sclera to the

choroid. Unlike the subretinal route, the suprachoroidal approach does not require retrobulbar anesthesia or pars plana vitrectomy, and avoids its complications while offering a greater surface area coverage of the posterior segment of the eye. However, the suprachoroidal space is not anatomically immune privileged and the presence of choriocapillaris causes rapid clearance of the administered drug hindering effective transduction of the retina.⁹⁶

The Choice of AAV Vector

AAV, a parvovirus, has a protein capsid surrounding a DNA genome (single stranded) approximately 4.8 kb in size. The genome contains genes responsible for replication, capsid, and assembly. Through usage of three promoters, alternative translation starts sites, and differential splicing, at least nine gene products are constructed by the virus. The coding sequences are bordered by inverted terminal repeats (ITRs) that are essential for genome replication and packaging. On the other hand, recombinant AAV, a protein-based nanoparticle, lacks viral DNA, can pass through the cell membrane, and eventually deliver genes into the nucleus. In the absence of replication proteins, rAAV forms circular concatemers which accumulate in the nucleus of transduced cells as episomes.⁹⁷ The peak gene expression is usually reached by around 4–6 weeks in AAV mediated gene therapy. There is no integration between host and episomal DNA, therefore the cargo gene gets diluted over time following mitoses. This ultimately results in diminished gene expression over time, the rate depending on cellular replication. In the perspective of the RPE cells which have very low turnover rates, rAAV is therefore an ideal vector for certain genes.

However, an essential contemplation for using the rAAV vector is the maximum packaging limit, which is less than other vectors like Lentivirus. In the beginning, packaging size under 5 kb was considered adequate.⁹⁸ As discussed before, Lentivirus has been used for gene therapy for LCA loci other than LCA 2 (*RPE65*), like loci 1, 10, and 16. Other possible non-viral approaches for gene delivery include bacteria or plasmid based, or others like nanoparticles, electroporation of nucleic acids, antisense oligonucleotides (LCA 10), and liposomes, etc. Efforts in producing rAAV vectors with higher packaging limits resulted in lower viral production yields.⁹⁹ After delivery of single-stranded AAV-delivered transgenes to the nucleus, it needs to be transformed into a double-stranded form, a rate limiting step at the commencement of transgene expression.¹⁰⁰ A substitute is the use of self-

complementary AAV (scAAV). Here the single-stranded genome can complement itself to produce its double-stranded form.^{100,101} Though gene expression becomes faster this way, the packaging capacity can drop significantly to around 3 kb in this strategy. scAAV2,¹⁰² scAAV5,¹⁰³ and scAAV8¹⁰⁴ have the advantage of faster onset of expression in retinal cells, though the pattern of expression is identical to that of single-stranded vectors.

An additional constraint to the onset and extent of gene expression is the degradation of AAV vector occurring through phosphorylation of surface-exposed tyrosine residues that enhance proteasome-mediated degradation. A mutation of these tyrosine residues to phenylalanine enables vectors to partially circumvent this pathway leading to increased transduction after subretinal, intravitreal, and intravenous administration compared to their naturally occurring counterparts. Rational design and library selection strategies are considered to be quite useful for achieving improved function of AAV in the retina.¹⁰⁵

The factors that decide the choice of AAV factor for gene transfer therefore are: 1) targeted cell/tissue types; 2) the target gene and its safety profile; 3) the selection of route of delivery; and 4) the promoter sequences utilized. AAV matches these for subretinal delivery being very stable to wide pH and temperature changes.¹⁰⁶ However, the concentration at which it can be formulated presently is limited to approximately 5×10^{13} particles per mL, and higher doses pose the risk of inducing inflammatory reactions.¹⁰⁷

Promoters and Enhancers for Viral Vectors

Gene therapy requires use of strong ubiquitous promoters such as the cytomegalovirus (CMV) or the chimeric chicken β -actin CMV enhancer and promoter. Other promoters like the human *RPE65* promoter and other forms of the chicken β -actin (CB) promoter (discussed later) have also been utilized. The choice of promoter is also dependent on the gene and the human cell intended to be transduced. Following viral vector transduction and insertion of genetic material into the target cell, specific promoters permit for the transcription and construction of the anticipated transgene only in designated target cells. By restricting the expression of the gene to a specific target cell type (eg, RPE, rods, or cones), they avert undesirable side-effects from the transgene production. Addition of promoters and enhancers in AAV mediated gene therapy

is necessitated because of their absence in the recombinant serotypes. Robust promoters also diminish the minimum dose of viral genomes (and related complications) by augmenting the gene expression. However, the size of the promoter can be a concern as it limits the gene base pairs that can be carried by the drug (discussed earlier).

RPE-specific expression can be driven by the use of *RPE65* promoters. RPE specific promoters, the target of LCA gene therapy, include the human *RPE65* promoter, NA65 promoter (optimized promoter), VMD2, and Synpiii promoters.¹⁰⁸ With these cell-specific promoters, only the cells that typically recognize those particular promoters will produce the transgene product. Although other cell types may be transduced by the viral vector, without recognition of the promoter sequence, the genetic material is not transcribed and the protein is not produced in those cells. As mentioned before, human *RPE65* and CAG promoters have been extensively employed for LCA. Theoretically the latter has a more robust gene expression profile, but is not specific for the human RPE cells. In clinical trials, the use of human RPE6 promoter has also resulted in satisfactory gene expression.

Phase I/II Clinical Trials Early Results

Clinical trials for LCA2 began in 2007 following success in preclinical studies (Table 2). AAV-RPE65 therapy had already been shown to be safe in canine and primate models, as discussed before.^{109,110} The initial results were stated in 2008 by two independent groups. The group from University College London and Moorfield's eye hospital (MEH) reported results of treatment of three human subjects with an AAV2.RPE65 construct whose expression was controlled by the human *RPE65* promoter. The drug was filled in a buffered saline solution at a titer of 1×10^{11} vector particles per milliliter and frozen in 1-mL aliquots at -70°C . Up to 1 mL of the vector was introduced, after detachment of approximately a third of the retina, into the subretinal space using a subretinal canula without any serious adverse events. Though statistically significant improvement in vision or visual fields was not seen in any patient, one subject showed significant functional improvement in dark-adapted perimetry and microperimetry. Subjective improvement in visual mobility was also noted in that patient.⁷⁵

The consortium, led by the Children's Hospital of Philadelphia (CHOP), including the Telethon Institute

of Genetics and Medicine (TIGEM), University of Pennsylvania (UPENN), and the Second University of Naples (SUN), also described the outcomes from treatment of three subjects aged between 19–26 years with AAV2.hRPE65v2 vector.⁷⁶ A surfactant was used here to avert the loss of the vector in containments. A subretinal injection of 1.5×10^{10} vector genome of AAV2.hRPE65v2 in 150 μL volume of phosphate-buffered saline was performed, thereby creating a confined dome shaped retinal detachment. The subretinal bleb was seen to resolve after 14 hours of surgery. No adverse event related to viral dissemination was recorded. An asymptomatic macular hole was noted in one patient on postoperative day 5, possibly related to a pre-existing epiretinal membrane. Remarkable improvements were seen in pupillary light responses in all cases. Three times increase in light sensitivity was noted in each treated eye, and even surpassing that of the fellow – previously better – eye. All three subjects revealed an improvement in dim light vision as early as 2 weeks after surgery. A drift toward enlarged visual field areas in each of the three patients was observed.

Several months later, a group from UPENN and the University of Florida (UFL) also stated comparable results.^{77,111} In that study, three subjects (aged between 21–24 years) were injected with subretinal AAV2-CBSB-hRPE65 containing 5.96×10^{10} viral genome in 150 μL , in the areas outside the macula in two subjects and within the macular area in the third.¹⁰⁹ No local or systemic adverse events were documented. Dark adapted perimetry sensitivities improved in all three eyes. A significant increase in cone and rod sensitivities were demonstrated. However, there was no improvement in visual acuity compared to the baseline. The authors appraised that nearly normal sensitivity to light was reinstated in specific retinal areas, even though the rod recovery time was still higher than normal (8 vs 1 hour).

Long-Term Results

At the beginning of 2009, extended results from these early phase studies were issued. Collectively the reports suggested an age dependent response to gene therapy in LCA with functional improvement in treated eyes.

Dose Escalation Trials: The CHOP-TIGEM-UPENN-SUN group assessed the retinal and visual function in 12 patients (aged 8–44 years) with *RPE65*-mutation related LCA up to 2 years.⁸⁰ The subjects were given either of the three doses, ie, 1.5×10^{10} (low), 4.8×10^{10} (medium), or

1.5×10^{11} (high) vector genomes delivered in 150 or 300 μL solution. The previous surgical procedure was slightly modified by including surgical peeling of epiretinal membranes if present. Injections below the macula were avoided in three patients with macular atrophy. High dose injections were given after buttressing fovea with perfluoro-octane liquid (aspirated subsequently).⁸⁰ The treatment was well tolerated in all patients showing a continuous enhancement in vision both subjectively and objectively. Pupillary light responses improved by at least 2 log units in all patients when measured using pupillometry (amplitude and velocity of constriction) as early as 7 days following injection. There was also a corresponding increase in full-field threshold sensitivities. Ambulatory vision was attained by children. An 8-year old patient attained near normal levels of light sensitivity.

Additional reports with an up to 3-year follow-up period revealed maximal improvement in vision within the initial 6 months of therapy and later stabilized.^{82,112} Functional MRI measurements revealed functioning in the visual pathway in previously long-standing blind eyes. This indicated a greater elasticity in the visual pathway contrary to previous notions.¹¹³

The UPENN/UFL group in their longer-term results described outcomes in 15 subjects, all less than 30 years of age, with the AAV2 vector. The investigators evaluated different doses and injection strategies in five cohorts (Table 2). The surgical adverse events included retinal detachment in one subject requiring additional intervention and non-resolving effusion of the choroid in a second patient. Systemic toxicity was not noted. An improvement of visual function, though to variable degree, was noted in all subjects. Photoreceptors became significantly more sensitive in the treated regions of the retina as early as 3 months post-injection and were sustained through 3 years. Eyes with the lowest visual acuity at baseline displayed the largest improvement in mean visual acuity.

There have been other such trials in the last decade. Two additional publications, one each from Israel and France, describe the outcomes in peer reviewed journals. The immediate results from the Israel study group stated improvement in function as early as 2 weeks in the treated retinal area (Table 2).¹¹⁴ In their report of a phase I/II study performed at Nantes University Hospital, the French study group described the safety of AAV mediated RPE 65 treatment for LCA. However, the improvements in visual function were variable (Table 2).¹¹⁵

Phase II Clinical Re-Administration Trials – A Step Forward

Phase I/II studies reported the success of unilateral injections. It was unclear whether treatment of the fellow eye secondarily would yield any benefit. The apprehension was that the first injection of virus might serve a role similar to vaccination. Hence, an immunogenic response might also cause injury to the primarily injected eye. Therefore, re-administration studies were first performed in large animal models before testing in the human clinical trial subjects. Sequential subretinal delivery of a high dose (1.5×10^{11} vector genome) of AAV2-hRPE65v2 was tested in both canine models, ie, six Briard (affected) dogs, besides four unaffected non-human primates that had been formerly exposed systemically to research grade AAV. It was found to be a safe procedure with a lack of systemic and ocular toxicity for both eyes. This was followed by initiation of human re-administration studies.¹¹⁶

In human trials, re-administration of vector was done in the fellow eye of three adults with LCA due to *RPE65* gene mutation 1.7–3.3 years after their initial therapy. The area targeted in the re-administration was the region which had sufficient viable retinal cells. All subjects received 1.5×10^{11} μg in 300 μL for the re-administration study in their previously un-injected eye. The oldest participants were registered foremost. Subjects were assessed every week and a 3-months stagger was maintained between enrolments of each of these patients. There were no toxic immune responses in any of the subjects. After injection, the “contralateral” eyes showed functional improvement in multiple aspects. The results reflected an age effect whereby the younger individuals exhibited larger gains than the older individual.¹¹⁷

In continuation of a previous early phase clinical study, a dose of AAV2-hRPE65v2 (1.5×10^{11} μg in 300 μL) was administered to formerly un-injected eyes of 11 subjects.¹¹⁸ There were no AAV related adverse events. However, cataract formation occurred in three patients, cataract in two cases, while one case developed endophthalmitis. Compared with baseline, results of 10 subjects displayed developments in sensitivity of light and mobility as early as 1 month, that sustained till 3 years.¹¹⁸

Orphan Drug Status

VN received Orphan Drug designation by US FDA on June 24, 2008, which provided incentives to assist and encourage its development. On April 2, 2012, orphan designation (EU/3/12/981) was granted by the European Commission to

Alan Boyd Consultants Ltd, UK, for AAV2.RPE65 gene therapy for treating LCA. Spark Therapeutics Ireland Ltd later acquired the sponsorship in 2017.

Phase III Clinical Trial

Based on the results of Phase I and II trials described above, a Phase III (“pivotal”) trial for *RPE65* gene augmentation therapy was started at CHOP and the University of Iowa. Thirty-one patients were registered and randomly allocated to intervention (n=21) or control (n=10) groups between November 15, 2012, and November 21, 2013. Individuals with age ≥ 3 years with an established diagnosis of biallelic *RPE65* mutations were enrolled if a) bilateral eyes had visual acuity of $\leq 20/60$ or visual field < 20 degrees in any meridian, or both, b) they had enough viable retinal cells as evidenced by retinal thickness on SD-OCT (> 100 microns within the posterior pole), fundus photography, and clinical evaluation; and c) they were able to accomplish a standardized multi-luminance mobility test (MLMT) within the luminance range assessed, but incapable to pass the lowest luminance level tested of 1 lux. Primary intervention was bilateral subretinal injection of AAV2.hRPE65v2 at 1.5×10^{11} μg in eligible individuals. Randomization of subjects was done to intervention or control group (2:1, respectively). Subjects in both the arms were assessed at the same time intervals for 1 year, and then the control group was crossed to the intervention group. Subjects in the control group, meeting all the inclusion criteria, received VN (bilateral) 1 year after their baseline evaluations.¹¹⁹

To measure results, subjects were requested to navigate a standardized course (discussed later) under seven different progressing illuminations commonly met during the course of a day, “starting from 1 lux (like that of a moonless summer night) to 400 lux (equivalent to a brightly lit office environment)”. The course involved navigation of a path defined by large black arrows on the floor avoiding placed obstacles. A change in multi-luminance mobility test score of ≥ 2 , from baseline to year 1, was considered a meaningful benefit in terms of functional vision.¹²⁰

The primary measure was defined as bilateral MLMT performance gain at year 1. Secondary measures were white light Full field light sensitivity threshold (FST) testing at 1 year, taking averaged value of two eyes, and averaged change of best-corrected visual acuity over both eyes. FST testing assesses night blindness (rod photoreceptors function) predominantly affected by *RPE65* mutations. Kinetic and static perimetry, visual function questionnaire, contrast sensitivity, pupil light

sensitivity, and domestic mobility assessments were also performed. Safety assessments included immunology testing apart from other standard tests. At 1 year, the mean change in bilateral MLMT score was 1.8 (SD=1.1) light levels in the intervention group, as opposed to 0.2 (1.0) in the control group. No control participant could clear MLMT at 1 lux (lowest level), however 13/20 treated subjects did. This was a very strong indicator of efficacy. Minimal inflammation, temporarily increased intraocular pressure, and retinal tears were the most commonly documented adverse effects.¹¹⁹

Mobility Tests as an Indicator of Efficiency

With time, subjects with untreated *RPE65* related LCA lose perception of light at any illumination, restricting independent navigation in early life. Since the traditional metrics of mobility do not account for ambient illumination while judging accuracy and speed of navigation, the MLMT was developed. This test is specifically designed to quantify and ascertain outcomes focused on various facets of vision, like field, acuity, and light sensitivity.¹²¹ For visually impaired individuals, the test also divides between higher and lower performers. Even young children (4 years) navigated the standardized course precisely and at a reasonable pace. Most important, the MLMT is a validated test found to be both reliable and reproducible.

Safety Concerns

VN, unlike most FDA-approved injectable treatments, necessitates a surgical procedure for administration. The FDA reviewers analyzed 41 subjects with VN intervention taking into account safety results of both Phase I and Phase III studies. The various treatment-related ocular adverse events, during the follow-up period spanning between 1– 6 years, included maculopathy (5%), macular holes (7%), retinal tears (10%), raised intraocular pressure (IOP) (15%), and cataract (20%). In general, 66% (21) of treated subjects experienced one or more ocular adverse events, mostly mild or moderate, and resolved, primarily ascribed to the surgical procedure.¹¹⁹ However, two (5%) study participants developed irreversible loss of vision, one due to raised IOP related optic atrophy, and the other because of macular atrophy secondary to the procedure. A 15-year follow-up study to evaluate long-term safety and efficacy is ongoing.

Gene Cassette of Voretigene Neparvovec

VN, as developed by Spark therapeutics, uses the rAAV2 capsid. The structure of rAAV gene cassettes is bounded

at its ends by two inverted terminal repeats (ITRs). The ITRs of rAAV are the only palindromic repeats carried over from the wild type AAV. These ITRs are required as they allow for episomal concatemerization, and thus action of the drug. However, the ITRs of the AAV serotype lack the promoter and the termination function, which makes the presence of promoters and enhancers necessary. Therefore, following the 5' ITR, a promoter sequence is incorporated in the drug. In the case of VN, it is the ubiquitous CAG promoter (consisting of a CMV enhancer and a chicken beta actin promoter). The job of the promoter and enhancer sequence here is to stabilize and increase the gene expression and transcription. This is followed by the chicken beta actin exon and intron which are necessary for gene regulation. Following this the next portion of the gene cassette consists of the *RPE65* DNA which is the dysfunctional target in the case of LCA. In VN, this DNA is a complimentary DNA representing the human *RPE65* gene, thus referred to as hRPE65v2. Following the DNA target, the rAAV gene cassette also requires a polyadenylation sequence. The polyadenylation sequence is necessary for the stability and expression of the gene product. In the case of VN, this sequence is derived from the bovine growth hormone. Lastly, the gene rAAV gene cassette contains the 3'ITR. VN, therefore, pharmacologically reads as ITR.CAG.RPE65v2.bGHpola.ITR gene sequence harbored in a rAAV2 capsid. Other similar constructs being evaluated for gene therapy for LCA are listed in Table 3.¹²²

FDA Approval

On October 12, 2017, a committee dedicated to cell-tissue-gene therapies discussed the efficacy and safety of VN. Approval was given in December 2017 after all 16 members voted in favor of the drug. Two-year outcomes of MLMT were taken into account to judge the efficacy of VN (Luxturna). The approval was given for patients with retinal dystrophy due to *RPE65* mutations.¹⁶ It is the first FDA approved gene replacement therapy that uses AAV vectors. The drug was priced at US\$425,000 for each eye.

EU Approval

The European Commission (EC) approved VN on November 23, 2018 as a one-time gene replacement therapy for *RPE65* mutation related retinal dystrophy, provided some retinal function was present. The EC decision was based on judgment of the committee that

evaluates medical products intended for humans. In early 2018, Spark Therapeutics and Novartis entered into an agreement for marketing VN in the rest of the world.¹²³

Conclusion

Gene therapy for LCA with VN has matured to a level of evidence-based success that inspires hopes for other IRDs and non-ocular disorders. However, it also brings with itself new challenges that need immediate addressal. At the level of regional groups, these include individualizing patterns of genetic defects in different ethnicities, training retinal surgeons and ocular geneticists, provision of appropriate visual tests for monitoring, and economical aspects of gene therapy. For researchers, the options of routes of drug delivery is still open ended, especially with the advent of the suprachoroidal approach. Subretinal delivery is sophisticated and not an office-based procedure. Further, due to the involvement of multiple genes, the approach to each genotype needs to be refined, and gene augmentation may not be the only solution. Specifically, in vivo gene editing is likely to find a role in specific genotypes of LCA. While AAV has currently become the approved vector for subretinal gene delivery, its small capacity is a hindrance and the capacity for transduction can be improved further. The perfect promoter-gene combination is yet elusive, and the size of promoter can be decreased to allow more space for the gene cDNA. Some long-term studies have shown visual and structural decline after early improvement, which makes concerns over appropriately timed re-administration in a previously treated eye a reality. As retinal imaging continues to evolve with advances like adaptive optics, outcome measures that are simpler or universally available as against the MLMT may be more pertinent. At the level of the patient, identification of ideal candidates for gene therapy needs to be done very cautiously, with emphasis on the stage of LCA, availability of functioning photoreceptors, and choice of retinal area for sub-retinal delivery. Judicious use of other rehabilitative therapies simultaneously with gene therapy is important, especially in the perspective of patient expectations of outcomes.

Acknowledgments

Hyderabad Eye Research Foundation, India, provides research support to SP, BT, RN and SJ. The authors thank Dr Sohini Mandal, MD for help with figures.

Disclosure

No author has any conflicts of interest to disclose.

References

- Sahel JA, Marazova K, Audo I. Clinical characteristics and current therapies for inherited retinal degenerations. *Cold Spring Harb Perspect Med.* 2014;5(2):a017111. doi:10.1101/cshperspect.a017111
- Cremers FPM, Boon CJF, Bujakowska K, et al. Special issue introduction: inherited retinal disease: novel candidate genes, genotype-phenotype correlations, and inheritance models. *Genes (Basel).* 2018;9(4):215. doi:10.3390/genes9040215
- Gregory-Evans K, Pennesi ME, Weleber RG. Retinitis pigmentosa and allied disorders. In: Ryan SJ, editor. *Retina.* Elsevier; 2013:761–835.
- Leber T. Ueber retinitis pigmentosa und angeborene amaurose. *Graefes Arch Clin Exp Ophthalmol.* 1869;15(3):1–25. doi:10.1007/BF02721213
- Perrault I, Rozet JM, Gerber S, et al. Leber congenital amaurosis. *Mol Genet Metab.* 1999;68(2):200–208. doi:10.1006/mgme.1999.2906
- Weleber RG, Michaelides M, Trzupke KM, et al. The phenotype of severe early childhood onset retinal dystrophy (SECORD) from mutation of RPE65 and differentiation from leber congenital amaurosis. *Invest Ophthalmol Vis Sci.* 2011;52(1):292–302. doi:10.1167/iovs.10-6106
- Anderson WF, Blaese RM, Culver K. The ADA human gene therapy clinical protocol: points to consider response with clinical protocol. *Hum Gene Ther.* 1990;1(3):331–362. doi:10.1089/hum.1990.1.3-331
- Deakin CT, Alexander IE, Kerridge I. Accepting risk in clinical research: is the gene therapy field becoming too risk-averse? *Mol Ther.* 2009;17(11):1842–1848. doi:10.1038/mt.2009.223
- Bank A. Human somatic cell gene therapy. *Bioessays.* 1996;18(12):999–1007. doi:10.1002/bies.950181210
- Mathews QL, Curiel DT. Gene therapy: human germline genetics modifications-assessing the scientific, socioethical, and religious issues. *South Med J.* 2007;100(1):98–100. doi:10.1097/SMJ.0b013e31802e645f
- Gonçalves GAR, Paiva RMA. Gene therapy: advances, challenges and perspectives. *Einstein (Sao Paulo).* 2017;15(3):369–375. doi:10.1590/S1679-45082017RB4024
- Zeng Y, Takada Y, Kjellstrom S, et al. RS-1 gene delivery to an adult Rsh knockout mouse model restores ERG b-wave with reversal of the electronegative waveform of X-linked retinoschisis. *Investig Ophthalmol Vis Sci.* 2004;45(9):3279–3285. doi:10.1167/iovs.04-0576
- Han Z, Conley SM, Naash MI. Gene therapy for stargardt disease associated with ABCA4 gene. *Adv Exp Med Biol.* 2014;801:719–724.
- Cashman SM, Gracias J, Adhi M, Kumar-Singh R. Adenovirus-mediated delivery of factor H attenuates complement C3 induced pathology in the murine retina: a potential gene therapy for age-related macular degeneration. *J Gene Med.* 2015;17(10–12):229–243. doi:10.1002/jgm.2865
- Matet A, Kostic C, Bemelmans AP, et al. Evaluation of tolerance to lentiviral LV-RPE65 gene therapy vector after subretinal delivery in non-human primates. *Transl Res.* 2017;188:40–57. doi:10.1016/j.trsl.2017.06.012
- FDA. *FDA Briefing Document: Advisory Committee Meeting. October 12, 2017. BLA 125610 (Voretigene Neparvovec).* FDA; 2017.
- Hampson G, Towse A, Pearson SD, Dreitlein WB, Henshall C. Gene therapy: evidence, value and affordability in the US health care system. *J Comp Eff Res.* 2017;7(1):15–28. doi:10.2217/ceer-2017-0068
- Takkar B, Bansal P, Venkatesh P. Leber's congenital amaurosis and gene therapy. *Indian J Pediatr.* 2018;85(3):237–242. doi:10.1007/s12098-017-2394-1
- Perrault I, Rozet JM, Gerber S, et al. Spectrum of retGC1 mutations in Leber's congenital amaurosis. *Eur J Hum Genet.* 2000;8(8):578–582. doi:10.1038/sj.ejhg.5200503
- Wimberg H, Lev D, Yosovich K, et al. Photoreceptor guanylate cyclase (*GUCY2D*) mutations cause retinal dystrophies by severe malfunction of Ca²⁺-dependent cyclic GMP synthesis. *Front Mol Neurosci.* 2018;11:348. doi:10.3389/fnmol.2018.00348
- Jacobson SG, Cideciyan AV, Peshenko IV, et al. Determining consequences of retinal membrane guanylyl cyclase (RetGC1) deficiency in human Leber congenital amaurosis en route to therapy: residual cone-photoreceptor vision correlates with biochemical properties of the mutants. *Hum Mol Genet.* 2013;22(1):168–183. doi:10.1093/hmg/dds421
- Boye SE. Leber congenital amaurosis caused by mutations in *GUCY2D*. *Cold Spring Harb Perspect Med.* 2014;5(1):a017350. doi:10.1101/cshperspect.a017350
- Haire SE, Pang J, Boye SL, et al. Light-driven cone arrestin translocation in cones of postnatal guanylate cyclase-1 knockout mouse retina treated with AAV-GC1. *Invest Ophthalmol Vis Sci.* 2006;47(9):3745–3753. doi:10.1167/iovs.06-0086
- Mihelec M, Pearson RA, Robbie SJ, et al. Long-term preservation of cones and improvement in visual function following gene therapy in a mouse model of leber congenital amaurosis caused by guanylate cyclase-1 deficiency. *Hum Gene Ther.* 2011;22(10):1179–1190. doi:10.1089/hum.2011.069
- Boye SE, Boye SL, Pang J, et al. Functional and behavioral restoration of vision by gene therapy in the guanylate cyclase-1 (GC1) knockout mouse. *PLoS One.* 2010;5(6):e11306. doi:10.1371/journal.pone.0011306
- Hidalgo-de-Quintana J, Evans RJ, Cheetham ME, et al. The Leber congenital amaurosis protein AIPL1 functions as part of a chaperone heterocomplex. *Invest Ophthalmol Vis Sci.* 2008;49(7):2878–2887. doi:10.1167/iovs.07-1576
- Sohocki MM, Bowne SJ, Sullivan LS, et al. Mutations in a new photoreceptor-pineal gene on 17p cause Leber congenital amaurosis. *Nat Genet.* 2000;24(1):79–83. doi:10.1038/71732
- Liu X, Bulgakov OV, Wen XH, et al. AIPL1, the protein that is defective in Leber congenital amaurosis, is essential for the biosynthesis of retinal rod cGMP phosphodiesterase. *Proc Natl Acad Sci USA.* 2004;101(38):13903–13908. doi:10.1073/pnas.0405160101
- Tan MH, Mackay DS, Cowing J, et al. Leber congenital amaurosis associated with AIPL1: challenges in ascribing disease causation, clinical findings, and implications for gene therapy. *PLoS One.* 2012;7(3):e32330. doi:10.1371/journal.pone.0032330
- Dharmaraj S, Leroy BP, Sohocki MM, et al. The phenotype of leber congenital amaurosis in patients with AIPL1 mutations. *Arch Ophthalmol.* 2004;122(7):1029–1037. doi:10.1001/archophth.122.7.1029
- Aboshiha J, Dubis AM, Spuy J, et al. Preserved outer retina in AIPL1 Leber's congenital amaurosis: implications for gene therapy. *Ophthalmology.* 2015;122(4):862–864. doi:10.1016/j.ophtha.2014.11.019
- Testa F, Surace EM, Rossi S, et al. Evaluation of Italian patients with leber congenital amaurosis due to AIPL1 mutations highlights the potential applicability of gene therapy. *Invest Ophthalmol Vis Sci.* 2011;52(8):5618–5624. doi:10.1167/iovs.10-6543
- Dryja TP, Adams SM, Grimsby JL, et al. Null RGRIP1 alleles in patients with Leber congenital amaurosis. *Am J Hum Genet.* 2001;68(5):1295–1298. doi:10.1086/320113

34. Gerber S, Perrault I, Hanein S, et al. Complete exon-intron structure of the RPGR-interacting protein (RPGRIP1) gene allows the identification of mutations underlying Leber congenital amaurosis. *Eur J Hum Genet.* 2001;9(8):561–571. doi:10.1038/sj.ejhg.5200689
35. Li T. Leber congenital amaurosis caused by mutations in RPGRIP1. *Cold Spring Harb Perspect Med.* 2014;5(4):a017384. doi:10.1101/cshperspect.a017384
36. Pawlyk BS, Smith AJ, Buch PK, et al. Gene replacement therapy rescues photoreceptor degeneration in a murine model of Leber congenital amaurosis lacking RPGRIP. *Invest Ophthalmol Vis Sci.* 2005;46(9):3039–3045. doi:10.1167/iovs.05-0371
37. Pawlyk BS, Bulgakov OV, Liu X, et al. Replacement gene therapy with a human RPGRIP1 sequence slows photoreceptor degeneration in a murine model of Leber congenital amaurosis. *Hum Gene Ther.* 2010;21:993–1004.
38. Henderson RH, Mackay DS, Li Z, et al. Phenotypic variability in patients with retinal dystrophies due to mutations in CRB1. *Br J Ophthalmol.* 2011;95:811–817. doi:10.1136/bjo.2010.186882
39. Simonelli F, Ziviello C, Testa F, et al. Clinical and molecular genetics of Leber's congenital amaurosis: a multicenter study of Italian patients. *Invest Ophthalmol Vis Sci.* 2007;48(9):4284–4290. doi:10.1167/iovs.07-0068
40. Ahmed Khan S, Richard Nestel A. CRB1 gene mutation causing different phenotypes of leber congenital amaurosis in siblings. *J Ophthalmic Vis Res.* 2019;14(4):518–524. doi:10.18502/jovr.v14i4.5467
41. van de Pavert SA, Kantardzhieva A, Malysheva A, et al. Crumbs homologue 1 is required for maintenance of photoreceptor cell polarization and adhesion during light exposure. *J Cell Sci.* 2004;117(18):4169. doi:10.1242/jcs.01301
42. Boon N, Wijnholds J, Pellissier LP. Research models and gene augmentation therapy for CRB1 retinal dystrophies. *Front Neurosci.* 2020;14:860. doi:10.3389/fnins.2020.00860
43. den Hollander AI, Koenekoop RK, Yzer S, et al. Mutations in the CEP290 (NPHP6) gene are a frequent cause of Leber congenital amaurosis. *Am J Hum Genet.* 2006;79(3):556–561. doi:10.1086/507318
44. Perrault I, Delphin N, Hanein S, et al. Spectrum of NPHP6/CEP290 mutations in Leber congenital amaurosis and delineation of the associated phenotype. *Hum Mutat.* 2007;28(4):416. doi:10.1002/humu.9485
45. McAnany JJ, Genead MA, Walia S, et al. Visual acuity changes in patients with leber congenital amaurosis and mutations in CEP290. *JAMA Ophthalmol.* 2013;131(2):178–182. doi:10.1001/2013.jamaophthalmol.354
46. Yzer S, Hollander AI, Lopez I, et al. Ocular and extra-ocular features of patients with Leber congenital amaurosis and mutations in CEP290. *Mol Vis.* 2012;18:412–425.
47. Cideciyan AV, Rachel RA, Aleman TS, et al. Cone photoreceptors are the main targets for gene therapy of NPHP5 (IQCB1) or NPHP6 (CEP290) blindness: generation of an all-cone Nphp6 hypomorph mouse that mimics the human retinal ciliopathy. *Hum Mol Genet.* 2011;20(7):1411–1423. doi:10.1093/hmg/ddr022
48. Kong J, Kim S-R, Binley K, et al. Correction of the disease phenotype in the mouse model of stargardt disease by lentiviral gene therapy. *Gene Ther.* 2008;15(19):1311–1320. doi:10.1038/gt.2008.78
49. Verrier JD, Madorsky I, Coggin WE, et al. Bicistronic lentiviruses containing a viral 2A cleavage sequence reliably co-express two proteins and restore vision to an animal model of LCA1. *PLoS One.* 2011;6(5):e20553. doi:10.1371/journal.pone.0020553
50. den Hollander AI, Roepman R, Koenekoop RK, et al. Leber congenital amaurosis: genes, proteins and disease mechanisms. *Prog Retin Eye Res.* 2008;27(4):391–419. doi:10.1016/j.preteyeres.2008.05.003
51. Mackay DS, Dev Borman A, Moradi P, et al. RDH12 retinopathy: novel mutations and phenotypic description. *Mol Vis.* 2011;17:2706–2716.
52. Parker RO, Crouch RK. Dehydrogenases RDHs in the visual cycle. *Exp Eye Res.* 2010;91(6):788–792. doi:10.1016/j.exer.2010.08.013
53. Haeseleer F, Jang GF, Imanishi Y, et al. Dual-substrate specificity short chain retinol dehydrogenases from the vertebrate retina. *J Biol Chem.* 2002;277(47):45537–45546. doi:10.1074/jbc.M208882200
54. Schuster A, Janecke AR, Wilke R, et al. The phenotype of early-onset retinal degeneration in persons with RDH12 mutations. *Invest Ophthalmol Vis Sci.* 2007;48(4):1824–1831. doi:10.1167/iovs.06-0628
55. Valverde D, Pereiro I, Vallespín E, et al. Complexity of phenotype-genotype correlations in Spanish patients with RDH12 mutations. *Invest Ophthalmol Vis Sci.* 2009;50(3):1065–1068. doi:10.1167/iovs.08-2083
56. Thompson DA, Jia L, Yao J, et al. AAV-mediated expression of human Rdh12 in mouse retina. *Invest Ophthalmol Vis Sci.* 2012;53:1916.
57. Shahi PK, Hermans D, Sinha D, et al. Gene augmentation and readthrough rescue channelopathy in an iPSC-RPE model of congenital blindness. *Am J Hum Genet.* 2019;104(2):310–318. doi:10.1016/j.ajhg.2018.12.019
58. Pattnaik BR, Shahi PK, Marino MJ, et al. A novel KCNJ13 nonsense mutation and loss of Kir7.1 channel function causes leber congenital amaurosis (LCA16). *Hum Mutat.* 2015;36(7):720–727. doi:10.1002/humu.22807
59. Khan AO, Bergmann C, Neuhaus C, Bolz HJ. A distinct vitreo-retinal dystrophy with early-onset cataract from recessive KCNJ13 mutations. *Ophthalmic Genet.* 2015;36(1):79–84. doi:10.3109/13816810.2014.985846
60. Redmond TM, Poliakov E, Yu S, et al. Mutation of key residues of RPE65 abolishes its enzymatic role as isomerohydrolase in the visual cycle. *Proc Natl Acad Sci U S A.* 2005;102(38):13658–13663. doi:10.1073/pnas.0504167102
61. Hanein S, Perrault I, Gerber S, et al. Leber congenital amaurosis: comprehensive survey of the genetic heterogeneity, refinement of the clinical definition, and genotype-phenotype correlations as a strategy for molecular diagnosis. *Hum Mutat.* 2004;23(4):306–317. doi:10.1002/humu.20010
62. Dev Borman A, Ocaña LA, Mackay DS, et al. Early onset retinal dystrophy due to mutations in LRAT: molecular analysis and detailed phenotypic study. *Invest Ophthalmol Vis Sci.* 2012;53(7):3927–3938. doi:10.1167/iovs.12-9548
63. Acland GM, Aguirre GD, Ray J, et al. Gene therapy restores vision in a canine model of childhood blindness. *Nat Genet.* 2001;28(1):92–95. doi:10.1038/ng0501-92
64. Cideciyan AV, Jacobson SG, Beltran WA, et al. Human retinal gene therapy for Leber congenital amaurosis shows advancing retinal degeneration despite enduring visual improvement. *Proc Natl Acad Sci U S A.* 2013;110(6):E517–E525. doi:10.1073/pnas.1218933110
65. Swain G, Prociuk M, Bagel J, et al. Adeno-associated virus serotypes 9 and rh10 mediate strong neuronal transduction of the dog brain. *Gene Ther.* 2014;21(1):28–36. doi:10.1038/gt.2013.54
66. Narfstrom K, Katz ML, Bragadottir R, et al. Functional and structural recovery of the retina after gene therapy in the RPE65 null mutation dog. *Invest Ophthalmol Vis Sci.* 2003;44(4):1663–1672. doi:10.1167/iovs.02-0595
67. Narfstrom K, Katz ML, Ford M, et al. In vivo gene therapy in young and adult RPE65^{-/-} dogs produces long-term visual improvement. *J Hered.* 2003;94(1):31–37. doi:10.1093/jhered/esg015

68. Acland GM, Aguirre GD, Bennett J, et al. Long-term restoration of rod and cone vision by single dose rAAV-mediated gene transfer to the retina in a canine model of childhood blindness. *Mol Ther*. 2005;12(6):1072–1082. doi:10.1016/j.ymthe.2005.08.008
69. Le Meur G, Stieger K, Smith AJ, et al. Restoration of vision in RPE65-deficient briard dogs using an AAV serotype 4 vector that specifically targets the retinal pigmented epithelium. *Gene Ther*. 2007;14(4):292–303. doi:10.1038/sj.gt.3302861
70. Annear MJ, Bartoe JT, Barker SE, et al. Gene therapy in the second eye of RPE65-deficient dogs improves retinal function. *Gene Ther*. 2011;18(1):53–61. doi:10.1038/gt.2010.111
71. Wright JF. Manufacturing and characterizing AAV-based vectors for use in clinical studies. *Gene Ther*. 2008;15(11):840–848. doi:10.1038/gt.2008.65
72. Jacobson SG, Aleman TS, Cideciyan AV, et al. Identifying photoreceptors in blind eyes caused by RPE65 mutations: prerequisite for human gene therapy success. *Proc Natl Acad Sci U S A*. 2005;102(17):6177–6182. doi:10.1073/pnas.0500646102
73. Narfström K, Seeliger M, Lai CM, et al. Morphological aspects related to long-term functional improvement of the retina in the 4 years following rAAV-mediated gene transfer in the RPE65 null mutation dog. *Adv Exp Med Biol*. 2008;613:139–146. doi:10.1007/978-0-387-74904-4_15
74. Kumaran N, Moore AT, Weleber RG, et al. Leber congenital amaurosis/early-onset severe retinal dystrophy: clinical features, molecular genetics and therapeutic interventions. *Br J Ophthalmol*. 2017;101(9):1147–1154. doi:10.1136/bjophthalmol-2016-309975
75. Bainbridge JW, Smith AJ, Barker SS, et al. Effect of gene therapy on visual function in Leber's congenital amaurosis. *N Engl J Med*. 2008;358(21):2231–2239. doi:10.1056/NEJMoa0802268
76. Maguire AM, Simonelli F, Pierce EA, et al. Safety and efficacy of gene transfer for Leber's congenital amaurosis. *N Engl J Med*. 2008;358(21):2240–2248. doi:10.1056/NEJMoa0802315
77. Hauswirth WW, Aleman TS, Kaushal S, et al. Treatment of leber congenital amaurosis due to RPE65 mutations by ocular subretinal injection of adeno-associated virus gene vector: short-term results of a phase I trial. *Hum Gene Ther*. 2008;19(10):979–990. doi:10.1089/hum.2008.107
78. Miyazaki J, Takaki S, Araki K, et al. Expression vector system based on the chicken beta-actin promoter directs efficient production of interleukin-5. *Gene*. 1989;79(2):269–277. doi:10.1016/0378-1119(89)90209-6
79. Annear MJ, Mowat FM, Bartoe JT, et al. Successful gene therapy in older Rpe65-deficient dogs following subretinal injection of an adeno-associated vector expressing RPE65. *Hum Gene Ther*. 2013;24(10):883–893. doi:10.1089/hum.2013.146
80. Maguire AM, High KA, Auricchio A, et al. Age-dependent effects of RPE65 gene therapy for Leber's congenital amaurosis: a Phase I dose-escalation trial. *Lancet*. 2009;374(9701):1597–1605. doi:10.1016/S0140-6736(09)61836-5
81. Jacobson SG, Cideciyan AV, Ratnakaram R, et al. Gene therapy for leber congenital amaurosis caused by RPE65 mutations: safety and efficacy in 15 children and adults followed up to 3 years. *Arch Ophthalmol*. 2012;130(1):9–24. doi:10.1001/archophthol.2011.298
82. Testa F, Maguire AM, Rossi S, et al. Three-year follow-up after unilateral subretinal delivery of adeno-associated virus in patients with Leber congenital amaurosis type 2. *Ophthalmology*. 2013;120(6):1283–1291. doi:10.1016/j.ophtha.2012.11.048
83. Cideciyan AV, Hauswirth WW, Aleman TS, et al. Human RPE65 gene therapy for Leber congenital amaurosis: persistence of early visual improvements and safety at 1 year. *Hum Gene Ther*. 2009;20(9):999–1004. doi:10.1089/hum.2009.086
84. Wojno AP, Pierce EA, Bennett J. Seeing the light. *Sci Transl Med*. 2013;5(175):175–178. doi:10.1126/scitranslmed.3005798
85. Yavuz B, Kompella UB. Ocular drug delivery. *Handb Exp Pharmacol*. 2017;242:57–93.
86. Patel A, Cholkar K, Agrahari V, et al. Ocular drug delivery systems: an overview. *World J Pharmacol*. 2013;2(2):47–64. doi:10.5497/wjp.v2.i2.47
87. Maia M, Kellner L, de Juan E Jr, et al. Effects of indocyanine green injection on the retinal surface and into the subretinal space in rabbits. *Retina*. 2004;24:80–91. doi:10.1097/00006982-200402000-00012
88. Stout JT, Francis PJ. Surgical approaches to gene and stem cell therapy for retinal disease. *Hum Gene Ther*. 2011;22(5):531–535. doi:10.1089/hum.2011.060
89. Qi Y, Dai X, Zhang H, et al. Trans-corneal subretinal injection in mice and its effect on the function and morphology of the retina. *PLoS One*. 2015;10(8):e0136523. doi:10.1371/journal.pone.0136523
90. Ehlers JP, Petkovsek DS, Yuan A, et al. Intrastretinal assessment of subretinal tPA injection for submacular hemorrhage in the PIONEER study utilizing intraoperative OCT. *Ophthalmic Surg Lasers Imaging Retina*. 2015;46(3):327–332. doi:10.3928/23258160-20150323-05
91. Parikh S, Le A, Davenport J, et al. An alternative and validated injection method for accessing the subretinal space via a transcleral posterior approach. *J Vis Exp*. 2016;7(118):e54808. doi:10.3791/54808
92. Georgiadis A, Duran Y, Ribeiro J, et al. Development of an optimized AAV2/5 gene therapy vector for Leber congenital amaurosis owing to defects in RPE65. *Gene Ther*. 2016;23(12):857–862. doi:10.1038/gt.2016.66
93. Weber M, Rabinowitz J, Provost N, et al. Recombinant adeno-associated virus serotype 4 mediates unique and exclusive long-term transduction of retinal pigmented epithelium in rat, dog, and nonhuman primate after subretinal delivery. *Mol Ther*. 2003;7(6):774–781. doi:10.1016/S1525-0016(03)00098-4
94. Jacobson SG, Acland GM, Aguirre GD, et al. Safety of recombinant adeno-associated virus type 2- RPE65 vector delivered by ocular subretinal injection. *Mol Ther*. 2006;13(6):1074–1084. doi:10.1016/j.ymthe.2006.03.005
95. Boye SE, Boye SL, Lewin AS, Hauswirth WW. A comprehensive review of retinal gene therapy. *Mol Ther*. 2013;21(3):509–519. doi:10.1038/mt.2012.280
96. Kansara V, Muya L, Wan CR, Ciulla TA. Suprachoroidal delivery of viral and nonviral gene therapy for retinal diseases. *J Ocul Pharmacol Ther*. 2020;36(6):384–392. doi:10.1089/jop.2019.0126
97. Choi VW, McCarty DM, Samulski RJ. Host cell DNA repair pathways in adeno-associated viral genome processing. *J Virol*. 2006;80(21):10346–10356. doi:10.1128/JVI.00841-06
98. Dong B, Nakai H, Xiao W. Characterization of genome integrity for oversized recombinant AAV vector. *Mol Ther*. 2010;18(1):87–92. doi:10.1038/mt.2009.258
99. Wu Z, Yang H, Colosi P. Effect of genome size on AAV vector packaging. *Mol Ther*. 2010;18(1):80–86. doi:10.1038/mt.2009.255
100. McCarty DM, Monahan PE, Samulski RJ. Self-complementary recombinant adeno-associated virus (scAAV) vectors promote efficient transduction independently of DNA synthesis. *Gene Ther*. 2001;8(16):1248–1254. doi:10.1038/sj.gt.3301514
101. McCarty DM. Self-complementary AAV vectors; advances and applications. *Mol Ther*. 2008;16(10):1648–1656. doi:10.1038/mt.2008.171
102. Koilkonda RD, Chou T-H, Porciatti V, Hauswirth WW, Guy J. Induction of rapid and highly efficient expression of the human ND4 complex I subunit in the mouse visual system by self-complementary adeno-associated virus. *Arch Ophthalmol*. 2010;128(7):876–883. doi:10.1001/archophthol.2010.135
103. Petersen-Jones SM, Bartoe JT, Fischer AJ, et al. AAV retinal transduction in a large animal model species: comparison of a self-complementary AAV2/5 with a single-stranded AAV2/5 vector. *Mol Vision*. 2009;15:1835–1842.

104. Natkunarajah M, Trittibach P, McIntosh J, et al. Assessment of ocular transduction using single-stranded and self-complementary recombinant adeno-associated virus serotype 2/8. *Gene Ther.* 2007;15(6):463–467. doi:10.1038/sj.gt.3303074
105. Day TP, Byrne LC, Schaffer DV, Flannery JG. Advances in AAV vector development for gene therapy in the retina. *Adv Exp Med Biol.* 2014;801:687–693. doi:10.1007/978-1-4614-3209-8_86
106. Rayaprolu V, Kruse S, Kant R, et al. Comparative analysis of adeno-associated virus capsid stability and dynamics. *J Virol.* 2013;87(24):13150–13160. doi:10.1128/JVI.0141513
107. Pang JJ, Chang B, Kumar A, et al. Gene therapy restores vision-dependent behavior as well as retinal structure and function in a mouse model of RPE65 Leber congenital amaurosis. *Mol Ther.* 2006;13(3):565–572. doi:10.1016/j.ymthe.2005.09.001
108. Buck TM, Wijnholds J. Recombinant adeno-associated viral vectors (rAAV)-vector elements in ocular gene therapy clinical trials and transgene expression and bioactivity assays. *Int J Mol Sci.* 2020;21(12):4197. doi:10.3390/ijms21124197
109. Jacobson SG, Boye SL, Aleman TS, et al. Safety in nonhuman primates of ocular AAV2-RPE65, a candidate treatment for blindness in leber congenital amaurosis. *Hum Gene Ther.* 2006;17(8):845–858. doi:10.1089/hum.2006.17.845
110. Pierce EA, Bennett J. The status of RPE65 gene therapy trials: safety and efficacy. *Cold Spring Harb Perspect Med.* 2015;5(9):a017285. doi:10.1101/cshperspect.a017285
111. Cideciyan AV, Aleman TS, Boye SL, et al. Human gene therapy for RPE65 isomerase deficiency activates the retinoid cycle of vision but with slow rod kinetics. *Proc Natl Acad Sci.* 2008;105(39):15112–15117. doi:10.1073/pnas.0807027105
112. Simonelli F, Maguire AM, Testa F, et al. Gene therapy for Leber's congenital amaurosis is safe and effective through 1.5 years after vector administration. *Mol Ther.* 2010;18(3):643–650. doi:10.1038/mt.2009.277
113. Ashtari M, Cyckowski LL, Monroe JF, et al. The human visual cortex responds to gene therapy-mediated recovery of retinal function. *J Clin Invest.* 2011;121(6):2160–2168. doi:10.1172/JCI57377
114. Banin E, Bandah-Rozenfeld D, Obolensky A, et al. Molecular anthropology meets genetic medicine to treat blindness in the North African Jewish population: human gene therapy initiated in Israel. *Hum Gene Ther.* 2010;21(12):1749–1757. doi:10.1089/hum.2010.047
115. Le Meur G, Lebranchu P, Billaud F, et al. Safety and long-term efficacy of AAV4 gene therapy in patients with RPE65 leber congenital amaurosis. *Mol Ther.* 2018;26(1):256–268. doi:10.1016/j.ymthe.2017.09.014
116. Amado D, Mingozzi F, Hui D, et al. Safety and efficacy of subretinal readministration of an AAV2 vector in large animal models: implications for studies in humans. *Sci Transl Med.* 2010;2(21):21ra16. doi:10.1126/scitranslmed.3000659
117. Bennett J, Ashtari M, Wellman J, et al. AAV2 gene therapy readministration in three adults with congenital blindness. *Sci Transl Med.* 2012;4(120):120ra115. doi:10.1126/scitranslmed.3002865
118. Bennett J, Wellman J, Marshall KA, et al. Safety and durability of effect of contralateral-eye administration of AAV2 gene therapy in patients with childhood-onset blindness caused by RPE65 mutations: a follow-on phase I trial. *Lancet.* 2016;388(10045):661–672. doi:10.1016/S0140-6736(16)30371-3
119. Russell S, Bennett J, Wellman JA, et al. Efficacy and safety of voretigene neparvovec (AAV2-hRPE65v2) in patients with RPE65-mediated inherited retinal dystrophy: a randomised, controlled, open-label, Phase 3 trial. *Lancet.* 2017;390(10097):849–860. doi:10.1016/S0140-6736(17)31868-8
120. Darrow JJ. Luxturna: FDA documents reveal the value of a costly gene therapy. *Drug Discov Today.* 2019;24(4):949–954. doi:10.1016/j.drudis.2019.01.019
121. Chung DC, McCague S, Yu ZF, et al. Novel mobility test to assess functional vision in patients with inherited retinal dystrophies. *Clin Exp Ophthalmol.* 2018;46(3):247–259. doi:10.1111/ceo.13022
122. Rodrigues GA, Shalaev E, Karami TK, Cunningham J, Slater NKH, Rivers HM. Pharmaceutical development of AAV-based gene therapy products for the eye. *Pharm Res.* 2018;36(2):29. doi:10.1007/s11095-018-2554-7
123. Novartis announces landmark EU approval for one-time gene therapy Luxturna® to restore vision in people with rare inherited retinal disease [Internet]. Novartis; [cited May 24, 2020]. Available from: <https://www.novartis.com/news/media-releases/novartis-announces-landmark-eu-approval-one-time-gene-therapy-luxturna-restore-vision-people-rare-inherited-retinal-disease>.
124. Moiseyev G, Chen Y, Takahashi Y, Wu BX, Ma JX. RPE65 is the isomerohydrolase in the retinoid visual cycle. *Proc Nat Acad Sci.* 2005;102(35):12413–12418. doi:10.1073/pnas.0503460102
125. Mackay DS, O'caka LA, Borman AD, et al. Screening of SPATA7 in patients with leber congenital amaurosis and severe childhood-onset retinal dystrophy reveals disease-causing mutations. *Invest Ophthalmol Vis Sci.* 2011;52(6):3032–3038. doi:10.1167/iovs.10-7025
126. Li Y, Wang H, Peng J, et al. Mutation survey of known LCA gene and loci in the Saudi Arabian population. *Invest Ophthalmol Vis Sci.* 2009;50(3):1336–1343. doi:10.1167/iovs.08-2589
127. Boldt K, Mans DA, Won J, et al. Disruption of intraflagellar protein transport in photoreceptor cilia causes Leber congenital amaurosis in humans and mice. *J Clin Invest.* 2011;121(6):2169–2180. doi:10.1172/JCI45627
128. Dharmaraj S, Li Y, Robitaille JM, et al. A novel locus for Leber congenital amaurosis maps to chromosome 6q. (letter). *Am J Hum Genet.* 2000;66(1):319–326. doi:10.1086/302719
129. Mohamed MD, Topping NC, Jafri H, Raashed Y, McKibbin MA, Inglehearn CF. Progression of phenotype in Leber's congenital amaurosis with a mutation at the LCA5 locus. *Br J Ophthalmol.* 2003;87(4):473–475. doi:10.1136/bjo.87.4.473
130. Jacobson SG, Cideciyan AV, Huang WC, et al. Leber congenital amaurosis: genotypes and retinal structure phenotypes. *Adv Exp Med Biol.* 2016;854:169–175.
131. Nichols LL 2nd, Alur RP, Boobalan E, et al. Two novel CRX mutant proteins causing autosomal dominant Leber congenital amaurosis interact differently with NRL. *Hum Mutat.* 2010;31(6):E1472–83. doi:10.1002/humu.21268
132. Kimura A, Singh D, Wawrousek EF, Kikuchi M, Nakamura M, Both ST. PCE-1/RX and OTX/CRX interactions are necessary for photoreceptor-specific gene expression. *J Biol Chem.* 2000;275(27):1152–1160. doi:10.1074/jbc.275.2.1152
133. Freund CL, Wang QL, Chen S, et al. De novo mutations in the CRX homeobox gene associated with Leber congenital amaurosis. *Nat Genet.* 1998;18(4):311–312. doi:10.1038/ng0498-311
134. Swaroop A, Wang QL, Wu W, et al. Leber congenital amaurosis caused by a homozygous mutation (R90W) in the homeodomain of the retinal transcription factor CRX: direct evidence for the involvement of CRX in the development of photoreceptor function. *Hum Mol Genet.* 1999;8(2):299–305. doi:10.1093/hmg/8.2.299
135. Akagi T, Mandai M, Ooto S, et al. Otx2 homeobox gene induces photoreceptor-specific phenotypes in cells derived from adult iris and ciliary tissue. *Invest Ophthalmol Vis Sci.* 2004;45(12):4570–4575. doi:10.1167/iovs.04-0697
136. Koenekoop RK, Wang H, Majewski J, et al. Mutations in NMNAT1 cause Leber congenital amaurosis and identify a new disease pathway for retinal degeneration. *Nat Genet.* 2012;44(9):1035–1039. doi:10.1038/ng.2356
137. Burnight ER, Wiley LA, Drack AV, et al. CEP290 gene transfer rescues Leber congenital amaurosis cellular phenotype. *Gene Ther.* 2014;21(7):662–672. doi:10.1038/gt.2014.39

138. Collart FR, Huberman E. Cloning and sequence analysis of the human and Chinese hamster inosine-5-prime-monophosphate dehydrogenase cDNAs. *J Biol Chem.* 1988;263:15769–15772.
139. Bowne SJ, Sullivan LS, Mortimer SE, et al. Spectrum and frequency of mutations in IMPDH1 associated with autosomal dominant retinitis pigmentosa and Leber congenital amaurosis. *Invest Ophthalmol Vis Sci.* 2006;47(1):34–42. doi:10.1167/iovs.05-0868
140. Molday LL, Djajadi H, Yan P, et al. RD3 gene delivery restores guanylate cyclase localization and rescues photoreceptors in the Rd3 mouse model of Leber congenital amaurosis 12. *Hum Mol Genet.* 2013;22(19):3894–3905. doi:10.1093/hmg/ddt244
141. Preising MN, Hausotter-Will N, Solbach MC, Friedburg C, Rüschemdorf F, Lorenz B. Mutations in RD3 are associated with an extremely rare and severe form of early onset retinal dystrophy. *Invest Ophthalmol Vis Sci.* 2012;53(7):3463–3472. doi:10.1167/iovs.12-9519
142. Friedman JS, Chang B, Kannabiran C, et al. Premature truncation of a novel protein, RD3, exhibiting subnuclear localization is associated with retinal degeneration. *Am J Hum Genet.* 2006;79(6):1059–1070. doi:10.1086/510021
143. Xi Q, Pauer GJ, Marmorstein AD, Crabb JW, Hagstrom SA. Tubby-like protein 1 (TULP1) interacts with F-actin in photoreceptor cells. *Invest Ophthalmol Vis Sci.* 2005;46(12):4754–4761. doi:10.1167/iovs.05-0693
144. Mataftsi A, Schorderet DF, Chachoua L, et al. Novel TULP1 mutation causing leber congenital amaurosis or early onset retinal degeneration. *Invest Ophthalmol Vis Sci.* 2007;48(11):5160–5167. doi:10.1167/iovs.06-1013
145. Zhang L, Lim SL, Du H, et al. High temperature requirement factor A1 (HTRA1) gene regulates angiogenesis through transforming growth factor- β family member growth differentiation factor 6. *J Biol Chem.* 2012;287(2):1520–1526. doi:10.1074/jbc.M111.275990
146. Asai-Coakwell M, French CR, Berry KM. GDF6, a novel locus for a spectrum of ocular developmental anomalies. *Am J Hum Genet.* 2007;80(2):306–315. doi:10.1086/511280
147. The online mendelian inheritance in man website. Available from: www.omim.org. Accessed August 15, 2017. OMIM# 179605. Peripherin 2, Mouse, Homolog of PRPH2. Cytogenetic location.
148. Bascom RA, Connell G, Garcia-Heras J, et al. Molecular and ultrastructural characterization of the products of the human retinopathy candidate genes ROM1 and RDS. (Abstract). *Am J Hum Genet.* 1990;47(suppl):A101.
149. Wang X, Wang H, Sun V, et al. Comprehensive molecular diagnosis of 179 Leber congenital amaurosis and juvenile retinitis pigmentosa patients by targeted next generation sequencing. *J Med Genet.* 2013;50(10):674–688. doi:10.1136/jmedgenet-2013-101558

The Application of Clinical Genetics

Dovepress

Publish your work in this journal

The Application of Clinical Genetics is an international, peer-reviewed open access journal that welcomes laboratory and clinical findings in the field of human genetics. Specific topics include: Population genetics; Functional genetics; Natural history of genetic disease; Management of genetic disease; Mechanisms of genetic disease;

Counselling and ethical issues; Animal models; Pharmacogenetics; Prenatal diagnosis; Dysmorphology. The manuscript management system is completely online and includes a very quick and fair peer-review system, which is all easy to use. Visit <http://www.dovepress.com/testimonials.php> to read real quotes from published authors.

Submit your manuscript here: <https://www.dovepress.com/the-application-of-clinical-genetics-journal>