

Treatment of facial rejuvenation with fat restoration

Seyed Reza Mousavi

Surgical Department, Shohada Medical Center, Shahid Beheshti University of Medical Sciences, Tajrish, Tehran, Iran

Objective: To improve the compensation for fat atrophy and making the face look young and improve the mental and emotional conditions of patients.

Material and methods: Our study was done from April 2003 to March 2006 with an assessment and documentation of the degree of facial lipoatrophy.

Results: We have very good results in 91% of patients with no important complications.

Discussion: Treatment of facial lipoatrophy is justified to overcome the physical and social consequences of facial fat loss that occur as a natural part of aging.

Keywords: facial rejuvenation, facial lipoatrophy, aging

Introduction

Facial lipoatrophy is the loss of fat that supports the fullness, shape, and contour of the face. However, lipoatrophy is also a common, natural part of the aging process and occurs in patients with certain cancers and type 2 diabetes and with extremes of exercise.¹⁻³

Treatment options such as bovine- and human-derived collagen products, fat injections, botulinum toxin, hyaluronic acid, and semipermanent fillers are available to complement the surgical interventions used by dermasurgeons. The proper selection and administration of these agents earlier in the process of lipoatrophy permit dermasurgeons to tailor the available medical and surgical interventions more effectively to meet their patients' needs. This educational program (education applicants and their cooperation with the surgeon and psychologist) will share the clinical experiences of an expert faculty on the process of assessing and treating facial lipoatrophy in patients who seek counseling. People who are unable to hide their aging appearance can sometimes experience eroded self-image and a lack of self-esteem. In some cases, clinical depression and social isolation occur, and among HIV patients, lipoatrophy can lead to poor compliance with therapy.^{4,5}

Kligman eloquently stated more than 15 years ago, "An aged, degraded skin is uncomfortable to live in. It is also unattractive and leads to aversive reactions by others. The unhandsome aged have trouble maintaining self-esteem when they recollect the smooth, unmarked, turgid skin that was the clothing of their youth."⁵

Left untreated, elderly individuals, who may already have fewer social contacts over time, can be confronted with a further lessening of contact with potential providers of support, including health care providers. Enhancing appearance provides a psychological boost that may lead to positive thoughts and actions.⁵ Most

Correspondence: Seyed Reza Mousavi
Surgical Department, Shohada Medical Center, Shahid Beheshti University of Medical Sciences, Tajrish, Tehran, Iran
Email seyed29@yahoo.com

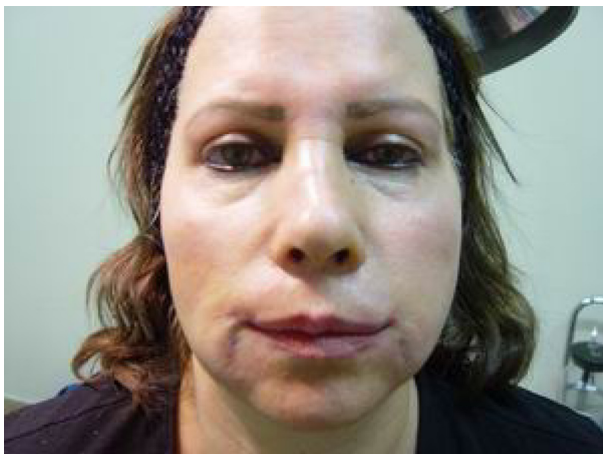

Table 1 Lipoatrophy: 4-point scale

Grade 1	Grade 2	Grade 3	Grade 4
82%	16%	2%	0%

importantly, in HIV patients, treatment in the most severely affected patients has been shown to reduce the physical consequences of facial fat loss.⁶ The purpose of this series of articles is to review the changes in fat distribution that lead to facial lipoatrophy. Clinical strategies to assess lipoatrophy and treatment options using temporary and semipermanent fillers are also reviewed.

Results

Our study was done on 385 patients in our surgical clinic from April 2003 to March 2006. Fat injection for cheek was 86%, for forehead 10%, and 4% for lip (lower 1%, and upper 3%). The excellent result for cheek was over 91% without important complications. We used a 3-point scale (mild, moderate, or severe) that is commonly used by clinicians to categorize the extent of lipoatrophy. However, by broadening the mild to moderate levels, it is possible to refine this assessment, particularly in patients where the etiology of facial lipoatrophy is associated with aging. We used the physical appearance of lipoatrophy to create a 4-point scale. A small, localized area of fat loss characterizes grade 1 lipoatrophy (82%). In grade 2 lipoatrophy (16%), more than one area is affected (generally including the jowl and oral commissure). Grade 3 lipoatrophy (2%) is characterized by a larger area with distinct shadowing. Patients with severe fat depletion in all facial regions, and with protruding musculature and bones is assigned grade 4 lipoatrophy (Table 1 and Figures 1 and 2).

**Figure 1** Before fat injection in grade 3 lipoatrophy.**Figure 2** After fat injection in grade 3 lipoatrophy.

The mean follow-up for the patients in the study was 6 months and long follow-up was more than 1 year.

Conclusions

Treatment of facial lipoatrophy is justified to overcome the physical and social consequences of facial fat loss that occur as a natural part of aging or as a consequence of certain diseases and drug therapy. During the past 25 years, many new treatments have been developed and approved by the US Food and Drug Administration (FDA). Other compounds and modifications of previously approved compounds are being developed and are likely to become available during the next few years.

FDA oversight and approval are important because the availability of thoroughly tested and approved products offers reassurance that a pure formulation can be obtained from a reliable source. For best results, physicians must be trained and skilled in fat injection techniques and be prepared to use a combination of techniques to achieve the best results for their patients.

Once lipoatrophy occurs, the goal of treatment is to reestablish the facial arcs and convexities that characterize the young face. There are no proven therapies to reverse or prevent peripheral lipoatrophy. Aside from cosmetic surgery, an array of temporary, semipermanent, and permanent injectable fillers are available to correct altered fat distribution. Other potential options in patients with HIV include switching antiretroviral drugs and administering thiazolidinediones. The use of antioxidants or cofactors has also been suggested.⁷

Despite the increasing demand and popularity of facial rejuvenation procedures, there has been little real change in traditional surgical techniques during recent decades.⁸ Surgical intervention as a treatment option for facial lipoatrophy

produces less than optimal results because it fails to address the primary issue of volume loss, and the unwanted results of traditional procedures become easy to recognize over time. For example, the unopposed tension of lateral vector face-lifts allows the cheek tissues to descend eventually over the tightened jawline, creating a ‘lateral sweep’ or pulled-back appearance in the face.⁸

We offer fat injection instead of other injectable material because it is very safe and has no complications.

Disclosure

No conflicts of interest were declared in relation to this paper.

References

1. Benn P, Sauret-Jackson V, Cartledge J, et al. Improvements in cheek volume in lipoatrophic individuals switching away from thymidine nucleoside reverse transcriptase inhibitors. *HIV Med.* 2009; 10(6):351–355.
2. Rooney DP, Ryan MF. Diabetes with partial lipodystrophy following sclerodermatous chronic graft vs. host disease. *Diabet Med.* 2006; 23(4):436–440.
3. Yiannias JA, DiCaudo DJ, Maskin E. Peripheral T-cell lymphoma presenting as lipoatrophy and nodules. *Int J Dermatol.* 2006; 45(12):1415–1419.
4. Ammassari A, Antinori A, Cozzi-Lepri A, et al. Relationship between HAART adherence and adipose tissue alterations. *J Acquir Immune Defic Syndr.* 2002;31 Suppl 3:S140–S144.
5. Kligman AM. Psychological aspects of skin disorders in the elderly. *Cutis.* 1989;43:498–501.
6. Valantin MA, Aubron-Olivier C, Ghosn J, et al. Poly lactic acid implants (New-Fill) to correct facial lipoatrophy in HIV-infected patients: results of the open-label study VEGA. *AIDS.* 2003;17:2471–2477.
7. Aids Clinical Trials Group. ACTG Metabolic Guides. 2002. Available at: <http://aactg.s-3.com/metabolic/default.htm>. Accessed Nov 2, 2005.
8. Hamra ST. Prevention and correction of the “face-lifted” appearance. *Facial Plast Surg.* 2000;16:215–230.

Clinical, Cosmetic and Investigational Dermatology

Publish your work in this journal

Clinical, Cosmetic and Investigational Dermatology is an international, peer-reviewed, open access, online journal that focuses on the latest clinical and experimental research in all aspects of skin disease and cosmetic interventions. All areas of dermatology will be covered; contributions will be welcomed from all clinicians and

Submit your manuscript here: <http://www.dovepress.com/clinical-cosmetic-and-investigational-dermatology-journal>

basic science researchers globally. This journal is indexed on CAS. The manuscript management system is completely online and includes a very quick and fair peer-review system, which is all easy to use. Visit <http://www.dovepress.com/testimonials.php> to read real quotes from published authors.

Dovepress