

Adenomatous Hyperplasia of the Gallbladder in the Setting of Mirizzi Syndrome, Mimicking Adenocarcinoma of the Gallbladder

Charles Newton Odongo¹
Carlos Cabrera Dreque¹
Felix Bongomin²
Felix Oyania³
Martin Situma¹
Raymond Atwine⁴

¹Department of Surgery, Faculty of Medicine, Mbarara University of Science and Technology, Mbarara, Uganda;

²Departments of Medical Microbiology & Immunology, and Internal Medicine, Faculty of Medicine, Gulu University, Gulu, Uganda; ³Department of Surgery, Faculty of Medicine, Kabale University, Kabale, Uganda; ⁴Department of Pathology, Faculty of Medicine, Mbarara University of Science and Technology, Mbarara, Uganda

Background: Adenomatous hyperplasia (AH) is an uncommon benign lesion of the gallbladder (GB), predominantly seen in men. AH is commonly confused with malignant GB neoplasms in the setting of chronic cholecystitis and gallstones. There is a scarcity of published literature on AH, suggesting its rarity and the need for this case report.

Case Presentation: A 24-year-old woman from Western Uganda presented with signs and symptoms consistent with extrahepatic biliary obstruction. Trans-abdominal ultrasound scan revealed cholecystomegaly (13.9 cm by 4.29 cm), thickened GB wall at 5.2 mm, with a poorly defined hypoechoic polypoid solid mass involving the fundal body of the GB. Explorative laparotomy with cholecystectomy and lymph node sampling was performed. Histopathological examination was consistent with adenomatous hyperplasia of the GB. The symptoms and laboratory values improved on follow-up in the clinic after laparotomy.

Conclusion: Adenomatous hyperplasia may be misdiagnosed as a malignant GB neoplasm, especially in the setting of chronic cholecystitis and gallstones. If a correct histopathological diagnosis is made, no further diagnostic work-up is necessary following surgical interventions.

Keywords: adenomatous hyperplasia, gallbladder, Mirizzi syndrome

Background

Benign neoplasms and tumor-like lesions of the gallbladder and the extrahepatic bile ducts are infrequent, and diagnosis of these lesions are often difficult to establish on the basis of signs and symptoms.^{1,2} Of these entities, adenomatous hyperplasia, with characteristic histopathological features of hyperplasia of metaplastic pyloric-type glands and of deep-seated glands in the absence of cellular atypia of the gallbladder, is uncommon.² These histological changes result in a thickened and nodular gallbladder mucosa.² Adenomatous hyperplasia, frequently referred to as pseudotumor, is completely benign, with no potential for a malignant transformation. There is little information about adenomatous hyperplasia, thus suggesting the infrequency of its occurrence. Adenomatous hyperplasia bears a resemblance to adenomyomatosis, though the former has extensive hypertrophy of the muscular layer, rather than the mucosa. Here we describe a case of an adenomatous hyperplasia of the gallbladder in a young adult female Ugandan.

Case Presentation

A 24-year-old female presented at a teaching hospital in Western Uganda with a two-month history of yellow discoloration of the sclerae associated with body itching, clay

Correspondence: Charles Newton Odongo
Department of Surgery, Faculty of Medicine, Mbarara University of Science and Technology, Mbarara, Uganda
Email cnodongo@gmail.com

Table 1 Laboratory Work-Ups of the Case

Parameters	Preoperative Laboratory Values	Laboratory Values One Month After Laparotomy	Reference Point of MRRH Laboratory
Total bilirubin	8.2 mg/dL	1.3 mg/dL	(0.20–1.30)
Conjugated bilirubin	5.9 mg/dL	1.2 mg/dL	(0.00–0.30)
Unconjugated bilirubin	2.6 mg/dL	0.4 mg/dL	(0.00–0.30)
Alkaline phosphatase	4463 U/L	312 U/L	(64–306)
Alanine transaminase	109.0 U/L	40 U/L	(0–42)
Aspartate transaminase	123.2 U/L	50 U/L	(0–37)
Gamma-glutamyl transferase	120 U/L	64 U/L	(0–55)
Hemoglobin	13 mg/dL	11.4 mg/dL	(9.5–13.5)
White cell count	7.8	10	(5.50–17.00)
Platelets	323	330	(150–400)
International normalized ratio	1.5	1.11	(<1.1) – normal patients not on warfarin
CA 19-9	21 U/mL		0–36
CEA	1.2 ng/mL		<2.5 ng/mL
Sodium	138 mmol/L	Not repeated	(135–145) mmol/L
Potassium	3.7 mmol/L	Not repeated	(3.5–5.5) mmol/L
Chloride	91 mmol/L	Not repeated	(95–105) mmol/L

Abbreviation: MRRH, Mbarara Regional Referral Hospital.

colored stool, loss of weight, and dark colored urine. She had non-contributory past medical history. Physical examinations revealed a wasted young female, with deep jaundice, therapeutic marks on right upper quadrant, and multiple scratch marks on the skin of the anterior abdominal wall and the limbs; she had moderate conjunctival pallor. Courvoisier's sign was positive, and Murphy's sign was negative. Her preoperative alkaline phosphatase was elevated 15-fold, and total bilirubin was elevated 6.3-fold upper limit of normal, predominantly conjugated hyperbilirubinemia (Table 1).

Trans-abdominal ultrasound scan revealed cholecystomegaly (13.9 cm × 4.29 cm), thickened gallbladder wall at 5.2 mm, with a poorly defined hypoechoic polypoid solid mass noted involving the fundal body of the gallbladder. The mass measured 4.1 cm × 1.4 cm, and moderately dilated common hepatic duct measured 2.00 cm. There was also intrahepatic biliary duct dilatation. With the above findings, a provisional diagnosis of symptomatic

extrahepatic biliary obstruction was made, and a decision to undertake explorative laparotomy was made.

Laparotomy Findings and Surgical Intervention

Findings were a thickened gallbladder wall with impacted stones at the lumen of infundibulum of the gallbladder, a dilated common hepatic duct, and no palpable mass or dilatation of common bile duct. The lymph nodes along the common bile duct were retrieved, and cholecystectomy was performed. Both gallbladder and lymph nodes were sent for histopathology.

Pathological Evaluation

On gross examination, a single piece of greenish gray tissue, soft, with firm nodular areas, 2.5 cm × 1.5 cm × 1 cm, with homogeneous solid was sampled all in two cassettes. Microscopically (H&E) the gallbladder mucosa

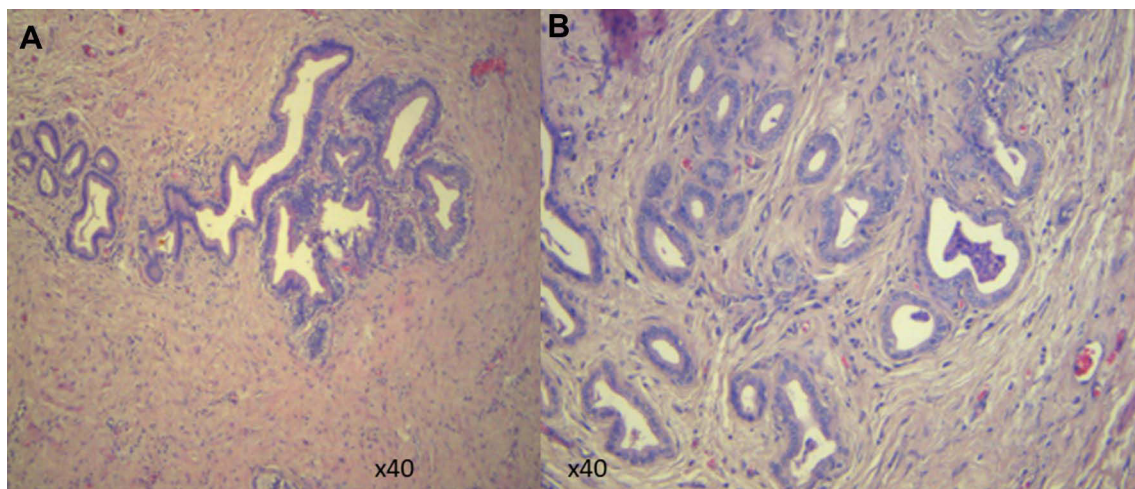


Figure 1 Mucosa consisting of variably sized glands lined by cytologically bland epithelium (A) and proliferated bland glands, with mild chronic inflammatory infiltrates (B).

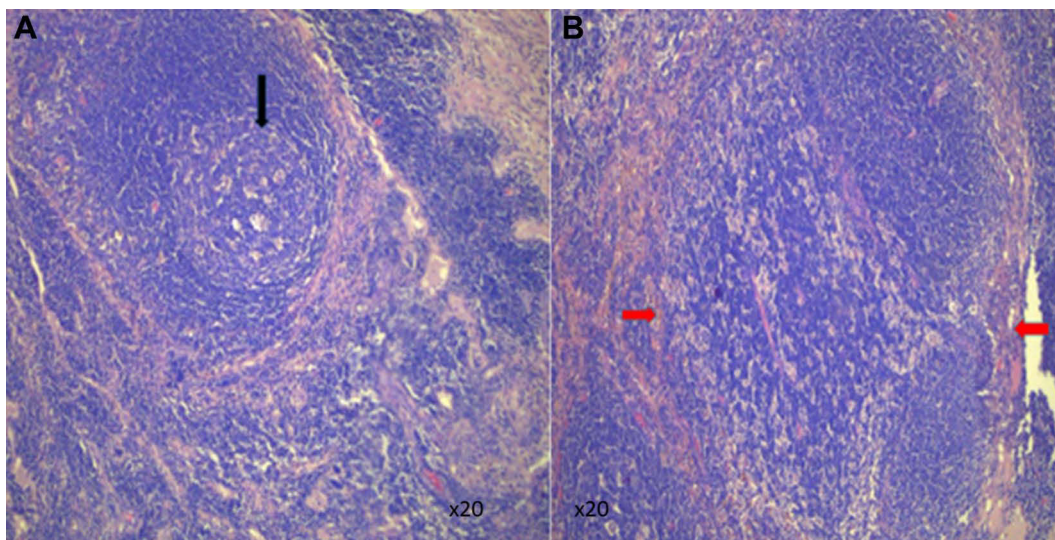


Figure 2 Lymph node tissue showing increased follicles (black arrow, (A)) and numerous histiocytosis (red arrows, (B)).

showed fibro-muscular adipose tissue, in the presence of proliferated bland glands, and had mild chronic inflammatory infiltrates. The muscular walls were not hypertrophied, and gallbladder mucosa consisted of variably sized glands lined by cytologically bland epithelium (Figure 1A and B). Lymph nodes showed preserved architecture with polymorphous, increased follicles and sinus histiocytosis (Figure 2A and B).

Discussion

Adenomatous hyperplasia of the gallbladder is an uncommon benign lesion that should always be differentiated from malignant tumors of the gallbladder as surgical resection

offers a complete cure for this unique disease entity.¹ Recent small and large case series have reported the prevalence of adenomatous hyperplasia to range between 0.8% and 12% of cholecystectomy specimens.¹ In comparison, the prevalence of malignancy has been reported to be as high as 15%, particularly in association with polyps of less than 1 centimeter in dimension.³ Adenomatous hyperplasia per se is not a premalignant lesion; however, previous studies have suggested a link between gallbladder carcinoma in the presence of gallstones, chronic inflammation, and metaplastic changes in patients with adenomatous hyperplasia.¹ There is a substantial increase in the incidence of adenomatous hyperplasia of the gallbladder in the past few years. This has been

attributed to: 1) recent advances in imaging techniques with new and more sensitive imaging modalities being widely available; and 2) the increasing numbers of laparoscopic cholecystectomies performed annually.^{3,4} Malignant transformation of adenomatous hyperplasia has been reported in relation to the presence of gallstones (80%), porcelain gallbladder (10–20%), and advanced age.^{3,5}

The clinical features of adenomatous hyperplasia are right upper quadrant pain, nausea and vomiting associated with meals, and occasionally overt features of extrahepatic biliary obstruction such as jaundice, body itching, clay colored stool, and dark colored urine.^{1,3,6} These overt symptoms of extrahepatic biliary obstruction were evident in our patient.

Right upper abdominal ultrasound scan revealed a thickened gallbladder wall with Mirizzi syndrome; this is consistent with other findings.^{7,8} Gallbladder wall thickening with engulfed stones has also been associated with carcinogenesis, making the diagnosis of adenomatous hyperplasia more difficult to predict.^{6,9} Perhaps contrast-enhanced ultrasonography using a galactose-based contrast agent would help distinguish the two entities by classifying them into linear, scattered, diffuse or branched, with diffuse and branched types considered as cancer.¹⁰ However, this modality is not available in this setting. Endoscopic ultrasound scan (EUS) is the imaging modality of choice compared to transabdominal ultrasound scan because of its higher ultrasound frequencies. Studies in other settings show that hypoechoic foci on EUS would differentiate neoplastic from non-neoplastic gallbladder lesions with high sensitivity 90% and specificity 89%.¹⁰ Two-phase spiral CT has been found to have a role in the differentiation between adenomatous hyperplasia and gallbladder malignancy. Wall thickness and enhancement pattern of the gallbladder wall are seen during the arterial and venous phases.¹¹ Mean wall thicknesses were 12.6 mm in the gallbladder carcinoma group and 6.9 mm in the adenomatous hyperplasia group.

Histological features of adenomatous hyperplasia include gallbladder mucosa with elongated papillary folds, fibrotic core, and a mild lymphocytic infiltrate.^{2,12} The surface shows hyperplasia of metaplastic pyloric-type glands, while branching mucous glands are found in deeper layers, focally filling the lamina propria.^{2,12,13} Both adenomyomatosis and adenomatous hyperplasia occur in the setting of chronic cholecystitis and in conjunction with the presence of gallstones.¹⁴ For our patient, histopathology revealed fibro-muscular adipose tissue, in the presence of proliferated bland glands, and mild chronic inflammatory

infiltrates without hypertrophy of the muscular layer, differentiating it from adenomyomatosis. In adenomyomatosis, cholesterol accumulation is intraluminal, and crystals precipitate in bile trapped in intramural diverticula (Rokitansky–Aschoff sinuses) lined by the epithelial layer of the mucosa.^{2,6} Gallbladder wall thickening and intramural diverticula containing cholesterol crystals, or calculi, are pathognomonic of adenomyomatosis.^{1,2,6,12} In contrast, in adenomatous hyperplasia, there is deposition of triglycerides and cholesterol esters within macrophages in the lamina propria, and the polyp is covered by normal epithelium.^{6,9} However, gallbladder malignancy should be suspected when there are features of a focal mass with locoregional lymphadenopathy, metastases, and features of biliary obstruction at the level of the porta hepatis.¹ These entities occur more commonly in females because of the greater prevalence of gallstone disease.^{1,2,9} The hyperplastic mucosa absorbs more bile than normal, and precipitation occurs with the increasing concentration, giving rise to stone formation.⁹ The other hypothesis proposed is that primary cholelithiasis causes secondary hyperplasia because of mechanical irritation by the calculi.⁹ The patient improved postoperatively, and her symptoms improved on follow-up in clinic.

Conclusion

Adenomatous hyperplasia of the gallbladder mimics malignant lesions, particularly in the setting of chronic cholecystitis and gallstones. Adenomatous hyperplasia is a benign disorder, and therefore no further diagnostic work-up is necessary in its management following a complete surgical resection.

Data Sharing Statement

The information used and/or analyzed during this case report is available from the corresponding author on reasonable request.

Ethics Approval and Consent to Participate

No institutional approval was required to publish the case details, as this case was identified during routine clinical care. The patient provided an informed written consent.

Consent for Publication

The patient provided an informed written consent for this case to be published in a peer-reviewed journal.

Acknowledgments

We would like to acknowledge.

Author Contributions

All authors made a significant contribution to the work reported, whether that is in the conception, study design, execution, acquisition of data, analysis and interpretation, or in all these areas; took part in drafting, revising or critically reviewing the article; gave final approval of the version to be published; have agreed on the journal to which the article has been submitted; and agree to be accountable for all aspects of the work.

Disclosure

The authors declare that they have no competing interests in this work.

References

- Mahajan A, Sripathi S. Gallbladder adenomyomatosis mimicking carcinoma: a diagnostic dilemma. *J Glob Oncol*. 2016;2(5):341. doi:10.1200/JGO.2016.005249
- Zimmermann A. Hyperplastic lesions and metaplastic changes of the gallbladder. In: *Tumors and Tumor-Like Lesions of the Hepatobiliary Tract*. Springer Cham; 2017:2747–2763.
- Bird JR, Brahm GL, Fung C, Sebastian S, Kirkpatrick ID. Recommendations for the management of incidental hepatobiliary findings in adults: endorsement and adaptation of the 2017 and 2013 ACR Incidental Findings Committee White Papers by the Canadian Association of Radiologists Incidental Findings Working Group. *Can Assoc Radiolog J*. 2020;71(4):437–447. doi:10.1177/0846537120928349
- Seale MK, Catalano OA, Saini S, Hahn PF, Sahani DV. Hepatobiliary-specific MR contrast agents: role in imaging the liver and biliary tree. *Radiographics*. 2009;29(6):1725–1748. doi:10.1148/rg.296095515
- Giang TH, Ngoc TT, Hassell LA. Carcinoma involving the gallbladder: a retrospective review of 23 cases-pitfalls in diagnosis of gallbladder carcinoma. *Diagn Pathol*. 2012;7(1):1–9. doi:10.1186/1746-1596-7-10
- Mellnick VM, Menias CO, Sandrasegaran K, et al. Polypoid lesions of the gallbladder: disease spectrum with pathologic correlation. *Radiographics*. 2015;35(2):387–399. doi:10.1148/rg.352140095
- Lee W. Diagnostic and therapeutic algorithm: polypoid lesions of the gallbladder. In: *Diseases of the Gallbladder*. Springer; 2020:255–268.
- Yu MH, Kim YJ, Park HS, Jung SI. Benign gallbladder diseases: imaging techniques and tips for differentiating with malignant gallbladder diseases. *World J Gastroenterol*. 2020;26(22):2967. doi:10.3748/wjg.v26.i22.2967
- Stokes MC, Burnette R, Ballard B, Ross C, Beech DJ. Adenomatous hyperplasia of the gallbladder. *J Natl Med Assoc*. 2007;99(8):959.
- Vijayakumar A, Vijayakumar A, Patil V, Mallikarjuna M, Shivaswamy B. Early diagnosis of gallbladder carcinoma: an algorithm approach. *ISRN Radiol*. 2012;2013:239424.
- Yun E, Cho S, Park S, et al. Gallbladder carcinoma and chronic cholecystitis: differentiation with two-phase spiral CT. *Abdom Imaging*. 2004;29(1):102–108. doi:10.1007/s00261-003-0080-4
- Shima N, Ohike N, Suzuki R, et al. Clinicopathological study of mass-forming gallbladder cancer focusing on the grade of cellular dysplasia. *Showa Univ J Med Sci*. 2018;30(1):35–42. doi:10.15369/sujms.30.35
- Shukla SK, Pant P, Singh G, Shahi K, Shahi KS. Histopathological examination of gallbladder specimens in Kumaon region of Uttarakhand. *J Gastrointest Cancer*. 2020;51(1):121–129. doi:10.1007/s12029-018-00188-4
- Katabi N. Neoplasia of gallbladder and biliary epithelium. *Arch Pathol Lab Med*. 2010;134(11):1621–1627. doi:10.5858/2009-0580-RAR.1

International Medical Case Reports Journal

Dovepress

Publish your work in this journal

The International Medical Case Reports Journal is an international, peer-reviewed open-access journal publishing original case reports from all medical specialties. Previously unpublished medical posters are also accepted relating to any area of clinical or preclinical science. Submissions should not normally exceed 2,000 words or 4

published pages including figures, diagrams and references. The manuscript management system is completely online and includes a very quick and fair peer-review system, which is all easy to use. Visit <http://www.dovepress.com/testimonials.php> to read real quotes from published authors.

Submit your manuscript here: <https://www.dovepress.com/international-medical-case-reports-journal-journal>