

# Cancer Metastases from Lung Adenocarcinoma Disappeared After Molecular Targeted Therapy: A Successfully Clinical Treatment Experience

Meng-Jie Li<sup>1,\*</sup>, Jun Wei<sup>2,\*</sup>, Guo-Ping Ai<sup>3,\*</sup>, Ying Liu<sup>4</sup>, Jian Zhu<sup>4</sup> 

<sup>1</sup>Department of Respiratory Oncology, Renmin Hospital of Qingxian, Cangzhou, 062650, People's Republic of China; <sup>2</sup>Department of the First Surgery, Wuhan Jin-Yin-Tan Hospital, Wuhan, 430011, People's Republic of China; <sup>3</sup>Department of Radiology, General Hospital of Central Theater Command of the People's Liberation Army, Wuhan, 430070, People's Republic of China; <sup>4</sup>Department of Thoracic Cardiovascular Surgery, General Hospital of Central Theater Command of the People's Liberation Army, Wuhan, 430070, People's Republic of China

\*These authors contributed equally to this work

Correspondence: Jian Zhu; Ying Liu, Department of Thoracic Cardiovascular Surgery, General Hospital of Central Theater Command of the People's Liberation Army, Wuhan, 430070, People's Republic of China, Tel +86-13871166489, Fax +86-27-50772388, Email zhujian0718@163.com; xxwky@163.com

**Introduction:** Molecular targeted therapy has shown certain therapeutic effects on various cancer types, especially lung cancer. Here, we report a case of a patient with unresectable non-small cell lung cancer (NSCLC) with bone metastases and metastatic lesions that disappeared after molecular targeted therapy.

**Patient Information:** A 49-year-old male patient's chest CT scan showed a patchy, slightly high-density shadow on the upper lobe of the left lung with an unclear boundary. The multiple thoracic vertebrae, 4th lumbar vertebrae, multiple ribs, right sacroiliac joint, right hip joint, right inferior ramus of pubis, left middle and upper femur, and right proximal radial bone showed nodular and slightly high-density shadows.

**Interventions:** The patient was not considered eligible for tumor resection due to his metastatic lesions. A resected lymph node biopsy was performed. The pathologic findings suggested lung adenocarcinoma, and the gene detection results indicated NM-005228: exon19:c.2235–2249del:p. GLu746-Ala750del (15.31%), NM-005228:exon20:c. G2356A: p. V786M (1.67%). The patient received the icotinib hydrochloride molecular targeted therapy.

**Outcomes:** After two months of treatment, pulmonary nodules were basically absent on chest CT scan re-examination. After nine months of treatment, no obvious abnormalities in the thoracic vertebral bone were found on 99mTc-MDP bone scan and CT scan re-examination. No obvious structural abnormalities, such as enlarged lymph nodes, could be found by ultrasound re-examination, and the patient remained alive without recurrence at the five-year follow-up.

**Conclusion:** This case report may provide a clue for the future development of molecular targeted therapy for lung cancer. It will allow surgeons to collaborate with oncologists and raise awareness of the benefit of the multidisciplinary approach to the diagnosis and treatment of cancer. Moreover, our results will help patients to fully understand the effect of nonsurgical treatments and improve confidence in the diagnosis and treatment of advanced lung cancer.

**Keywords:** bone metastases, lung cancer, molecular targeted therapy, gene therapy

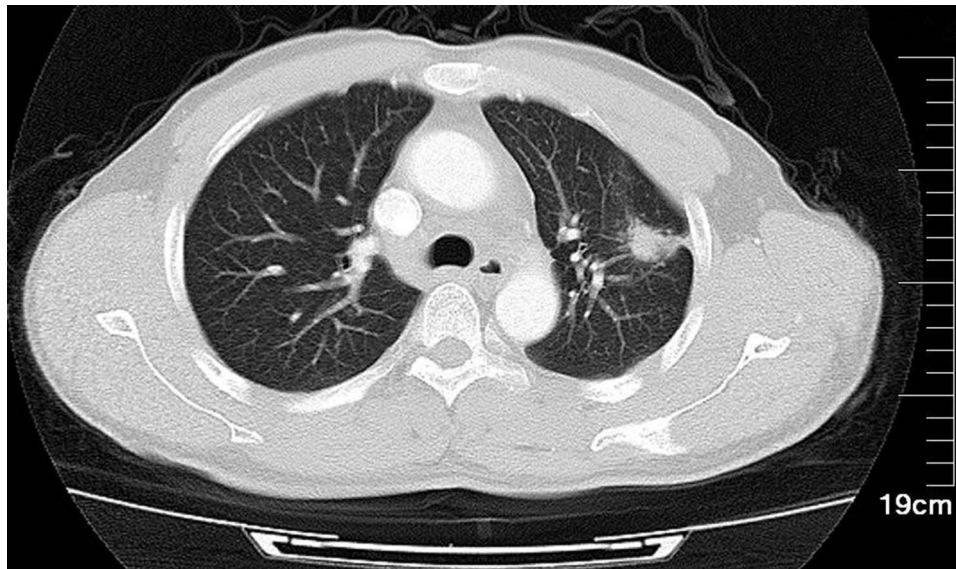
## Introduction

For nearly half a century, many surgeons have believed they are the only individuals capable of saving cancer patients. This bias also applies to cancer patients, who believe they will die of cancer without surgery. In fact, surgery can prolong the lifespan of patients with early and locally advanced cancer to a certain degree; however, the effect of surgery is limited.<sup>1</sup> Large-scale gene detection has identified different driver gene mutations in the subtypes of non-small cell lung cancer (NSCLC), which has resulted in several achievements in the development of molecular targeted therapies for lung cancer in recent years.<sup>2</sup> Several previous literature reports reveal that molecular targeted therapy can produce a good therapeutic effect in patients with corresponding gene mutations.<sup>3</sup> However, the disappearance of bone metastases after molecular targeted

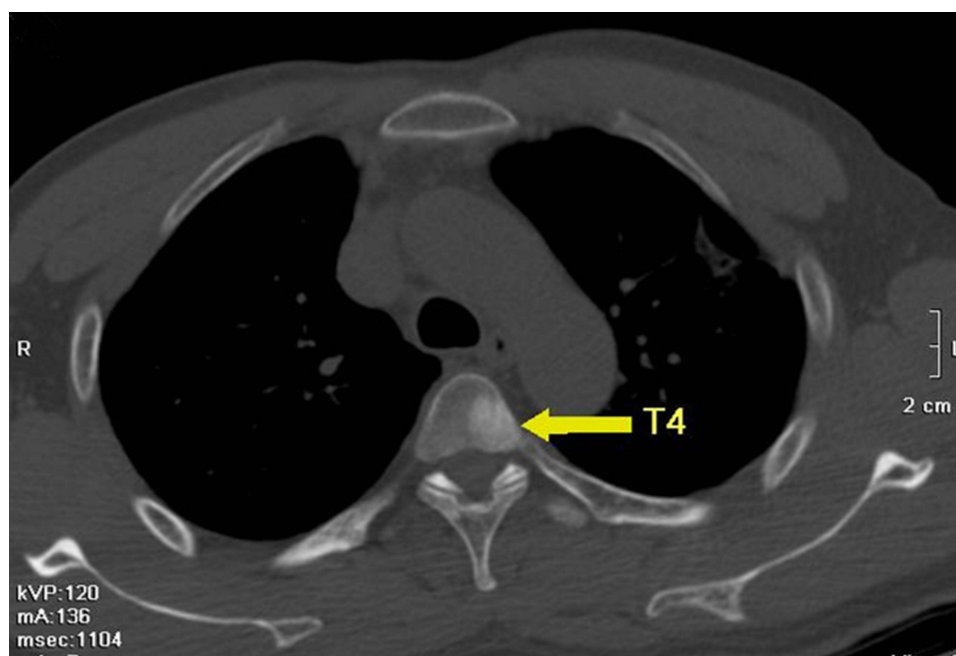
therapy alone has few previously reported. Here, we report this finding in our exciting case of a man with bone cancer metastases from lung adenocarcinoma.

## Case Report

A 49-year-old man presented with an irritating dry cough that had persisted for two weeks. He had been smoking thirty cigarettes a day for ten years and had quit smoking more than one year prior. His father and two older brothers died of lung cancer. His 28-year-old daughter was recently diagnosed with early-stage lung adenocarcinoma. The patient had no relevant past medical records, nor had he taken any medication. His chest computed tomography (CT) scan showed a  $2.8 \times 1.2$  cm patchy, slightly high-density shadow on the upper lobe of the left lung, and there were multiple burr shadows around the edges (see Figure 1). In addition, the 4th (see Figure 2), 5th, 6th, 10th, 12th thoracic vertebrae, 4th lumbar vertebrae, 3rd right anterior rib, 5th left costal

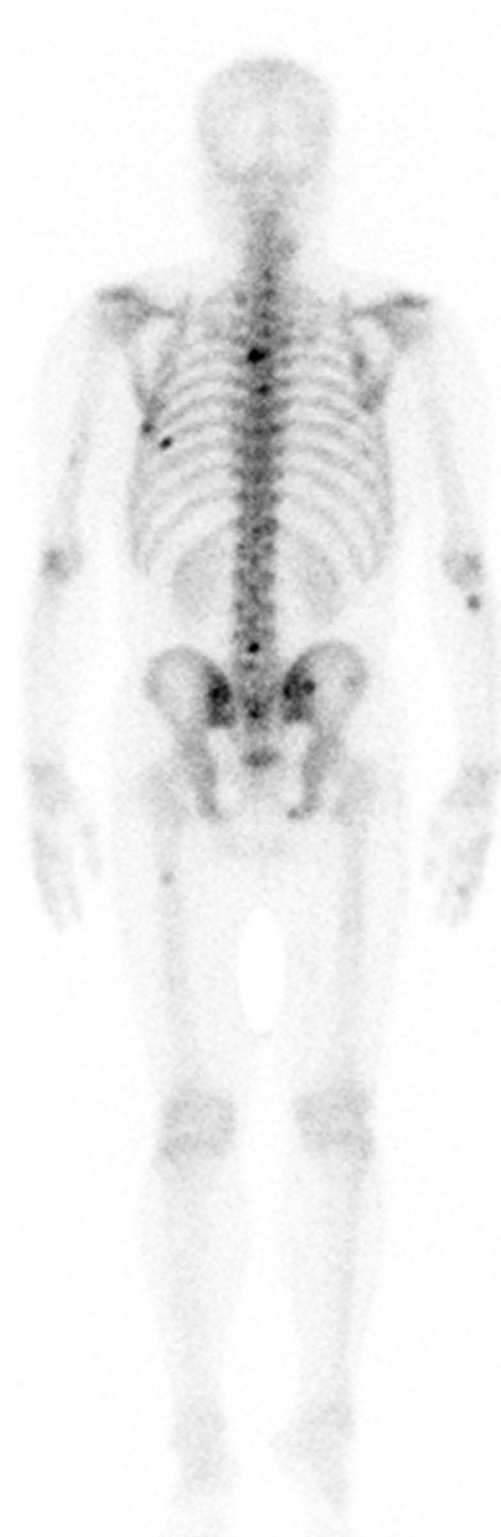


**Figure 1** A 16-slice computed tomographic scan revealed a left lung nodule superior lobe ( $2.8 \times 1.2$  cm) anterior segment. The nodule had a spiculated sign, pleural indentation, vessel convergence, and multiple burr shadows on the edges.



**Figure 2** A 16-slice computed tomographic scan revealed a high-density nodule in the fourth thoracic vertebra.

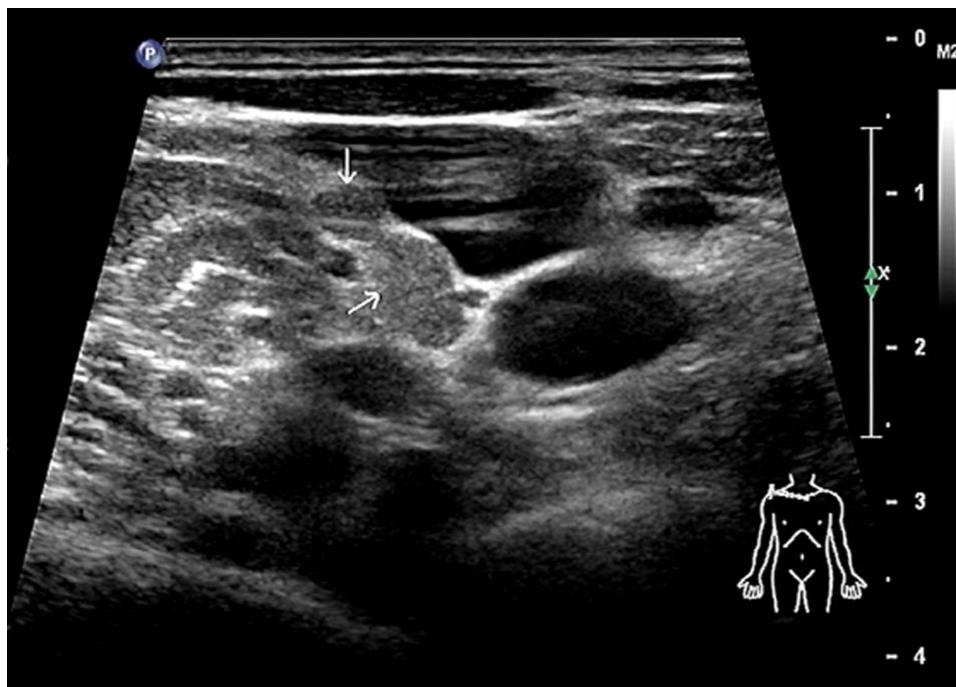
axillary side, 8th left posterior rib, right sacroiliac joint, right hip joint, right inferior ramus of pubis, left middle and upper femur, right proximal radial bone showed nodular and slightly high-density shadows. This result suggested that the left upper lobe lung cancer was complicated by hilar and bone metastasis. Bone metastases were also confirmed by a  $^{99m}\text{Tc}$ -MDP bone scan (see Figure 3), in which the bone showed vigorous metabolism. Considering that the multiple metastases could not be completely



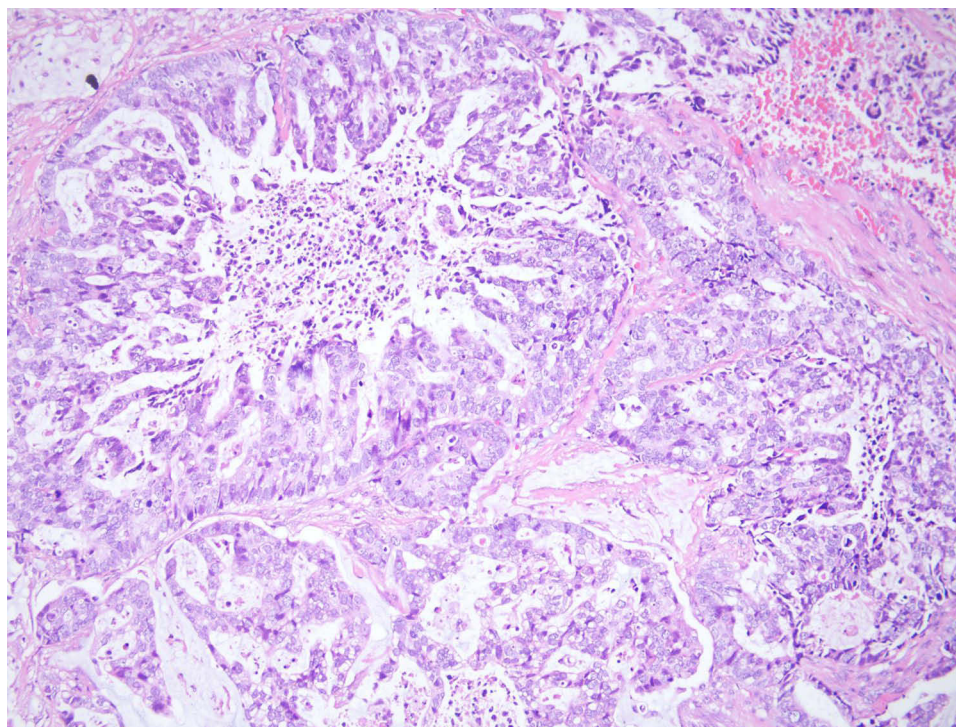
**Figure 3** A  $^{99m}\text{Tc}$ -MDP bone scan revealed bone metastases at the 4th, 5th, 6th, 10th, and 12th thoracic vertebrae and 4th lumbar vertebrae.



resected, we identified ipsilateral supraclavicular lymph nodes with metastases by ultrasound (see Figure 4). Then, we performed a resected lymph node biopsy. The pathologic findings suggested lung adenocarcinoma (Figure 5) and PCK (+), TTF (+), CK7 (+), Napsin A (+), CDX2 (-), Villin (-), P40 (-), Syn (-), and Ki67 (5–10%). Genetic testing of paraffin section from supraclavicular



**Figure 4** An enlarged lymph node that can be touched on the surface of the body is proven to be structurally abnormal by color ultrasound and is eventually used for pathological biopsy.



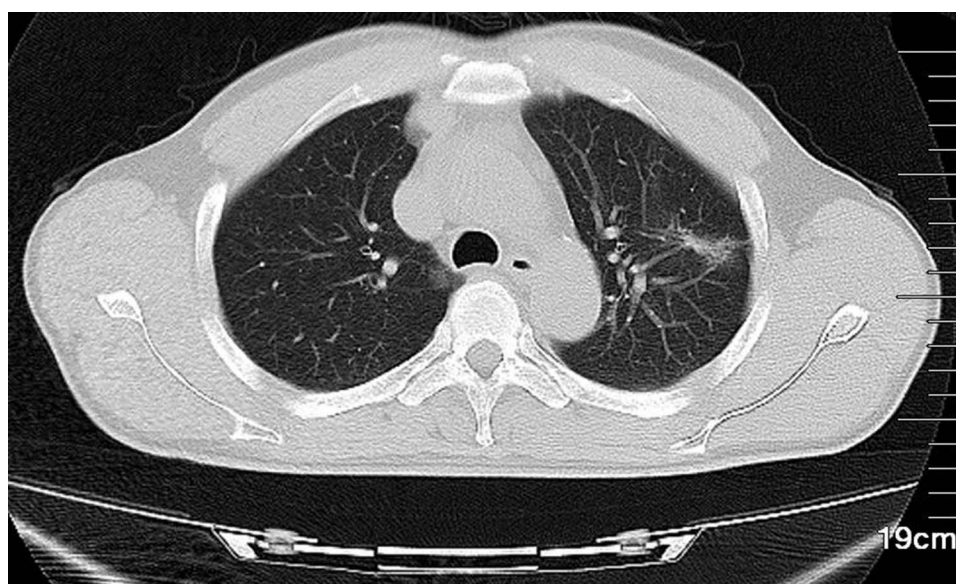
**Figure 5** Image of histologic diagnosis using hematoxylin and eosin staining (original  $\times 200$ ), which revealed lung adenocarcinoma metastasis.

lymph node was conducted in a CLIA-certified lab using hybridization capture-based next-generation sequencing panels. Gene targets (MyGene, BGI-Shenzhen [Headquarters]: Shenzhen, 518083, China. Genomic alterations assessed included single nucleotide variations, insertions and deletions, copy number variations, and gene rearrangements in selected genes. The MyGene panels covered common lung cancer-related genes. The minimum coverage across the sample was  $\geq 1000\times$ . Actionability of genomic alterations and the level of evidence were determined based on the OncoKB dataset and drug approval status in mainland China) results indicated NM-005228:exon19:c.2235–2249del:p. GLu746-Ala750del (15.31%), NM-005228:exon20:c. G2356A: p.V786M (1.67%). Based on the examinations, a tentative diagnosis of T4N3M1c (stage IVB, according to the seventh edition of TNM) lung cancer was proposed.

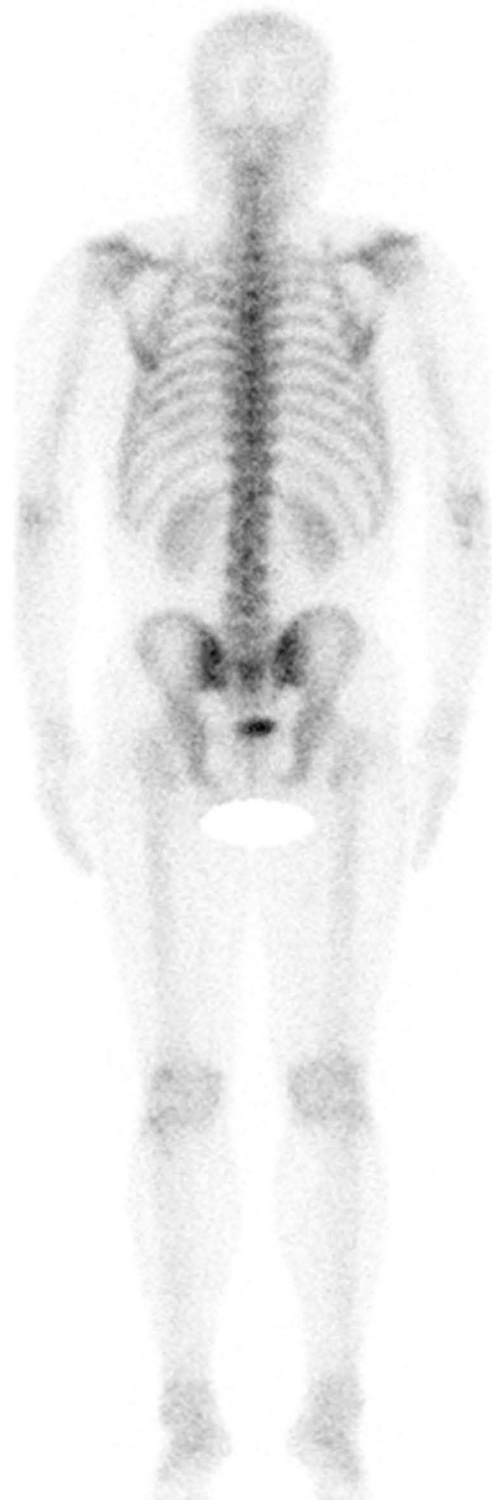Given that the tumor was unresectable, the patient opted for icotinib hydrochloride-molecular targeted therapy after the multidisciplinary team (MDT) doctors' explanation of various treatments. After two months of treatment with icotinib hydrochloride only, pulmonary nodules were basically absent on chest CT scan re-examination (see Figure 6). The patient's white blood cells were normal, and liver and kidney function tests were normal. He had no symptoms other than mild skin itching. Considering that the patient responded relatively well to the therapy, he was approved to continue taking icotinib hydrochloride. Subsequently, the patient's nuclear medicine doctors were surprised to find that the bone metastatic lesions had disappeared on the follow-up 99mTc-MDP bone scan and CT scan (see Figures 7 and 8) nine months after the initiation of icotinib hydrochloride monotherapy. No obvious structural abnormalities, such as enlarged lymph nodes, could be found by ultrasound re-examination.

## Discussion

Lung cancer is the leading cause of cancer-related death worldwide, with the highest morbidity rate. The diagnosis and treatment of lung cancer has undergone tremendous changes in recent years.<sup>4,5</sup> Surgery can prolong the lifespan of patients with early and locally advanced lung cancer to a certain degree; however, the effect of surgery is limited. Prolonged patient survival no longer depends mainly on the innovation of surgical techniques or the thorough dissection of lymph nodes but also on the development of therapeutics by biomedical scientists, including molecular targeted therapy, immunotherapy, and anti-angiogenesis therapy.<sup>6</sup> The lung cancer that had metastasized in this patient could not be surgically removed cleanly; thus, treatment was limited. Historically, patients with stage IVB NSCLC have poor clinical outcomes; however, recent advances in molecular targeted therapy have shown survival benefit. We identified the type of cancer in our patient through pathological biopsy and identified the mutation sites of the patient's cancer through genetic analysis. Icotinib was given as the first-line treatment for this patient as it was the most

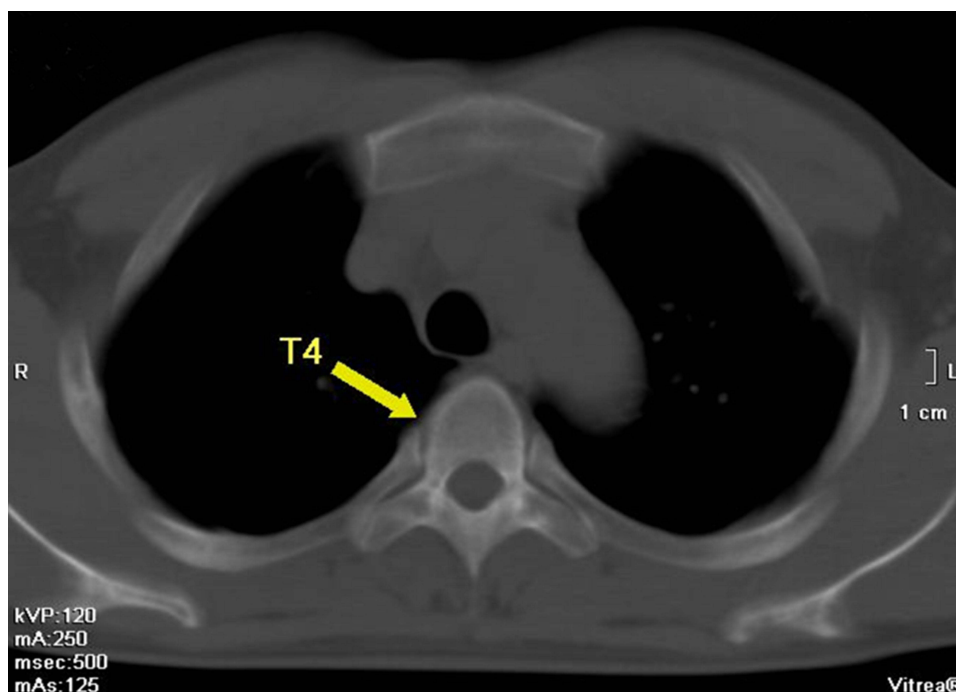


**Figure 6** A 16-slice computed tomographic scan revealed that the left lung nodule was significantly smaller than before and was almost absorbed.



**Figure 7** A  $^{99m}\text{Tc}$ -MDP bone scan revealed that the bone metastases were absorbed.





**Figure 8 A** 16-slice computed tomographic scan revealed that the high-density nodule in the fourth thoracic vertebra was absorbed.

appropriate approach based on the genetic testing data. Herein, we summarize novel therapies with icotinib in NSCLC.

Icotinib is a novel epidermal growth factor receptor-tyrosine kinase inhibitor (EGFR-TKI) that has good antitumor efficacy for NSCLC, especially for patients with exon 19 deletion (19Del) or exon 21 L858R mutation.<sup>7</sup> It has become one of the standard drugs for the treatment of advanced NSCLC in China.<sup>8</sup> Compared to the other two commercially available EGFR tyrosine kinase inhibitors, gefitinib and erlotinib, icotinib is similar in chemical structure, mechanism of activity and therapeutic effects, but is less expensive. Better safety and a wider therapeutic window have also been shown in several Chinese studies.<sup>9,10</sup>

In the present patient, it took only two months from the initiation of treatment for the primary tumor to almost disappear; subsequently, the bone metastases disappeared. This was not only unthinkable for the patient but was also incomprehensible to the nuclear doctors. The patient was treated without the use of surgical resection of the tumor, but the treatment outcome was significantly better than surgical resection.

Of course, there are also limitations in this report. Even an isolated case is not enough to explain the great effect of molecular targeted therapy. But I believe it is a beginning, a beginning for nonoperative curing cancer metastases from lung adenocarcinoma.

In conclusion, molecular targeted therapy may result in the disappearance of bone metastases, indicating that molecular targeted therapy for lung cancer may be an important approach to lung cancer treatment. The results of this case will allow surgeons to collaborate with oncologists and raise awareness of the importance of the multidisciplinary approach to the diagnosis and treatment of cancer. Moreover, our finding will help patients to fully understand the effect of nonsurgical treatment and improve their confidence in the diagnosis and treatment of advanced lung cancer.

## Ethics Approval and Consent to Participate

Written informed consent was obtained from the patient in accordance with the Declaration of Helsinki for the purpose of publication of the present case report and any relevant images.

## Consent for Publication

Written informed consent was obtained from the patient for publication of the case report and the accompanying.

## Author Contributions

All authors contributed to data analysis, drafting or revising the article, gave final approval of the version to be published, agreed to the submitted journal, and agreed to be accountable for all aspects of the work. Meng-Jie Li, Jun Wei, and Guo-Ping Ai contributed equally to this work and should be considered as co-first authors for this study.

## Funding

This work is supported by grants from Yuying Plan with Growth Project of General hospital of Central Theater Command of the People's Liberation Army, CHINA [No. ZZYZCZ202106] and Primary Research & Development Plan of Hubei Province, CHINA [No.2020BCB059].

## Disclosure

The authors declare that they have no conflicts of interest for this work.

## References

1. Zhao L, Li L, Chen T, Fang C. Effective treatment of NSCLC with surgery after nivolumab combined with chemotherapy: a case report and brief review of the literature. *Oncotargets Ther.* 2020;13:13307–13313. doi:10.2147/OTT.S266155
2. Osmani L, Askin F, Gabrielson E, Li QK. Current WHO guidelines and the critical role of immunohistochemical markers in the subclassification of non-small cell lung carcinoma (NSCLC): moving from targeted therapy to immunotherapy. *Semin Cancer Biol.* 2018;52:103–109. doi:10.1016/j.semcancer.2017.11.019
3. Smeltzer MP, Wynes MW, Lantuejoul S, et al. The International Association for the Study of Lung Cancer Global Survey on molecular testing in lung cancer. *J Thorac Oncol.* 2020;15(9):1434–1448. doi:10.1016/j.jtho.2020.05.002
4. Shrestha S, Higuchi T, Shirai K, et al. Prognostic significance of semi-quantitative FDG-PET parameters in stage I non-small cell lung cancer treated with carbon-ion radiotherapy. *Eur J Nucl Med Mol Imaging.* 2020;47(5):1220–1227. doi:10.1007/s00259-019-04585-0
5. Zhu J, Zhang Y, Gao XH, Xi EP. Coronavirus disease 2019 or lung cancer: a differential diagnostic experience and management model from Wuhan. *J Thorac Oncol.* 2020;15(8):e141–e142. doi:10.1016/j.jtho.2020.04.030
6. Gotwals P, Cameron S, Cipolletta D, et al. Prospects for combining targeted and conventional cancer therapy with immunotherapy. *Nat Rev Cancer.* 2017;17(5):286–301. doi:10.1038/nrc.2017.17
7. Qu J, Wang YN, Xu P, et al. Clinical efficacy of icotinib in lung cancer patients with different EGFR mutation status: a meta-analysis. *Oncotarget.* 2017;8(20):33961–33971. doi:10.18632/oncotarget.15475
8. Xu L, Qi Q, Zhang Y, Cui J, Liu R, Li Y. Combination of icotinib and chemotherapy as first-line treatment for advanced lung adenocarcinoma in patients with sensitive EGFR mutations: a randomized controlled study. *Lung Cancer.* 2019;133:23–31. doi:10.1016/j.lungcan.2019.05.008
9. Guan YS, He Q, Li M. Icotinib: activity and clinical application in Chinese patients with lung cancer. *Expert Opin Pharmacother.* 2014;15(5):717–728. doi:10.1517/14656566.2014.890183
10. Pan S, Wang S, Li W, Chai Y. Icotinib versus cisplatin plus docetaxel as adjuvant chemotherapy in patients with stage II (N1+) non-small cell lung cancer harboring positive EGFR mutations: a single-center retrospective study. *Oncotargets Ther.* 2021;14:1083–1091. doi:10.2147/OTT.S290636

Pharmacogenomics and Personalized Medicine

Dovepress

Publish your work in this journal

Pharmacogenomics and Personalized Medicine is an international, peer-reviewed, open access journal characterizing the influence of genotype on pharmacology leading to the development of personalized treatment programs and individualized drug selection for improved safety, efficacy and sustainability. This journal is indexed on the American Chemical Society's Chemical Abstracts Service (CAS). The manuscript management system is completely online and includes a very quick and fair peer-review system, which is all easy to use. Visit <http://www.dovepress.com/testimonials.php> to read real quotes from published authors.

Submit your manuscript here: <https://www.dovepress.com/pharmacogenomics-and-personalized-medicine-journal>