



Giant Lupus Vulgaris with Negative T-SPOT.TB, a Case Report and Literature Review

Zhen-Zhen Wang ¹, Hongsheng Wang ^{1,2}

¹Institute of Dermatology, Chinese Academy of Medical Sciences & Peking Union Medical College, Jiangsu Key Laboratory of Molecular Biology for Skin Diseases and STIs, Nanjing, People's Republic of China; ²Center for Global Health, School of Public Health, Nanjing Medical University, Nanjing, People's Republic of China

Correspondence: Hongsheng Wang, Institute of Dermatology, Chinese Academy of Medical Sciences & Peking Union Medical College, Jiangsu Key Laboratory of Molecular Biology for Skin Diseases and STIs, St. 12 Jiangwangmiao, Nanjing, Jiangsu, People's Republic of China, Tel +86 13002571330, Fax +86 25-85478953, Email whs33@vip.sina.com

Abstract: Lupus vulgaris is a paucibacillary form of cutaneous tuberculosis (CTB) which is accounting for 1–2% of all tuberculosis cases. Here, we report a rare huge lupus vulgaris misdiagnosed as sarcoidosis for 11 years. A 65-year-old man presented to dermatology outpatient with a large asymptomatic erythematous plaque and erosions on his neck. Sarcoidosis was initially diagnosed on the basis of negative interferon-gamma release tests and biopsies of lymph nodes and lesions. The patient was treated with long-term oral steroid and immunosuppressive agents, but the lesions expanded gradually. Lupus vulgaris was finally diagnosed by combining molecular detection and mycobacterial culture. The skin lesions were resolved after six months of standard antituberculosis therapy. We report this case to analyze the reasons for the misdiagnosis and review-related literature to further provide experience for the diagnosis and treatment of cutaneous tuberculosis with negative T-SPOT.TB.

Keywords: lupus vulgaris, cutaneous tuberculosis, diagnosis, T-SPOT.TB

Introduction

CTB is a rare form of tuberculosis, comprising 1–2% of all tuberculosis cases.¹ There are many masquerading features of lupus vulgaris, including papule, nodular, plaque, ulcerative, vegetating forms, psoriasis and tumor-like lesions and so on. Due to a great variability in the clinical presentations of CTB, misdiagnoses are not uncommon due to lack of recognition. Here, we report a case of huge lupus vulgaris misdiagnosed as sarcoidosis for 11 years. The patient received long-term steroid therapy leading to Cushing's syndrome-like manifestations and even femoral head necrosis. We report this case to raise diagnostic awareness and treatment of atypical CTB with negative T-SPOT.TB.

Case Report

A 65-year-old immunocompetent man presented to our hospital with an 11-year history of a huge erythematous erosive plaque on his neck. The lesions developed from a pigeon's egg-sized nodule 11 years ago. Physical examination showed a reddish nodular plaque with superficial erosions, tough textures, well-defined borders on his neck in a size of 18 × 10 cm and verrucous proliferating nodules behind his left ear with no abnormalities on neurological examination (Figure 1). Apple jelly nodules were seen on diascopy. He was previously healthy and had no fever, dry cough, fatigue, or other complaints. He denied any history of contact with tuberculosis patients. Initially, sarcoidosis was diagnosed based on biopsies of skin lesions or lymph nodes and he was treated with prednisone acetate and azathioprine over 10 years. However, the skin lesions are still gradually expanding.

Laboratory examinations including syphilis, human immunodeficiency virus tests, peripheral blood lymphocytes count, microscopic examination of *Mycobacterium leprae*, IgM and IgG levels against NDO-LID as well as MMP-II for leprosy, acid-fast staining of sputum smear and anti- *Mycobacterium tuberculosis* antibodies showed negative results. The measurement of enzyme-linked immunospot assay for tuberculosis (T-SPOT.TB) and leprosy were also negative.

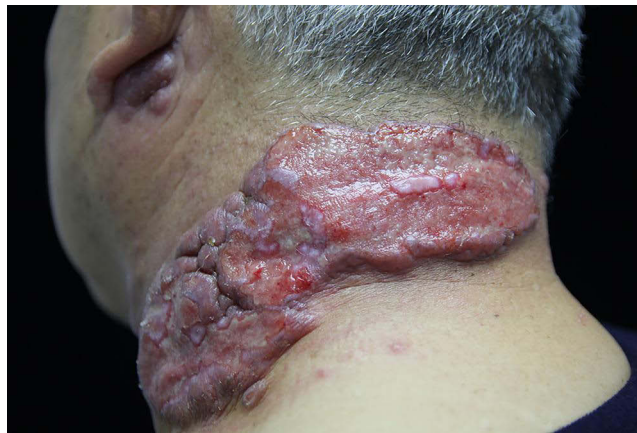

Figure 1 Reddish hypertrophic ulcerative plaque on the left neck and verrucous proliferating nodules of the left ear of the patient before treatment.

A computed tomographic (CT) scan revealed multiple enlarged lymph nodes in bilateral neck, submandibular and mediastinum. Histopathological examination of the lesion on the neck showed necrosis and epithelioid-cell granuloma (Figure 2A) in the dermis, which infiltrates lymphocytes, epithelioid cells and Langhans giant cells (Figure 2B) and negative findings of periodic acid-Schiff, silver and Ziehl-Neelsen stains. Single polymerase chain reaction (PCR) tests for *rpoB* and *hsp65* genes of the skin lesions did not identify *Mycobacterium tuberculosis* until nested PCR for the same genes were performed. Tissue cultures from the lesions grew caseous yellow colonies at 37°C in Löwenstein–Jensen medium after 40 days. The isolate's 16S ribosomal RNA and *hsp65* gene sequence were 100% homologous to *Mycobacterium tuberculosis* strain FDAARGOS_756.

The patient was eventually diagnosed with lupus vulgaris. Resistance testing showed that the pathogen was sensitive to isoniazid, rifampicin, ethambutol, streptomycin and pyrazinamide.

The patient received the antituberculosis regimen including rifampin, isoniazid, ethambutol, pyrazinamide for two months followed by isoniazid and rifampicin for 4 months (2HRZE/4HR). After six months of follow-up, the lesions were almost completely cleared, leaving residual scar and hyperpigmentation (Figure 3) and the enlarged lymph nodes were smaller than before on CT scan with no adverse effects during treatment.

Discussion

Lupus vulgaris is a common chronic paucibacillary form of CTB. It can occur at any age and is noninfectious. Arora et al recently reported an unusual case of a mother and child suffering from lupus vulgaris at the same time.² The cause of CTB in this patient may be the transmission of TB to the skin after previous self-infection, or direct inoculation of *Mycobacterium tuberculosis* or *Mycobacterium bovis* bacillus Calmette–Guérin (BCG), and direct inoculation is more likely.³ It often presents as small reddish-brown flat patches with a soft texture at first and then gradually progresses. Complications such as scar atrophy and tissue destruction may occur. Disseminated lesions are rare and usually associated with active tuberculosis or immunosuppression. The diagnosis of lupus vulgaris is often challenging due to varied clinical presentations. Lupus vulgaris has been reported to be misdiagnosed as mycosis fungoides,⁴ leishmaniasis,⁵ cutaneous malignancy,⁶ hemangioma⁷ etc. The patient was initially misdiagnosed with sarcoidosis, which, and leprosy, are exactly two chief diseases in diagnostic difficulty to distinguish. Sammain et al reported a case of lupus vulgaris, which is misdiagnosed as sarcoidosis, more than 20 years after onset.⁸ Misdiagnosis of CTB or delay in treatment can lead to persistence and expansion of lesions, causing transmission, and even malignant changes in longstanding lesions.⁹

T-SPOT.TB, a type of interferon-gamma release assay, is based on interferon-gamma (IFN- γ) secretion by lymphocytes exposed to *M. tuberculosis*-specific antigens: early secreted antigenic target 6 (ESAT-6) and culture filtrate protein 10 (CFP-10). T-SPOT.TB is usually positive in *M. tuberculosis* infected individuals with high sensitivity and specificity to aid in diagnosis.¹⁰ However, repeated PPD and T-SPOT.TB in this immunocompetent patient were

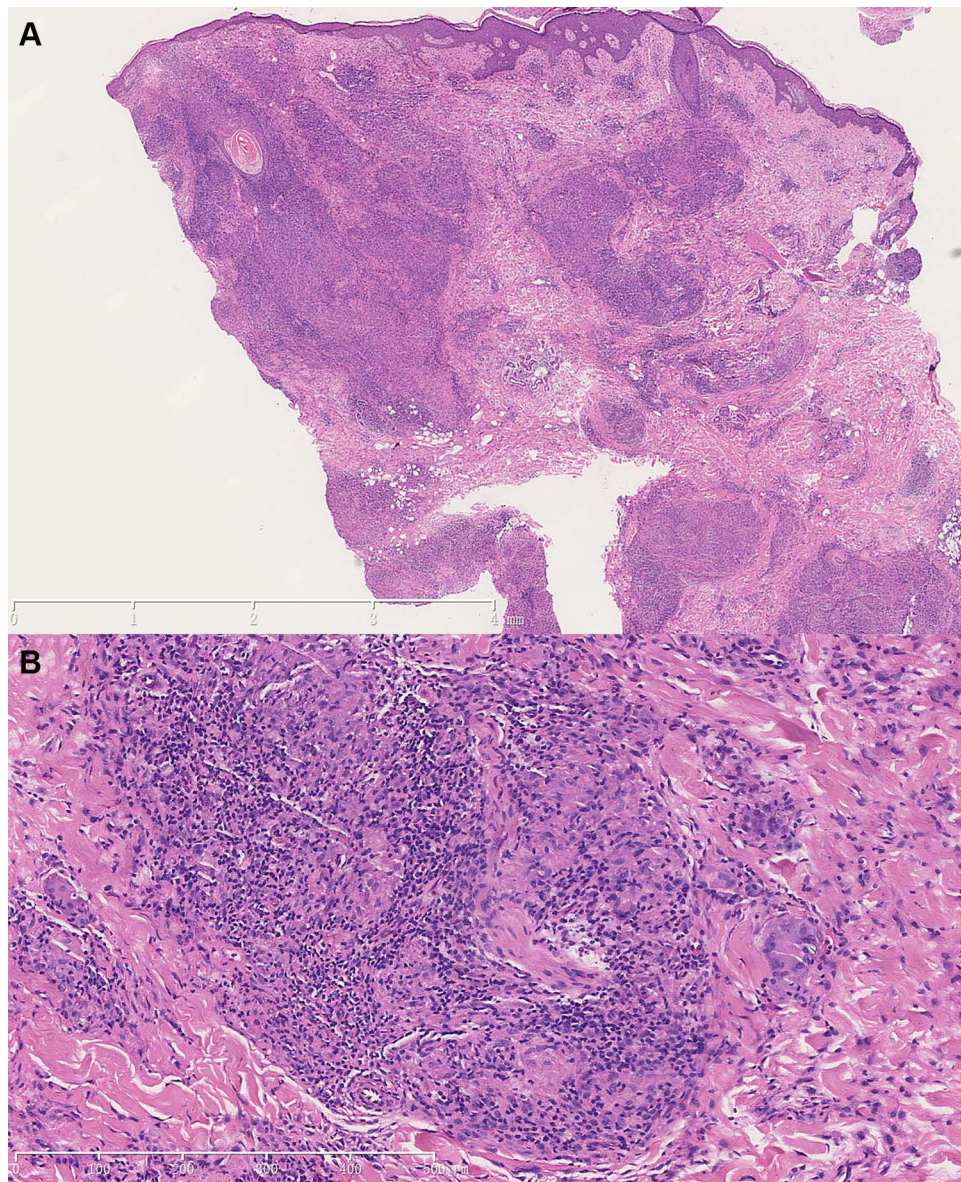


Figure 2 Hematoxylin and eosin staining of skin biopsy specimen showed infectious granuloma (A) with necrosis and infiltrates of lymphocytes, epithelioid cells and Langhans giant cells (B) (original magnification: upper panel $\times 12.5$, lower panel: $\times 100$).

negative even though PCR amplification for ESAT-6 and CFP-10 of the colony showed no deletion of these two virulence-related genes. It is reported that the possible reasons for the false negative of T-SPOT.TB are as follows: decreased albumin-globulin ratio, CD4+ and CD8+,¹¹ older age,^{12,13} over-weight (BMI ≥ 25 kg/m) and a longer period of illness before hospitalization (>6 months);¹² HIV co-infection, non-Hispanic white race/ethnicity.¹³ The false-negative results of T-SPOT.TB in our case are possibly due to increased age, long period of disease, and long-term use of steroids and immunosuppressants may also have an effect. An explanation for this association could be the gradual decrease of IFN- γ production that occurs in response to ESAT-6 and CFP-10 with age.^{14,15} Negative results of conventional molecular detection or IGRA can sometimes be misleading like this case. This reminds doctors not to rely too much on IGRA as its negative result does not rule out the diagnosis of CTB. Molecular testing and mycobacterial culture of skin lesions are the gold standard for the diagnosis of CTB. Antituberculosis treatment can be used to help diagnose people with high suspicion.¹⁶ Adjunct testing like FNAC of underlying lymph nodes with AFB stain can also help assist in diagnosis.⁹ Additionally, advanced molecular detection tools like nested or multiplex PCR are very helpful and promising, allowing a rapid diagnosis and early appropriate treatment.

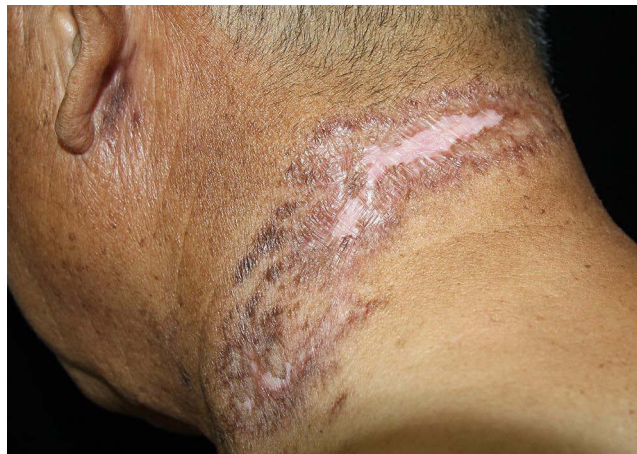

Figure 3 Clinical photographs after six months' antituberculosis treatment: the lesions were almost completely cleared leaving scars and hyperpigmentation after 6 months.

The treatment of CTB is the same as that of other forms of tuberculosis, which is treated with multi drug therapy (MDT) of antituberculosis. It is expected that there will be a clinical response within 4–6 weeks and can be adjusted by culture and drug sensitivity data. Reconstructive surgery may be required for some severe cases of CTB. Adverse effects of drugs should be monitored during follow-up. Besides, it should also be noted that Santesteban et al reported a case of paradoxical responses during treatment of lupus vulgaris.¹⁷ Our experience in this case shows that even for such patients with huge and atypical skin lesions on the premise of long-term application of glucocorticoids and immunosuppressants and negative results of T-SPOT. TB, the application of traditional antituberculosis treatment is still effective.

Ethics Statement

The publications of images were included with the patient's consent.

Consent Statement

Informed consent was provided by the patient for publication of the case. No further institutional approval was required.

Acknowledgments

We thank the patient for allowing us to use his pictures and clinical data. We also thank Dr Jingshu Xiong, Haiqin Jiang, Ying Shi, Wenyue Zhang and Xiaopo Wang from the Institute of Dermatology, Chinese Academy of Medical Sciences & Peking Union Medical College for helping with the pathology and laboratory examinations.

Funding

This work was supported by the grants from Jiangsu Provincial Science and Technology Project (BE2018619).

Disclosure

The authors report no conflicts of interest in this work.

References

1. Franco-Paredes C, Marcos LA, Henao-Martínez AF, et al. Cutaneous mycobacterial infections. *Clin Microbiol Rev.* 2018;32(1):e00069–18. doi:10.1128/CMR.00069-18
2. Arora K, Batra A, Dhanta A, Hazarika N. Lupus vulgaris in a mother and child. *BMJ Case Rep.* 2021;14(3):e240591. doi:10.1136/bcr-2020-240591
3. Walker SL, Lozewicz S, Sood R, Mann TA, Campalani E, Hubbard VG. Lupus vulgaris due to *Mycobacterium bovis* bacillus Calmette-Guérin (BCG) at the site of previous BCG vaccination. *Clin Exp Dermatol.* 2009;34(7):e213–5. doi:10.1111/j.1365-2230.2008.03057.x
4. Kogut M, Hadaschik E, Grabbe S, Andrusis M, Enk A, Hartschuh W. Granulomatous mycosis fungoides, a rare subtype of cutaneous T-cell lymphoma. *JAAD Case Rep.* 2015;1(5):298–302. doi:10.1016/j.jidcr.2015.05.010

5. Landau M, Srebrnik A, Brenner S. Leishmaniasis recidivans mimicking lupus vulgaris. *Int J Dermatol.* 1996;35(8):572–573. doi:10.1111/j.1365-4362.1996.tb03658.x
6. Sirka CS, Rout AN, Kumar P, Purkait S. Lupus vulgaris masquerading as tumorous growth. *Indian J Dermatol Venereol Leprol.* 2021;87(4):562–565. doi:10.25259/IJDVL_1008_20
7. Garg V, Shastri M, Nanda A. Lupus vulgaris uncovered by FNAC after a decade of clinical misdiagnosis as hemangioma. *Indian J Pathol Microbiol.* 2021;64(2):420–422. doi:10.4103/IJPM.IJPM_42_20
8. Sammain A, Jocher A, Bruckner-Tuderman L, Schempp CM. Lupus vulgaris—a case diagnosed more than 20 years after onset. *J Dtsch Dermatol Ges.* 2006;4(11):958–960. doi:10.1111/j.1610-0387.2006.06114.x
9. Kaul S, Jakhar D, Mehta S, Singal A. Cutaneous tuberculosis. Part II: complications, diagnostic workup, histopathological features, and treatment. *J Am Acad Dermatol.* 2022;8. DOI:10.1016/j.jaad.2021.12.064
10. Chen Y, Jiang H, Zhang W, et al. Diagnostic value of T-SPOT.TB test in cutaneous mycobacterial infections. *Acta Derm Venereol.* 2018;98(10):989–990. doi:10.2340/00015555-3011
11. Li K, Yang C, Jiang Z, et al. Quantitative investigation of factors relevant to the T cell spot test for tuberculosis infection in active tuberculosis. *BMC Infect Dis.* 2019;19(1):673. doi:10.1186/s12879-019-4310-y
12. Pan L, Jia H, Liu F, et al. Risk factors for false-negative T-SPOT.TB assay results in patients with pulmonary and extra-pulmonary TB. *J Infect.* 2015;70(4):367–380. doi:10.1016/j.jinf.2014.12.018
13. Nguyen DT, Teeter LD, Graves J, Graviss EA. Characteristics associated with negative interferon- γ release assay results in culture-confirmed tuberculosis patients, Texas, USA, 2013–2015. *Emerg Infect Dis.* 2018;24(3):534–540. doi:10.3201/eid2403.171633
14. Hang NT, Lien LT, Kobayashi N, et al. Analysis of factors lowering sensitivity of interferon- γ release assay for tuberculosis. *PLoS One.* 2011;6(8):e23806. doi:10.1371/journal.pone.0023806
15. Kobashi Y, Mouri K, Yagi S, et al. Clinical utility of the QuantiFERON TB-2G test for elderly patients with active tuberculosis. *Chest.* 2008;133(5):1196–1202. doi:10.1378/chest.07-1995
16. Ramam M, Ramesh V. Trial of antitubercular therapy in the diagnosis of cutaneous tuberculosis. *Am J Dermatopathol.* 2010;32(3):316. doi:10.1097/DAD.0b013e3181c6ed81
17. Santesteban R, Bonaut B, Córdoba A, Yanguas I. Paradoxical reaction to antituberculosis therapy in a patient with lupus vulgaris. *Actas Dermosifiliogr.* 2015;106(2):e7–e12. doi:10.1016/j.ad.2014.05.003

Clinical, Cosmetic and Investigational Dermatology

Dovepress

Publish your work in this journal

Clinical, Cosmetic and Investigational Dermatology is an international, peer-reviewed, open access, online journal that focuses on the latest clinical and experimental research in all aspects of skin disease and cosmetic interventions. This journal is indexed on CAS. The manuscript management system is completely online and includes a very quick and fair peer-review system, which is all easy to use. Visit <http://www.dovepress.com/testimonials.php> to read real quotes from published authors.

Submit your manuscript here: <https://www.dovepress.com/clinical-cosmetic-and-investigational-dermatology-journal>