





# Germinal Centre-Related Primary Cutaneous Diffuse Large B-Cell Lymphoma, Leg Type: Report of a Remission Case

Fang Liu , Fei Qi , Xiuying Zhang, Mei Cao , Shiguang Peng 

Department of Dermatology, Beijing Chaoyang Hospital, Capital Medical University, Beijing, People's Republic of China

Correspondence: Fang Liu, Email [roseliufang@qq.com](mailto:roseliufang@qq.com)

**Abstract:** Primary cutaneous diffuse large B-cell lymphoma, leg type (PCDLBCL-LTs) is a rare and the most aggressive type of the cutaneous B-cell lymphoma with poor prognosis and low therapeutic response. It mostly affects elderly women, with a 5-year survival rate of 50% if not efficiently treated. We present a 28-year-old male patient with indolent PCDLBCL-LT who reached nearly 100% clearance after six rituximab plus cyclophosphamide, doxorubicin, vincristine, and prednisone (R-CHOP) chemotherapy sessions.

**Keywords:** primary cutaneous diffuse large B-cell lymphoma, leg type, rituximab plus cyclophosphamide, doxorubicin, vincristine, prednisone (R-CHOP), remission

## Summary

Primary cutaneous diffuse large B-cell lymphoma, leg type (PCDLBCL-LTs) is a rare and aggressive tumour that mostly affects elderly women. Rituximab plus cyclophosphamide, doxorubicin, vincristine, and prednisone (R-CHOP) has been recognised as the first-line therapy for PCDLBCL-LT worldwide. Limited cases involving Asian patients have been reported. Here, we present a 28-year-old male patient with indolent PCDLBCL-LT who reached nearly 100% clearance after six R-CHOP chemotherapy sessions.

## Introduction

Primary cutaneous B-cell lymphomas (PCBCLs) are a group of rare lymphomas that originate from B-cells, which can be divided into three dominant subtypes: primary cutaneous follicle centre lymphoma (PCFCL), primary cutaneous marginal zone lymphoma, and primary cutaneous diffuse large B-cell lymphoma, leg type (PCDLBCL-LT).<sup>1–3</sup> PCBCLs are extremely rare in Asians, and to the best of our knowledge, there are only few studies that analysed Chinese cases. PCDLBCL-LT is recognised as the most aggressive type of the cutaneous B-cell lymphomas, with poor prognosis and low therapeutic response.<sup>1–3</sup> PCDLBCL-LT most commonly involves the lower leg(s) of older women (male-to-female ratio of 1:2–4; median age in the seventies),<sup>4</sup> with a 5-year survival rate of 50% if not efficiently treated.<sup>2</sup>

The representative clinical presentation is solitary or clustered enlarging plaques on one or both legs. Atypical presentations, including annular erythema and patches, have also been reported. Histopathology usually indicates dense centroblasts and immunoblasts infiltrating the entire dermis with sparse perivascular T cell infiltration. Additionally, markers related to the B-cell lineage, including cluster of differentiation (CD)20, CD79a, paired box 5, and immunoglobulin M, and germinal centre and post-germinal centre markers, including B-cell lymphoma (BCL)2, BCL6, CD10, and multiple myeloma-1 (MUM-1), are positive in most cases. MYC-1 is positive in 65–80% of the cases, and CD30 is rarely expressed by neoplastic cells.<sup>1,4</sup>

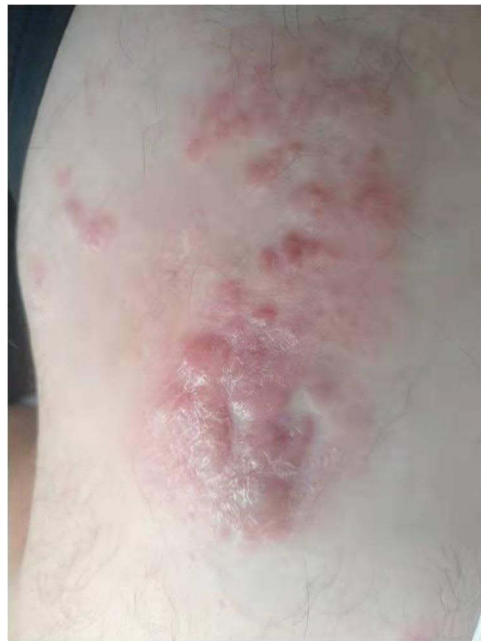While most PCDLBCL-LT cases occur in older female patients, a few cases involve younger patients in their twenties.<sup>5</sup> Here, we present a young man who developed PCDLBCL-LT on his right thigh in his early twenties and completely resolved after R-CHOP therapy.

## Case Presentation

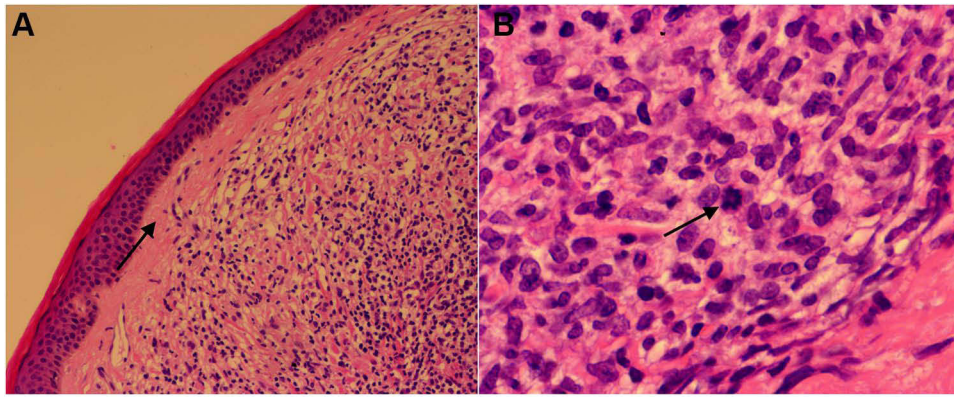
A 28-year-old male patient presented to our clinic on July 22, 2019 with multiple asymptomatic coalescing scarlet plaques on his lateral right thigh. He noticed a single, painless, warty lesion with a slight tingling sensation, which enlarged during a 5-year period. The patient had no history of arthralgia or myalgia. The patient was afebrile, and lymphadenopathy was not observed. A complete skin examination demonstrated that he was otherwise healthy, but a cluster of 12 cm × 12 cm, erythematous infiltrated consolidated papulonodules were discovered on the extensor surface of his proximal right lower extremity (Figure 1).

Excisional skin biopsy demonstrated a condensed disseminated infiltration of lymphocytes in the entire dermis with a granular zone between the epidermis and dermis (Figure 2A). Clustered atypical cells and abundant neoplastic immunoblasts and centroblasts can be seen in the dermis (Figure 2B). Immunohistochemical staining showed that the tumour cells expressed diffuse positivity for B-cell markers, including CD20 (Figure 3A) and CD79a (Figure 3B). CD3, Bcl-2 (Figure 3C), Bcl-6 (Figure 3D), CD5, CD10, CD30, MYC, and Ki-67 also showed positive expression. MUM-1 was negative (Figure 3E). These results confirmed the diagnosis of diffuse large B-cell lymphoma. To exclude extracutaneous involvement, positron emission tomography-computed tomography (PET-CT) was performed, which showed increased metabolic rate in the lower part of the right thigh, which supported the diagnosis of PCDLBCL-LT.

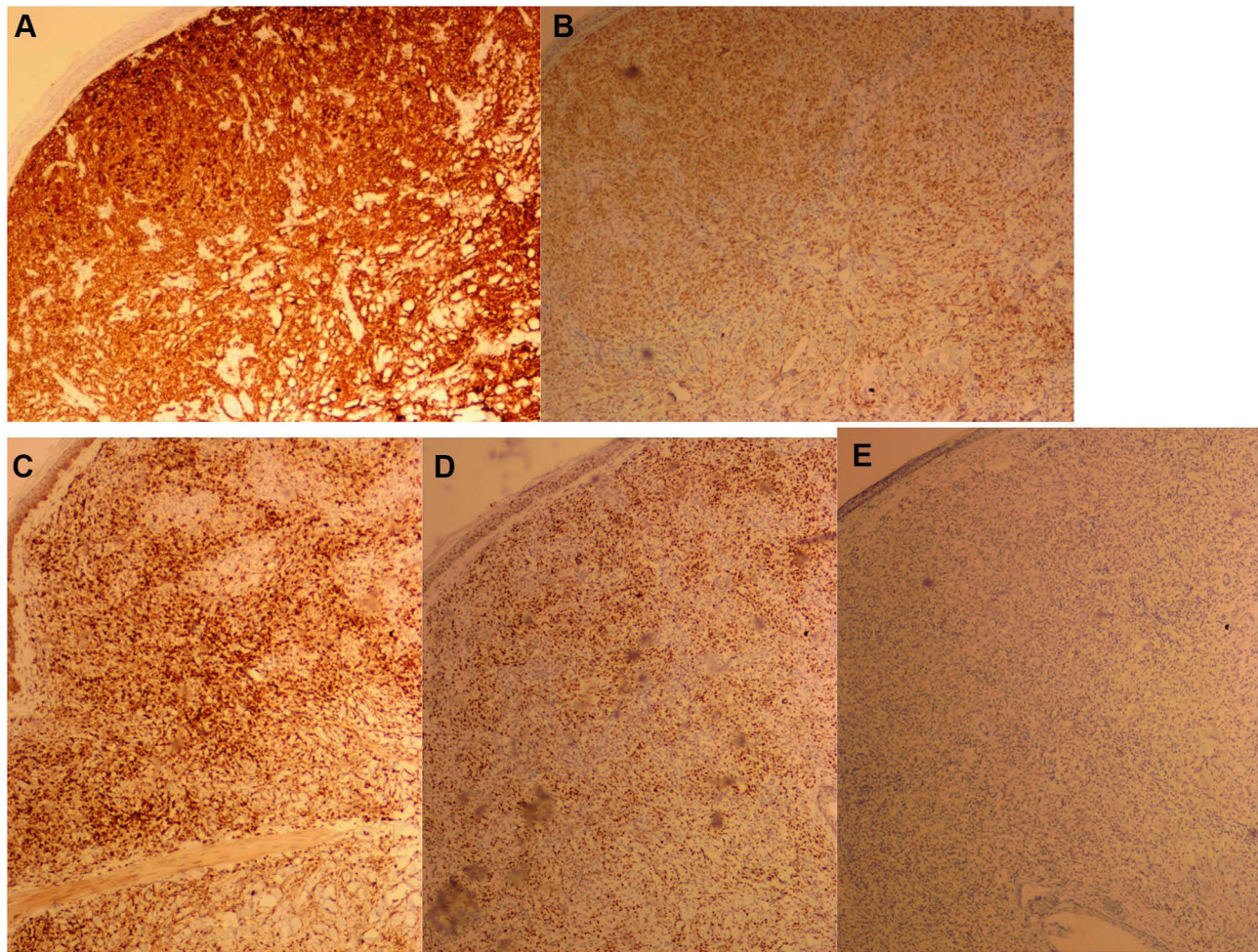
The patient was referred to an oncologist for a chemotherapy plan; six treatment sessions of R-CHOP therapy were carried out. Follow-up at the end of each chemotherapy session and every 6 months after the chemotherapy ceased was conducted. Nearly 100% remission of the lesion was achieved after the sixth treatment session (Figure 4). No notable signs of recurrence or metastasis in both skin examination and PET-CT screening were observed at the sixth month routine post-chemo visit.



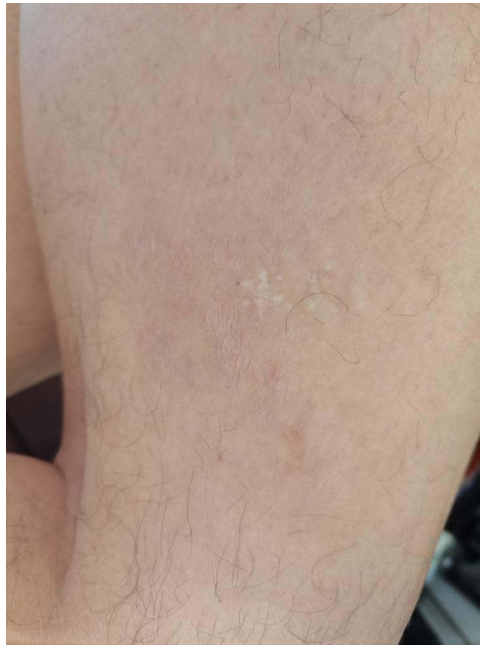**Figure 1** Image before treatment. A 12 cm×12 cm cluster of erythematous infiltrated consolidated papulonodules presented on the extensor surface of the patient's proximal lower right extremity.



**Figure 2** (A) Granz zone can be seen between the epidermis and dermis (arrow indication). A condensed disseminated infiltration of lymphocytes in the entire dermis (hematoxylin–eosin, original magnification: 40×). (B) Atypical cells and abnormal mitosis of large cells can be seen (hematoxylin–eosin, original magnification: 400×).



**Figure 3** Immunohistochemistry stain showed CD20 (A), CD79a (B), Bcl-2 (C), Bcl-6 (D) positivity, MUM-1 negativity (E).



**Figure 4** Six months after the six chemotherapy sessions, the skin lesions disappeared completely.

## Discussion

Here, we report a relatively indolent case of a young male patient whose lesion appeared 5 years before he sought medical care. The lesion did not have the characteristic fast, invasive, and poor prognostic nature of the typical PCDLBCL-LT, which was especially rare and easy to misdiagnose. Since this patient's first hospital visit was 5 years after disease onset, the aggressive character of the disease was observed. A whole-body PET-CT scan and excisional biopsy were performed and showed that the lesions constricted to the right thigh skin, and no extracutaneous metastasis was noted.

While many published studies have shown that tumour cells in DLBCL can co-express MUM1 and Bcl-6, 10, this case demonstrated negative MUM-1 expression. According to CD10, Bcl-6, and MUM-1 expression, DLBCL is sub-classified into the germinal centre (GC) B-cell like and non-GC subtypes.<sup>6</sup> A high proportion of non-GC subtype cases express MUM1, indicating poor prognosis, which is correlated to our case. The present lesion with negative MUM1 expression did not show the characteristic fast, invasive, and poor prognostic nature of the typical PCDLBCL-LT, which was especially rare and easily to misdiagnose, but showed a relatively good response to R-CHOP.

R-CHOP is recognised as the most efficient therapy for PCDLBCL-LT.<sup>1-4,7</sup> A French study reported a significant improvement in 3- and 5-year survival rates after treatment with a combination of rituximab and polychemotherapy.<sup>8</sup>

Notably, the R-CHOP regimen worked well in this patient, resulting in complete tumour subsidence. Although no recurrence was found during the sixth month revisit after chemotherapy was completed, close follow-up is still needed to prevent recurrence in the future.

## Ethical Statement

The procedures and medications performed in this case were approved by the Ethics Committee of Beijing Chaoyang Hospital, Capital Medical University. A signed consent was obtained from the patient for the publication of the case details accompanying images.

## Funding

There is no funding to report.

## Disclosure

The authors report no conflicts of interest in this work.

## References

1. Willemze R, Cerroni L, Kempf W, et al. The 2018 update of the WHO-EORTC classification for primary cutaneous lymphomas. *Blood*. 2019;133(16):1703–1714. doi:10.1182/blood-2018-11-881268
2. Fava P, Rocuzzo G, Alberti-Violetti S, et al. Cutaneous B-cell lymphomas: update on diagnosis, risk-stratification, and management. *Presse Med*. 2022;51(1):104109. doi:10.1016/j.lpm.2022.104109
3. Vitiello P, Sica A, Ronchi A, et al. Primary cutaneous B-cell lymphomas: an update. *Front Oncol*. 2020;10:651. doi:10.3389/fonc.2020.00651
4. Hristov C. Primary cutaneous diffuse large B-cell lymphoma, leg type: diagnostic considerations. *Arch Pathol Lab Med*. 2012;136(8):876–881. doi:10.5858/arpa.2012-0195-RA
5. Suárez AL, Querfeld C, Horwitz S, et al. Primary cutaneous B-cell lymphomas: part I. Clinical features, diagnosis, and classification. *J Am Acad Dermatol*. 2013;69:329– e1. doi:10.1016/j.jaad.2013.06.011
6. Naresh KN. MUM1 expression dichotomises follicular lymphoma into predominantly, MUM1-negative low-grade and MUM1-positive high-grade subtypes. *Haematologica*. 2007;92:267–268. doi:10.3324/haematol.10682
7. Kraft RM, Ansell SM, Villasboas JC, et al. Outcomes in primary cutaneous diffuse large B-cell lymphoma, leg type. *Hematol Oncol*. 2021;39(5):658–663. doi:10.1002/hon.2919
8. Grange F, Joly P, Barbe C, et al. Improvement of survival in patients with primary cutaneous diffuse large B-cell lymphoma, leg type, in France. *JAMA Dermatol*. 2014;150:535–541. doi:10.1001/jamadermatol.2013.7452

Clinical, Cosmetic and Investigational Dermatology

Dovepress

**Publish your work in this journal**

Clinical, Cosmetic and Investigational Dermatology is an international, peer-reviewed, open access, online journal that focuses on the latest clinical and experimental research in all aspects of skin disease and cosmetic interventions. This journal is indexed on CAS. The manuscript management system is completely online and includes a very quick and fair peer-review system, which is all easy to use. Visit <http://www.dovepress.com/testimonials.php> to read real quotes from published authors.

Submit your manuscript here: <https://www.dovepress.com/clinical-cosmetic-and-investigational-dermatology-journal>