

A Rare Case of Co-Infection with *Nocardia farcinica*, *Pneumocystis jirovecii*, and *Aspergillus fumigatus* Due to Tooth Extraction in a Mildly Immunosuppressed Patient

Guo Jinlin^{1,*}, Song Shaohui^{2,*}, Zhang Wenjun³, Cai Xinfeng⁴

¹Department of Pharmacy, Shanxi Provincial People's Hospital, Taiyuan, People's Republic of China; ²Department of Pharmacy, The Maternal and Child Health Hospital of Dadukou District of Chongqing City, Chongqing, People's Republic of China; ³Department of Pharmacy, Second Hospital of Shanxi Medical University, Taiyuan, People's Republic of China; ⁴Department of Pharmacy, Shanxi Province Cancer Hospital/Shanxi Hospital Affiliated to Cancer Hospital, Chinese Academy of Medical Sciences/Cancer Hospital Affiliated to Shanxi Medical University, Taiyuan, People's Republic of China

*These authors contributed equally to this work

Correspondence: Cai Xinfeng, Shanxi Province Cancer Hospital, Taiyuan, Shanxi, 030012, People's Republic of China, Tel +86-18835167718, Email caixinfeng5236@126.com

Abstract: We report a case of co-infection with *Nocardia farcinica*, *Pneumocystis jirovecii*, and *Aspergillus fumigatus* due to tooth extraction in a mildly immunosuppressed patient. This patient did not respond well to a meropenem-based regimen, and the number of lesions was significantly reduced after switching to imipenem. The patient's trough concentration was insufficient when using conventional doses of voriconazole for the treatment of pulmonary aspergillosis. After adding omeprazole, the concentration reached standard levels and symptoms improved. The patient eventually made a full recovery.

Keywords: *Aspergillus fumigatus*, interaction, intracranial infection, *Nocardia farcinica*, *Pneumocystis jirovecii*, voriconazole

Plain Language Summary

- *Nocardia farcinica*, *Pneumocystis jirovecii*, and *Aspergillus fumigatus* are opportunistic pathogens, and co-infection of these three species is very rare.
- We report a case of co-infection with *Nocardia farcinica*, *Pneumocystis jirovecii*, and *Aspergillus fumigatus* in an immunosuppressed patient.
- This patient did not respond well to a meropenem-based regimen, and the number of lesions was significantly reduced after switching to imipenem.
- For the treatment of *N. farcinica*, especially for intracranial infection, imipenem is superior to meropenem.
- During treatment with voriconazole, if the trough concentration of voriconazole does not reach the target, the concentration can be increased by adding omeprazole.

Introduction

Immunosuppressed patients are prone to opportunistic infections.¹ *Nocardia farcinica*, *Pneumocystis jirovecii*, and *Aspergillus fumigatus* are opportunistic pathogens, and their risk factors include high-dose glucocorticoids or immunosuppressants, AIDS, solid organ transplantation, and hematological tumors.²⁻⁴ The mortality rate of such infections is high, and clinical treatment is a great challenge. Co-infection of these three species has not been reported before. We report a case of successful treatment of intracranial infection with *N. farcinica* combined with pulmonary infection with *P. jirovecii* and *A. fumigatus*.

Case Presentation

A 62-year-old male took dexamethasone tablets (2.25 mg three times per day) and ornidazole tablets (0.5g two times per day) orally after tooth extraction. Ten days later, he developed fever (body temperature of 39°C) accompanied by chills, headache, bloating, tinnitus, and hearing loss. Treatment at the local hospital was not effective, and he was transferred to our hospital three days later. On admission, the patient's body temperature was 38.6°C, blood pressure was 134/74 mmHg, respiration was 16 beats/min, heart rate was 75 beats/min, and he was conscious. Relevant examinations were as follows: white blood cell count of $4.40 \times 10^9/L$, neutrophil percentage of 89.8%, lymphocyte count of $0.17 \times 10^9/L$, CD4+ lymphocyte count of $32/mm^3$, C-reactive protein level of 14.38 mg/L, creatinine level of 37.05 $\mu mol/L$, pH of 7.399, procalcitonin level of 0.123 ng/mL, and 1,3- β -D-glucan level of 253.73 pg/mL. Cranial magnetic resonance imaging (MRI) showed multiple lesions in the brain. Enhanced MRI of the head showed multiple abnormal enhancement shadows in the brain: hematogenous disseminated lesions were possible. Chest computed tomography (CT) showed multiple ground-glass opacities in the anterior segment and lower lobe of the left lung. The patient's cerebrospinal fluid (CSF) had a white blood cell count of $1352 \times 10^6/L$, neutrophil percentage of 92%, glucose level of 0.59 mmol/L, and protein level of 1.48 g/L. Next-generation sequencing (NGS) of the patient's CSF reported 37,235 sequences from *N. farcinica* and 8 sequences from human cytomegalovirus. Blood NGS reported 61 sequences from *Nocardia farcinica*, 543 sequences from human cytomegalovirus, and 8 sequences from *P. jirovecii*. The patient's condition gradually deteriorated, and he developed confusion and respiratory failure, requiring an invasive ventilator to assist breathing. After a week of treatment with meropenem, compound sulfamethoxazole (SMZ), linezolid, and ganciclovir, the patient's symptoms improved slightly and he could breathe independently (Figure 1). On the 18th day, the patient's sputum culture was positive for *A. fumigatus* and lung CT showed new lesions. *N. farcinica* and *P. jirovecii* were not found in the sputum culture and we did not perform NGS again. The doctor administered voriconazole by intravenous drip (400 mg every 12 hours on the first day then 200 mg every 12 hours) to fight infection. The patient showed minimal response for about a week, with occasional hemoptysis, and the voriconazole trough concentration was 0.8 mg/L. We added oral omeprazole to the patient's regimen. On the 31st day, the patient's voriconazole trough concentration was 1.1 mg/L, and the blood no longer appeared in the sputum. CT showed that the lesions were absorbed better than before. The patient still had occasional headaches. On the 35th day, head MRI still revealed multiple infection lesions, similar to previous scans (Figure 2). We replaced meropenem with imipenem. On the 70th day, head MRI revealed a significantly reduced number of lesions. On the 78th day, the patient was transferred to a local hospital for continued treatment, and the treatment plan was changed to SMZ combined with linezolid, amoxicillin, and clavulanate potassium. The patient fully recovered after six months of treatment.

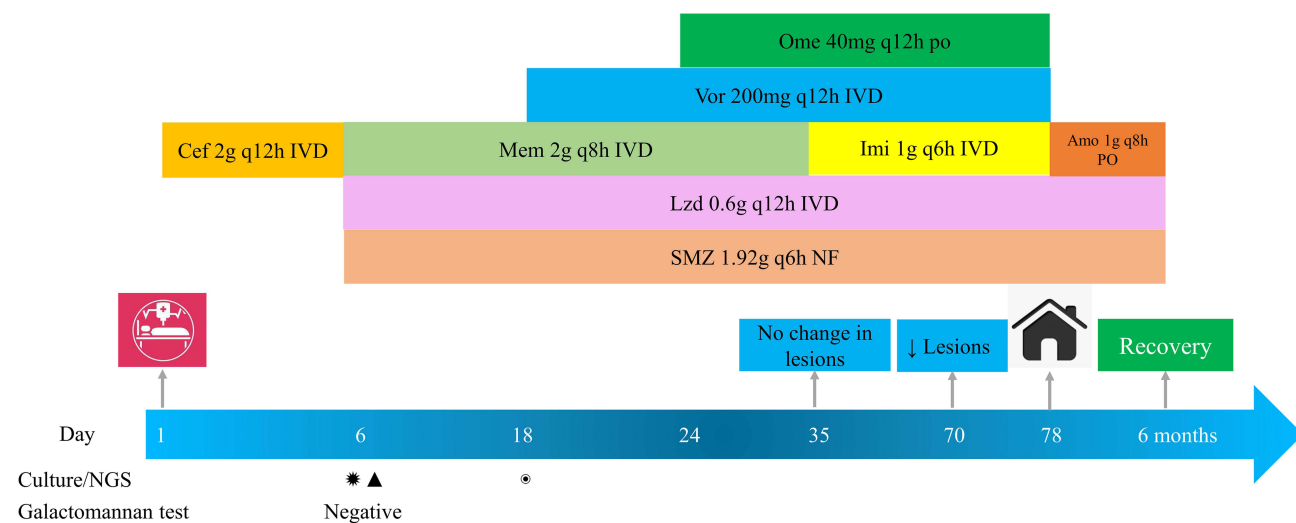


Figure 1 Treatment timeline. *: *Nocardia farcinica*; ▲: *Pneumocystis jirovecii*; and ⊙: *Aspergillus fumigatus*.

Abbreviations: Cef, Ceftriaxone; Mem, meropenem; Lzd, linezolid; SMZ, compound sulfamethoxazole tablets; Ome, omeprazole tablets; Imi, Imipenem; Vor, voriconazole; Amo, amoxicillin-clavulanate potassium; PO, oral; NF, nasal feeding; IVD, intravenous drip; q8h, every eight hours; q6h, every 6 hours; q12h, every 12 hours; NGS, metagenomics next-generation sequencing.

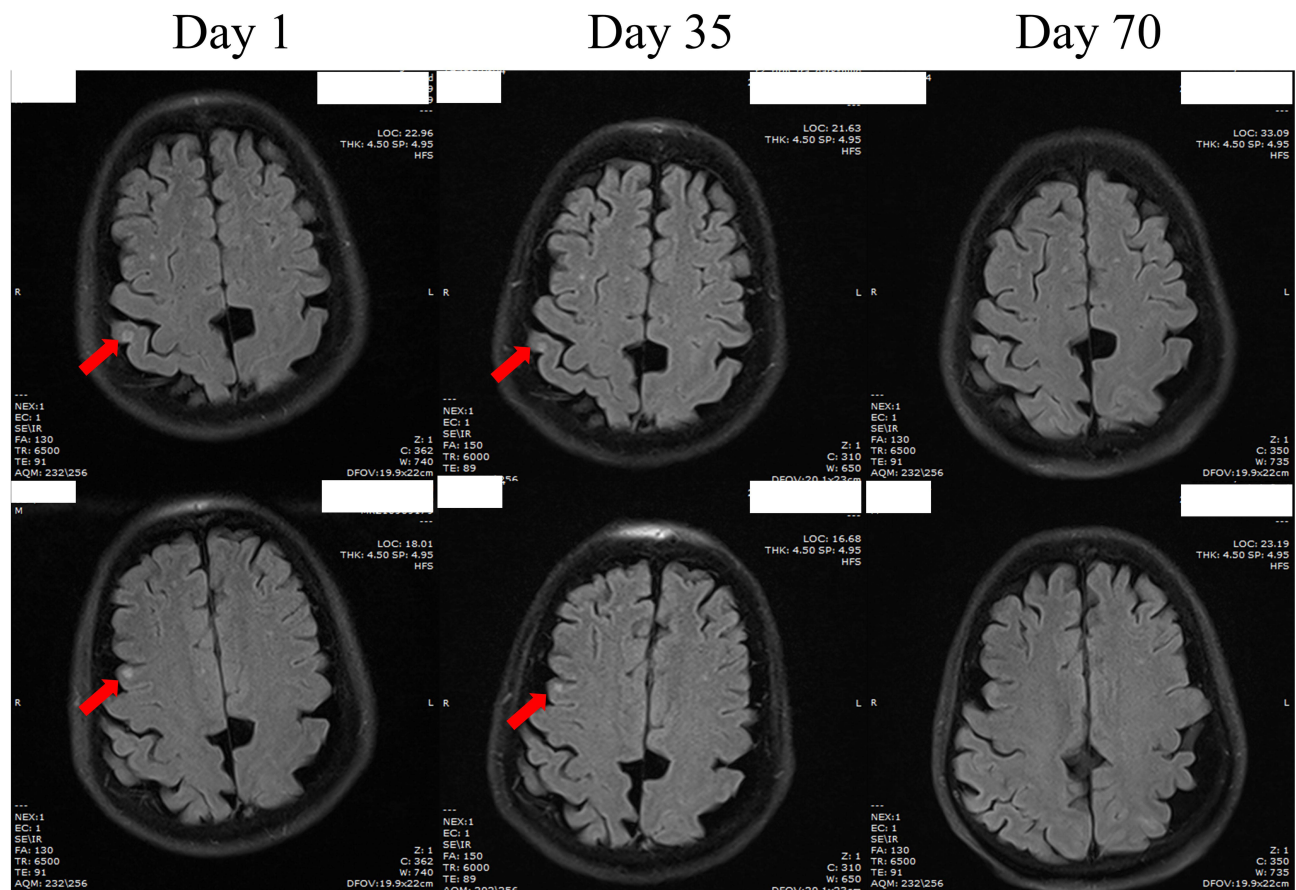


Figure 2 Magnetic resonance imaging scan of the patient.

Discussion

To the best of our knowledge, this is the first report of an immunocompromised patient with *N. farcinica*, *P. jirovecii*, and *A. fumigatus* co-infection. The patient presented with headache and hearing loss, and multiple lesions were observed on head MRI, which is indicative of intracranial infection. The number of sequences from *N. farcinica* in the patient's CSF was very high and CSF examination showed *N. farcinica* infection in the patient's brain. The patient's CSF examination was consistent with purulent meningitis.⁵

The patient had respiratory dysfunction and low immune function; the CD4⁺ lymphocyte count was only 32/mm³, ground-glass shadows could be seen on chest CT, sequences from *P. jirovecii* were detected in the patient's blood and 1,3-β-D-glucan levels were as high as 253.73 pg/mL. 1,3-β-D-glucan is an antigenic component of the cell wall of many fungi, including *P. jirovecii*. It can only be used for auxiliary diagnosis of *P. jirovecii* due to lack of specificity.^{6,7} Morjaria's⁸ study found that 1,3-β-D-glucan ≥ 200 pg/mL had a sensitivity of 70%, specificity of 100%, positive predictive value of 100% for *P. jirovecii*. So we believe that the patient in the present case can be diagnosed with *P. jirovecii* pneumonia.^{4,9} The patient's galactomannan test was negative, and initially he did not use drugs for *Aspergillus*, but the patient's dyspnea was relieved after being treated for *N. farcinica* and *P. jirovecii*, so we believe that the patient's *Aspergillus* infection is a secondary infection.

Using the search terms *N. farcinica* and *P. jirovecii* on PubMed, the co-infection of *Nocardia* and *P. jirovecii* was found to be very rare and only one report describe this kind of infection and the patient was on SMZ based treatment.¹⁰ SMZ is the main treatment for *Nocardia* and *P. jirovecii*. Amikacin, imipenem, meropenem, linezolid, and amoxicillin-clavulanate potassium are all active against *N. farcinica*. If dissemination or central nervous system infection occurs, at least two drugs should be selected for treatment.¹¹ However, amikacin cannot reach an effective concentration intracranially, but imipenem is clinically effective and its activity is stronger than that of meropenem and linezolid can achieve a high intracranial concentration and can

be used for severe infections.¹² Imipenem can maintain higher concentrations intracranially than meropenem in cerebrospinal fluid and is four times more active against *Nocardia*.^{13,14} The patient's initial treatment with a meropenem-based regimen for one month was ineffective, and a month after imipenem was substituted, the lesions were significantly reduced, proving that imipenem is superior to meropenem in the treatment of intracranial infection with *N. farcinica*.

On the 18th day, the patient's sputum culture was positive for *A. fumigatus*, and CT showed a new lesion. The doctor considered fungal infection and initiated voriconazole for treatment. However, during treatment, the patient occasionally had blood in the sputum, and chest CT showed that the infection was still progressing. The voriconazole trough concentration was 0.8 mg/L. According to guidelines and previous reports, the trough concentration of voriconazole should be maintained between 1 and 6 mg/L.^{15,16} Therefore, the poor antifungal effect observed in patients is likely related to the insufficient concentration of voriconazole, but voriconazole is very expensive and the treatment course for fungal infections is relatively long so patients may not be able to afford higher doses. The label of voriconazole states that CYP450 inhibitors such as omeprazole and esomeprazole will lead to an increase in voriconazole concentration.¹⁷ Therefore, we added omeprazole to the patient's treatment regimen. After three days, the patient's voriconazole trough concentration reached the treatment standard, and the patient's symptoms gradually improved. After about two months of voriconazole treatment, it was discontinued. Therefore, we believe that for patients with insufficient voriconazole concentrations at conventional doses, the voriconazole concentration can be increased by adding omeprazole.

There were some limitations in this study. Our microbiology laboratory failed to culture *Nocardia* and *P. jirovecii*, and we were unable to perform drug susceptibility testing for *Aspergillus*. Therefore, the drug susceptibility to these three pathogens can only be based on previous literature reports. Considering the problem of fungal resistance, drug susceptibility testing should be performed before using triazoles and the treatment strategy with voriconazole is only applicable in MIC \leq 1 ug/mL for *Aspergillus*.

Conclusion

N. farcinica, *P. jirovecii* and *A. fumigatus* are opportunistic pathogens, and co-infection of these three species is very rare. These pathogens are usually associated with strong, long-lasting immunosuppressive regimens, but the tooth extraction-associated incident described in this report highlights the need to pay attention even to such inconspicuous cases. For the treatment of *N. farcinica*, especially for intracranial infection, imipenem is superior to meropenem. During treatment with voriconazole, if the trough concentration of voriconazole does not reach the target, the concentration can be increased by adding omeprazole.

Data Sharing Statement

The datasets generated and/or analyzed during the current study are not publicly available since the patient's medical records and data are private, but can be made available from the corresponding author on reasonable request under the consent from the patient.

Compliance with Ethics Guidelines

This study was conducted following the legal requirements and the Declaration of Helsinki and its subsequent amendments. Informed consent for publication was obtained from the patient. According to the hospital protocol, no formal ethics approval was required for this study.

Acknowledgments

We would like to thank the patient for their approval of this paper.

Funding

There is no funding to report.

Disclosure

The authors declare that they have no competing interests.

References

1. Wang JGL, Xu YN. Risk factor analysis of respiratory tract infection in elderly patients in a tertiary grade A hospital cadre ward. *Med J Chin PLA.* 2020;38(8):41–43.
2. Abreu C, Rocha-Pereira N, Sarmento A, Magro F. Nocardia infections among immunomodulated inflammatory bowel disease patients: a review. *World J Gastroenterol.* 2015;21(21):6491–6498. doi:10.3748/wjg.v21.i21.6491
3. Patterson TF, Thompson GR, Denning DW, et al. Practice guidelines for the diagnosis and management of aspergillosis: 2016 update by the Infectious Diseases Society of America. *Clin Infect Dis.* 2016;63(4):e1–e60. doi:10.1093/cid/ciw326
4. Lagrou K, Chen S, Masur H, et al. Pneumocystis jirovecii disease: basis for the revised EORTC/MSGERC invasive fungal disease definitions in individuals without human immunodeficiency virus. *Clin Infect Dis.* 2021;72(Suppl 2):S114–S120. doi:10.1093/cid/ciaa1805
5. Tunkel AR, Hasbun R, Bhimraj A, et al. 2017 Infectious Diseases Society of America's Clinical Practice Guidelines for healthcare-associated ventriculitis and meningitis. *Clin Infect Dis.* 2017;64(6):e34–e65. doi:10.1093/cid/ciw861
6. Karageorgopoulos DE, Qu JM, Korbila IP, Zhu YG, Vasileiou VA, Falagas ME. Accuracy of beta-D-glucan for the diagnosis of Pneumocystis jirovecii pneumonia: a meta-analysis. *Clin Microbiol Infect.* 2013;19(1):39–49. doi:10.1111/j.1469-0691.2011.03760.x
7. Theel ES, Jespersen DJ, Iqbal S, et al. Detection of (1, 3)-beta-D-glucan in bronchoalveolar lavage and serum samples collected from immunocompromised hosts. *Mycopathologia.* 2013;175(1–2):33–41. doi:10.1007/s11046-012-9579-y
8. Morjaria S, Frame J, Franco-Garcia A, Geyer A, Kamboj M, Babady NE. Clinical performance of (1,3) Beta-D glucan for the diagnosis of pneumocystis pneumonia (PCP) in cancer patients tested with PCP polymerase chain reaction. *Clin Infect Dis.* 2019;69(8):1303–1309. doi:10.1093/cid/ciy1072
9. Sax PE, Komarow L, Finkelman MA, et al. Blood (1->3)-beta-D-glucan as a diagnostic test for HIV-related Pneumocystis jirovecii pneumonia. *Clin Infect Dis.* 2011;53(2):197–202. doi:10.1093/cid/cir335
10. Hou J, Cao J, Tan P, Yu Y. Pneumocystis jirovecii pneumonia, Nocardia brasiliensis, and Mycobacterium tuberculosis co-infection in a myasthenia gravis patient: a case report. *Medicine.* 2021;100(1):e24245. doi:10.1097/MD.00000000000024245
11. Restrepo A, Clark NM. Infectious diseases community of practice of the American Society of T. Nocardia infections in solid organ transplantation: guidelines from the infectious diseases community of practice of the American Society of Transplantation. *Clin Transplant.* 2019;33(9):e13509. doi:10.1111/ctr.13509
12. John G, Bartlett PGA, Paul A. *The Johns Hopkins ABX Guide.* Beijing: Scientific and Technical Documentation Press; 2012.
13. Cercenado E, Marin M, Sanchez-Martinez M, Cuevas O, Martinez-Alarcon J, Bouza E. In vitro activities of tigecycline and eight other antimicrobials against different Nocardia species identified by molecular methods. *Antimicrob Agents Chemother.* 2007;51(3):1102–1104. doi:10.1128/AAC.01102-06
14. David N, Gilbert HFC, Michael S. *The Sanford Guide to Antimicrobial Therapy 2020.* 50 ed. Beijing: PEKING UNION MEDICAL COLLEGE PRESS; 2021.
15. Park WB, Kim NH, Kim KH, et al. The effect of therapeutic drug monitoring on safety and efficacy of voriconazole in invasive fungal infections: a randomized controlled trial. *Clin Infect Dis.* 2012;55(8):1080–1087. doi:10.1093/cid/cis599
16. John J, Loo A, Mazur S, Walsh TJ. Therapeutic drug monitoring of systemic antifungal agents: a pragmatic approach for adult and pediatric patients. *Expert Opin Drug Metab Toxicol.* 2019;15(11):881–895. doi:10.1080/17425255.2019.1671971
17. Chen K, Zhang X, Ke X, Du G, Yang K, Zhai S. Individualized medication of voriconazole: a practice guideline of the division of therapeutic drug monitoring. Chinese Pharmacological Society. *Ther Drug Monit.* 2018;40(6):663–674. doi:10.1097/FTD.0000000000000561

Infection and Drug Resistance

Dovepress

Publish your work in this journal

Infection and Drug Resistance is an international, peer-reviewed open-access journal that focuses on the optimal treatment of infection (bacterial, fungal and viral) and the development and institution of preventive strategies to minimize the development and spread of resistance. The journal is specifically concerned with the epidemiology of antibiotic resistance and the mechanisms of resistance development and diffusion in both hospitals and the community. The manuscript management system is completely online and includes a very quick and fair peer-review system, which is all easy to use. Visit <http://www.dovepress.com/testimonials.php> to read real quotes from published authors.

Submit your manuscript here: <https://www.dovepress.com/infection-and-drug-resistance-journal>