

Gilteritinib Affects the Selection of Dominant Clones in Clonal Hematopoiesis: Sequential Genetic Analysis of an *FLT3*-ITD Positive AML Patient with Long-Term Gilteritinib Therapy

Seiichiro Katagiri¹, Nahoko Furuya¹, Daigo Akahane¹, SungGi Chi², Yosuke Minami², Yuka Harada³, Hironori Harada⁴, Akihiko Gotoh¹

¹Department of Hematology, Tokyo Medical University, Tokyo, Japan; ²Department of Hematology, National Cancer Center Hospital East, Chiba, Japan; ³Department of Clinical Laboratory, Tokyo Metropolitan Cancer and Infectious Diseases Center Komagome Hospital, Tokyo, Japan; ⁴Laboratory of Oncology, School of Life Sciences, Tokyo University of Pharmacy and Life Sciences, Tokyo, Japan

Correspondence: Seiichiro Katagiri, Department of Hematology, Tokyo Medical University, 6-7-1 Nishishinjuku, Shinjuku-ku, Tokyo, 160-0023, Japan, Tel +81-3-3342-6111 (ext. 5895), Fax +81-3-5381-6651, Email patchsei@yahoo.co.jp

Abstract: We performed sequential molecular analyses of a 75-year-old woman with *de novo* *FLT3*-ITD positive acute myeloid leukemia (AML) who had received gilteritinib therapy for 43 months. At the time of diagnosis, her karyotype was normal; however, *FLT3*-ITD, *NPM1*, *DNMT3A*, and *IDH2* mutations were detected. She received induction therapy with daunorubicin and cytarabine and achieved hematological complete remission (HCR). After attaining HCR, she underwent consolidation therapy with azacytidine or cytarabine, aclarubicin, and granulocyte-colony stimulating factor. However, AML relapsed eight months after the first HCR. *FLT3*-ITD and *NPM1* mutations were persistently positive, and the patient received gilteritinib therapy. Although the *FLT3*-ITD clone was not detected during gilteritinib treatment, a clone harboring monosomy 7 and *CBL* mutations emerged. Bone marrow examinations at 15, 24, and 32 months after gilteritinib treatment revealed multi-lineage blood cell dysplasia without an increase in myeloblasts. After 33 months of treatment, gilteritinib was discontinued for two months because of ileus development, and the *FLT3*-ITD clone was detected again. Gilteritinib treatment was restarted, and *FLT3*-ITD became negative. Our analysis demonstrated that: (1) hematopoiesis derived from gilteritinib-resistant clones was generated by long-term gilteritinib treatment, and (2) *FLT3*-ITD clones regained clonal dominance in the absence of *FLT3* inhibition. These findings suggest that gilteritinib affects the selection of dominant clones during clonal hematopoiesis.

Keywords: gilteritinib, *FLT3*-ITD, *CBL*, monosomy 7, clonal hematopoiesis

Introduction

Clonal hematopoiesis is defined as the presence of a population of cells derived from a mutated multipotent stem/progenitor cell harboring a selective growth advantage in the absence of unexplained cytopenia, hematological cancers, or other clonal disorders by the 5th edition of the World Health Organization Classification.¹ It has been reported that clonal hematopoiesis increases the risk of developing myeloid neoplasms such as myelodysplastic syndromes and acute myeloid leukemia (AML).^{2,3}

FMS-like tyrosine kinase 3 (*FLT3*) gene is a receptor-type tyrosine kinase, and in AML, it undergoes internal tandem duplication (ITD) mutation that duplicate and repeat part of the juxta membrane region, and tyrosine kinase domain (TKD) mutations that are point mutations in the kinase region.⁴ In particular, *FLT3*-ITD is an important prognostic factor in AML, and long-term survival is difficult to achieve in *FLT3*-ITD-positive AML patients who cannot undergo hematopoietic stem cell transplantation (HSCT).⁵

Gilteritinib is an oral, potent, selective *FLT3* inhibitor with inhibitory activity against both *FLT3*-ITD and *FLT3*-TKD mutations,⁶ and has shown significant therapeutic efficacy in relapsed refractory *FLT3*-mutated AML.^{6,7} Gilteritinib is

expected to be a therapeutic option for transplant-ineligible patients; however, the effect of long-term administration of gilteritinib on hematopoiesis is unknown. In this study, we analyzed the changes in hematopoietic clones from diagnosis to 43 months after gilteritinib treatment in an older patient with recurrent *FLT3*-ITD positive AML who received long-term administration of gilteritinib.

Case Presentation

A 75-year-old woman with fever was referred to our hospital and diagnosed with AML. Bone marrow (BM) examination revealed myeloperoxidase-positive leukemic cells and extensive BM necrosis (Figure 1A–C). Cytogenetic analysis of 24 metaphases showed a normal karyotype; however, molecular analysis of the patient by next-generation sequencing (NGS) conducted in Hematologic Malignancy (HM)-SCREEN-Japan-01 (UMIN000035233)⁸ identified *FLT3*-ITD, *DNMT3A*, *IDH2*, and *NPM1* mutations (Table 1). She received induction therapy with daunorubicin and cytarabine and achieved hematological complete remission (HCR). She subsequently underwent two courses of azacytidine, followed by three courses of cytarabine, aclarubicin, and granulocyte-colony stimulating factor; however, AML relapsed eight months after the first HCR (Figure 1D–F). Cytogenetic analysis revealed clones containing t(3;5)(p14;p15) (Table 1). *FLT3*-ITD was persistently positive, and she received reinduction therapy with gilteritinib (120 mg/day). The patient achieved complete remission with incomplete count recovery on day 49 after gilteritinib treatment. However, the dose was reduced to 80 mg/day because of cytopenia. Nine months after gilteritinib therapy, her blood count recovered and she achieved a second HCR. BM examination showed no increase in myeloblasts; however, blood cells with multilineage dysplasia were observed. Cytogenetic analysis using fluorescence in situ hybridization (FISH) showed the emergence of a monosomy 7 clone. Molecular analysis of HM-SCREEN-Japan-01 did not detect *FLT3*-ITD or *NPM1* mutations, but a new *Casitas B-cell lymphoma (CBL)* gene mutation was identified (Table 1). She continued gilteritinib treatment, and BM examinations were performed at 15, 24, and 32 months after starting treatment. Each BM examination revealed the continuation of multilineage blood cell dysplasia without an increase in myeloblasts (Figure 1G–I). Cytogenetic analysis of the three specimens showed that monosomy 7 clones gradually expanded. In the molecular analysis, samples taken 15 and 24 months after treatment were subjected to NGS analysis in the HM-SCREEN-Japan-01 study, whereas the samples taken 32 months after treatment were subjected to NGS analysis using the Komagome myeloid panel.⁹ All of which revealed *DNMT3A*, *IDH2*, and *CBL* mutations but not *FLT3*-ITD (Table 1). After 33 months of treatment, gilteritinib was discontinued for two months

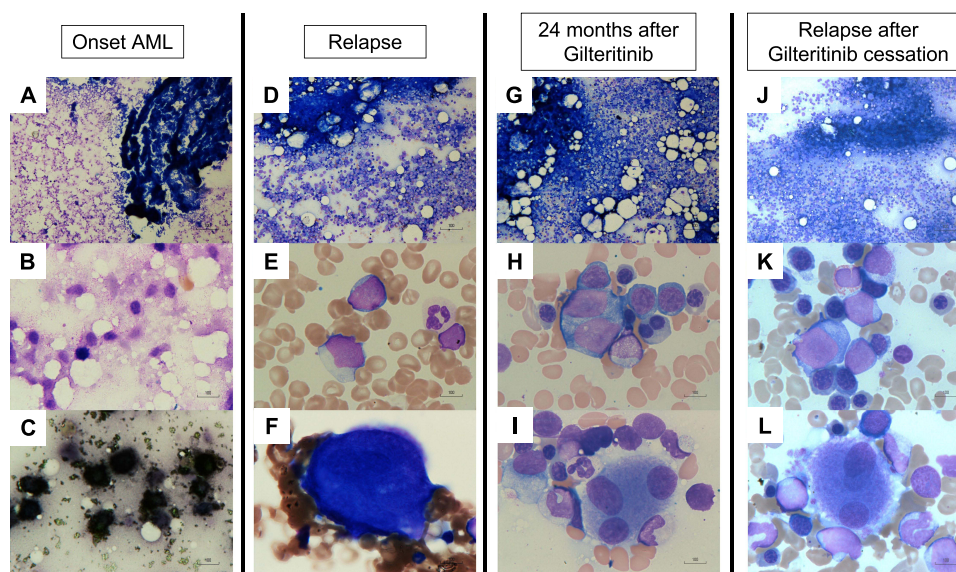


Figure 1 Bone marrow smear at onset of AML, first relapse of AML, 24 months after gilteritinib therapy, and relapse after gilteritinib cessation. (A and B) Wright–Giemsa (WG) staining at onset, showing extensive bone marrow necrosis. (C) Myeloperoxidase (MPO) staining at onset. (D–F) WG staining at first relapse, showing myeloblast increase without blood cell dysplasia. (G–I) WG staining at 24 months after gilteritinib therapy, showing multi-lineage blood cell dysplasia without myeloblast increase. (J–L) WG staining at relapse after gilteritinib cessation (35 months after gilteritinib treatment), showing a repopulation of myeloblasts against the background of multilineage dysplasia. Magnification is 100x for (A, D, G, and J), and 1000x for (B, C, E, F, H, I, K, and L).

Table I Summary of Genome Profiling in a Patient with Long Term Gilteritinib Therapy

BM Sample		Karyotype Analysis		Mutation Analysis	
Phase	BM Blast	Q-banding	Monosomy 7 FISH	FLT3-ITD PCR	NGS
Onset	>90%	46,XX[24]	0%	Positive	DNMT3A R882H
					IDH2 R140Q
					FLT3-ITD
					NPM1 W288fs*12
First Relapse	31.2%	46,XX,t(3;5)(p14;p15)[5]/46,XX[17]	0%	Positive	DNMT3A R882H
					IDH2 R140Q
					FLT3-ITD
					NPM1 W288fs*12
					ATM N567fs*6
9 months after Gilteritinib therapy	8%	46,XX,t(3;5)(p14;p15)[8]/46,XX[1]	46%		DNMT3A R882H
					IDH2 R140Q
					CBL C404Y
15 months after Gilteritinib therapy	4%	46,XX,t(3;5)(p14;p15)[2]/45,XX, idem,-7[3]/45,XX, idem,-7,+mar[3]/46,XX[5]		Negative	DNMT3A R882H
					IDH2 R140Q
					CBL C404Y
24 months after Gilteritinib therapy	4%	46,XX,t(3;5)(p14;p15)[8]/45,XX, idem,-7[5]/46,XX[7]	64%		DNMT3A R882H
					IDH2 R140Q
					CBL C404Y
32 months after Gilteritinib therapy	1.8%	46,XX,t(3;5)(p14;p15) [1]/45,XX, idem,-7[17]/46,XX[2]	81%	Negative	DNMT3A R882H
					IDH2 R140Q
					CBL C404Y
Cessation of Gilteritinib therapy (33–34 months)					
35 months after Gilteritinib therapy	10%	46,XX,t(3;5)(p14;p15),-7[13]/46,XX, idem,+mar[2]/46,XX[5]	70%	Positive	
39 months after Gilteritinib therapy	20%	46,XX,t(2;5)(p14;p15),-7,-14,+mar[1]/44,XX,t(3;5)(p14;p15),-7,-20[1]/44,X,-X,-7[1]/46,XX[1]	81%	Positive	
40 months after Gilteritinib therapy	6%	45,XX,t(3;5)(p14;p15),-7[11]/46,XX, del(1)(q24)[1]/46,XX[7]			FLT3-ITD
					IDH2 R140Q
					CBL C404Y
43 months after Gilteritinib therapy	1.6%	46,XX,t(3;5)(p14;p15),-7[19]/46,XX [1]		Negative	

Abbreviations: BM, bone marrow; FISH, Fluorescence in situ hybridization; PCR, polymerase chain reaction; NGS, next-generation sequencing.

because the patient developed ileus complicated by septic shock. After the cessation of gilteritinib treatment, myeloblasts appeared in the peripheral blood. BM examination revealed 10% myeloblasts (Figure 1J–L), and *FLT3*-ITD was again detected by qualitative polymerase chain reaction (PCR). Gilteritinib treatment was restarted, and the peripheral blood myeloblasts disappeared. Five months after resuming treatment, BM examination showed that the myeloblast ratio had decreased to 6%. NGS performed in the HM-SCREEN-Japan-02 study (UMIN000046371)¹⁰ revealed *FLT3*-ITD, *IDH2*, and *CBL* mutations. However, the allele frequency of *FLT3*-ITD was 1.6%. Eight months after the resumption of treatment, BM examination showed multi-lineage blood cell dysplasia without myeloblast increase, and qualitative PCR demonstrated that *FLT3*-ITD had also become negative.

Discussion

Recently, the influence of chemotherapy on clonal hematopoiesis has been attracted attention. It has been shown that clonal hematopoiesis before chemotherapy is a risk factor for therapy-related myeloid neoplasia.^{11,12}

We observed clonal hematopoiesis in a *FLT3*-ITD-positive AML patient at the time of diagnosis, relapse, and up to 43 months after the administration of gilteritinib. In the ADMIRAL study, eight of 247 patients in a gilteritinib cohort were confirmed to have survived in remission for more than two years without HSCT.⁷ However, most of them (7/8) were under the age of 65 and had a history of transplantation before participating in the study. Gilteritinib therapy can rarely be continued for more than 40 months in older AML patients.

Mutations in *DNMT3A*, *IDH2*, *NPM1*, and *FLT3*-ITD were detected at diagnosis, and *DNMT3A* and *IDH2* were detected in all subsequent samples. Clones with these mutations were considered pre-leukemia clones.

At the time of recurrence after cytotoxic chemotherapy, *NPM1* mutation and *FLT3*-ITD were detected, suggesting that the clone had re-expanded at the time of initial diagnosis. At the time of recurrence, chromosomal analysis revealed a clone of t(3;5)(p14;p15). Following the administration of gilteritinib, clones harboring *NPM1* mutation and *FLT3*-ITD disappeared and a clone with *CBL* mutation emerged. Chromosomal analysis revealed that the clones with t(3;5)(p14;p15) had newly acquired monosomy 7.

CBL has E3 ubiquitin ligase activity and plays an inhibitory role in signal transduction by ubiquitylating activated tyrosine kinase receptors such as *FLT3* and *PDGFR*.¹³ *CBL* mutations in myeloid malignancies are concentrated in the Linker and RING finger domains responsible for E3 ubiquitin ligase activity, impairing its activity.^{13,14} In recent years, activation of the RAS/MAPK pathway has attracted attention as a mechanism of resistance to gilteritinib. McMahon et al reported that 36.6% of 41 cases who resisted gilteritinib therapy showed the emergence of gene mutations related to the RAS/MAPK pathway, including *CBL*, after administration of gilteritinib.¹⁵ Furthermore, Schnittger et al analyzed *CBL* mutations in 636 cases of myelodysplastic syndromes (MDS) and MDS/myeloproliferative neoplasms and reported that *CBL* mutations were associated with monosomy 7 and *TET2* mutation.¹⁶ This patient in the current study had multi-lineage blood cell dysplasia during gilteritinib therapy. These dysplasias are presumed to result from the expansion of gilteritinib-resistant clones with monosomy 7 and *CBL* mutations.

Interestingly, in the current case, the *FLT3*-ITD clone reappeared after the cessation of gilteritinib treatment due to ileus. Furthermore, the reemerging clones remained sensitive to gilteritinib. This observation suggests that the *FLT3*-ITD clone may have higher proliferative potential than the *CBL* mutation/monosomy 7 clone in the absence of *FLT3* inhibitors. We speculated that gilteritinib suppressed long-term *FLT3*-ITD clones, resulting in hematopoietic formation by *CBL*-mutant/monosomy 7 clones.

The present study had some limitations. NGS methods for genetic analysis differ depending on the timing of the BM collection. Therefore, in this case, it may not be possible to accurately compare changes in clone size. The *CBL* mutation/monosomy 7 clone was not detected by NGS or FISH prior to gilteritinib administration. However, it is necessary to evaluate the possibility that this clone existed as a minor clone before the administration of gilteritinib using digital PCR.

Conclusion

The present analysis demonstrated that (1) hematopoiesis derived from gilteritinib-resistant clones was generated in a long-term gilteritinib-treated patient and (2) *FLT3*-ITD clones regained clonal dominance in the absence of *FLT3* inhibition. These findings suggest that gilteritinib affects the selection of dominant clones during clonal hematopoiesis.

Sequential clonal analyses in patients treated with long-term molecular targeted drugs, such as FLT3 inhibitors, are expected to clarify the mechanism by which hematopoietic tumors emerge from clonal hematopoiesis; however, further studies are required.

Consent to Participate

The patient's daughter provided informed consent to publish the patient's case details and any accompanying images.

Author Contributions

All authors made a significant contribution to the work reported, whether that is in the conception, study design, execution, acquisition of data, analysis and interpretation, or in all these areas; took part in drafting, revising or critically reviewing the article; gave final approval of the version to be published; have agreed on the journal to which the article has been submitted; and agree to be accountable for all aspects of the work.

Disclosure

Akihiko Gotoh reports grants, personal fees from Eisai, grants, personal fees from Ono Pharmaceutical, grants, personal fees from Taiho Pharmaceutical, grants, personal fees from Takeda Pharmaceutical, grants, personal fees from Nippon Shinyaku, grants, personal fees from Chugai Pharmaceutical, grants from MSD, grants, personal fees from Otsuka Pharmaceutical, grants, personal fees from Sumitomo Pharma, grants from Bayer, grants, personal fees from Daiichi Sankyo, grants, personal fees from Nihon Pharmaceutical, personal fees from Novartis Pharma, personal fees from Alexion Pharmaceuticals, personal fees from Kyowa Kirin, personal fees from Janssen, personal fees from Pfizer Japan, personal fees from Sanofi, personal fees from PharmaEssentia Japan, outside the submitted work. Yosuke Minami received research funding from Ono, and Honoraria from Bristol-Myers Squibb, Novartis, and Pfizer. Yuka Harada reports grants from JSPS KAKENHI Grant, grants from Clinical Research Fund of Tokyo Metropolitan Government, during the conduct of the study. Part of the NGS assay was supported by a National Cancer Research and Development Expenses Grant. The authors report no other conflicts of interest in this work.

References

1. Khoury JD, Solary E, Abla O, et al. The 5th edition of the world health organization classification of haematolymphoid tumours: myeloid and histiocytic/dendritic neoplasms. *Leukemia*. 2022;36(7):1703–1719. doi:10.1038/s41375-022-01613-1
2. Steensma DP, Bejar R, Jaiswal S, et al. Clonal hematopoiesis of indeterminate potential and its distinction from myelodysplastic syndromes. *Blood*. 2015;126(1):9–16. doi:10.1182/blood-2015-03-631747
3. Abelson S, Collord G, Ng SWK, et al. Prediction of acute myeloid leukaemia risk in healthy individuals. *Nature*. 2018;559(7714):400–404. doi:10.1038/s41586-018-0317-6
4. Yamamoto Y, Kiyoi H, Nakano Y, et al. Activating mutation of D835 within the activation loop of FLT3 in human hematologic malignancies. *Blood*. 2001;97(8):2434–2439. doi:10.1182/blood.V97.8.2434
5. Papaemmanuil E, Gerstung M, Bullinger L, et al. Genomic classification and prognosis in acute myeloid leukemia. *N Engl J Med*. 2016;374(23):2209–2221. doi:10.1056/NEJMoa1516192
6. Perl AE, Martinelli G, Cortes JE, et al. Gilteritinib or chemotherapy for relapsed or refractory FLT3-mutated AML. *N Engl J Med*. 2019;381(18):1728–1740. doi:10.1056/NEJMoa1902688
7. Perl AE, Larson RA, Podoltsev NA, et al. Follow-up of patients with R/R FLT3-mutation-positive AML treated with gilteritinib in the Phase 3 ADMIRAL trial. *Blood*. 2022;139(23):3366–3375. doi:10.1182/blood.2021011583
8. Hosono N, Chi S, Yamauchi T, et al. Clinical utility of genomic profiling of AML using paraffin-embedded bone marrow clots: HM-SCREEN-Japan 01. *Cancer Sci*. 2023;114(5):2098–2108. doi:10.1111/cas.15746
9. Konishi T, Sadato D, Toya T, et al. Impact of gene alterations on clinical outcome in young adults with myelodysplastic syndromes. *Sci Rep*. 2023;13(1):2641. doi:10.1038/s41598-023-29794-4
10. Arai H, Chi S, Utsu Y, et al. A practice-oriented genome profiling study with the novel halo-shape annealing and defer-ligation enrichment (HANDLE) system: HM-screen-JAPAN02. *Blood*. 2022;140(Supplement 1):10722–10724. doi:10.1182/blood-2022-159351
11. Gillis NK, Ball M, Zhang Q, et al. Clonal haemopoiesis and therapy-related myeloid malignancies in elderly patients: a proof-of-concept, case-control study. *Lancet Oncol*. 2017;18(1):112–121. doi:10.1016/S1470-2045(16)30627-1
12. Wong TN, Ramsingh G, Young AL, et al. Role of TP53 mutations in the origin and evolution of therapy-related acute myeloid leukaemia. *Nature*. 2015;518(7540):552–555. doi:10.1038/nature13968
13. Sanada M, Suzuki T, Shih LY, et al. Gain-of-function of mutated C-CBL tumour suppressor in myeloid neoplasms. *Nature*. 2009;460(7257):904–908. doi:10.1038/nature08240

14. Dunbar AJ, Gondek LP, O'Keefe CL, et al. 250K single nucleotide polymorphism array karyotyping identifies acquired uniparental disomy and homozygous mutations, including novel missense substitutions of c-Cbl, in myeloid malignancies. *Cancer Res.* 2008;68(24):10349–10357. doi:10.1158/0008-5472.CAN-08-2754
15. McMahon CM, Ferng T, Canaani J, et al. Clonal selection with RAS pathway activation mediates secondary clinical resistance to selective FLT3 inhibition in acute myeloid leukemia. *Cancer Discov.* 2019;9(8):1050–1063. doi:10.1158/2159-8290.CD-18-1453
16. Schnittger S, Bacher U, Alpermann T, et al. Use of CBL exon 8 and 9 mutations in diagnosis of myeloproliferative neoplasms and myelodysplastic/myeloproliferative disorders: an analysis of 636 cases. *Haematologica.* 2012;97(12):1890–1894. doi:10.3324/haematol.2012.065375

OncoTargets and Therapy

Dovepress

Publish your work in this journal

OncoTargets and Therapy is an international, peer-reviewed, open access journal focusing on the pathological basis of all cancers, potential targets for therapy and treatment protocols employed to improve the management of cancer patients. The journal also focuses on the impact of management programs and new therapeutic agents and protocols on patient perspectives such as quality of life, adherence and satisfaction. The manuscript management system is completely online and includes a very quick and fair peer-review system, which is all easy to use. Visit <http://www.dovepress.com/testimonials.php> to read real quotes from published authors.

Submit your manuscript here: <https://www.dovepress.com/oncotargets-and-therapy-journal>