

Reflectance Confocal Microscopy of Adult Periorificial Dermatitis: A Case Report

Sihao Shen¹, Jiangfeng Feng¹, Xiuzu Song², Wenzhong Xiang²

¹Department of Dermatology, Hangzhou Third People's Hospital, Zhejiang Chinese Medical University, Hangzhou, People's Republic of China;

²Department of Dermatology, Hangzhou Third People's Hospital, Affiliated Hangzhou Dermatology Hospital, Zhejiang University School of Medicine, Hangzhou, People's Republic of China

Correspondence: Wenzhong Xiang, Department of Dermatology, Hangzhou Third People's Hospital; Affiliated Hangzhou Dermatology Hospital, Zhejiang University School of Medicine, Westlake Ave 38, Hangzhou, 310009, People's Republic of China, Tel +86 13588004268, Email xiangwenzhong@126.com

Abstract: Periorificial dermatitis (PD) is an inflammatory disorder of the facial skin that mainly occurs around the mouth and manifests as erythema, papules, pustules, scales and other lesions. Special attention is needed in the clinical diagnosis of PD to distinguish it from acne, seborrheic dermatitis (SD), granulomatous rosacea (GR), sarcoidosis and childhood granulomatous periorificial dermatitis (CGPD). We used reflectance confocal microscopy (RCM) images of a patient with PD to assist in the diagnosis of PD. RCM of PD showed slight oedema of the spinous layer. Numerous dendritic cells, scattered hair follicular keratotic plugging and hair follicle dilatation were observed. The dilation and congestion of superficial dermis blood vessels, an increasing vascular density and accelerated blood flow, and a greater abundance of infiltrated inflammatory cells were also detected.

Keywords: periorificial dermatitis, reflectance confocal microscopy, acne, seborrheic dermatitis, granulomatous rosacea, sarcoidosis, childhood granulomatous periorificial dermatitis

Introduction

Periorificial dermatitis (PD) is an inflammatory disorder of the facial skin that mainly occurs around the mouth and manifests as erythema, papules, pustules, scales and other lesions, most often in women aged 16–50.¹ It was first described by Frumess and Lewis in 1957 as a type of cyclic dermatitis.² To date, the exact pathogenesis of PD is not clear. Common causes include the topical use of glucocorticoids and exaggerated skincare, but other factors, such as bacterial or fungal infection and the application of fluoride toothpaste, are also worth discussing.³

Acne and seborrheic dermatitis (SD) are common and important differential diagnoses of PD. Attention is needed in the diagnosis of PD to distinguish it from these diseases, as well as granulomatous rosacea (GR), sarcoidosis and childhood granulomatous periorificial dermatitis (CGPD).⁴ Clinically, patients tend to refuse skin biopsy; therefore, noninvasive methods for differential diagnosis will be more practical.

Reflectance confocal microscopy (RCM) is a noninvasive imaging method that has been shown to provide sufficient data to support the clinical diagnosis of inflammatory and pigmented skin diseases.⁵ PD is a benign and self-limiting disease; thus, overdiagnosis should be avoided. The combination of RCM with clinical features will facilitate differential diagnosis. RCM does not cause discomfort to the patient and allows repeated examination of the same skin area. Currently, there are no studies on RCM in PD, and we provide a case to fill this research gap.

Case Report

A 25-year-old young woman presented with periorificial erythema papules for one year, with a tight feeling, no itching, and gradual aggravation. The patient denied the use of creams containing steroid hormones and did not use fluoridated toothpaste. Dermatological examination revealed erythema and papules around the wing of the

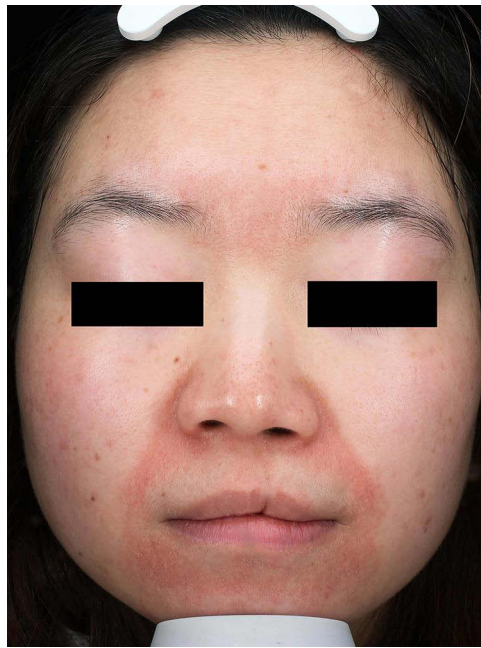

Figure 1 Facial image of the PD patient. Erythema and papules can be seen around the wing of nose and mouth without scales.

nose and mouth without scales. Approximately 5 mm of skin area separated the lesions, and the lip was not invaded (Figure 1). The results of all routine tests were within the normal range.

A trained professional performed RCM imaging on this patient (Vivascope 1500[®]; Lucid Technologies, Henrietta, N.Y., USA) using an objective lens with 30x magnification. The lateral resolution was 0.5~1.0 μm , and the axial resolution was 3~55 μm .

RCM images revealed that the skin lesions were thinner than the surrounding normal skin. The spinous layer showed slight oedema. Many dendritic cells, scattered hair follicular keratotic plugging and hair follicle dilatation were observed. There was no pigmentation in the epidermis and no melanophages in the dermis. The dilation and congestion of superficial dermis blood vessels, an increasing vascular density and accelerated blood flow, and a greater abundance of infiltrated inflammatory cells were also detected (Figure 2).

Since the patient refused skin biopsy, we did not perform this examination. According to previous studies, the histopathological findings of PD are mainly perifollicular lymphocytic and perivascular infiltration. In addition, epidermal oedema and keratosis, along with vascular dilatation, are seen in the dermis.^{2,4} The findings of RCM corresponded substantially with the histopathology.

Treatment included topical 0.03% tacrolimus cream and vitamin E cream and 0.1 g oral doxycycline twice a day. The erythema and papules mostly subsided after a month (Figure 3). RCM examination found no obvious oedema in the spinous layer, vascular dilation and congestion were improved, and no inflammatory cells were detected in the dermis (Figure 4).

Discussion

The clinical manifestations of PD are sometimes clinically similar to those of acne, SD, GR, LMDF and CGPD, and RCM can assist in diagnosis. Acne tends to occur in young patients, and under RCM, comedos (enlarged infundibula with a hyperkeratotic bright border), papules (massive inflammatory cell infiltration), and pustules (hyperreflecting inflammatory infiltration in the pustular cavity) can be found.⁶ SD usually occurs in the brow, scalp and nasolabial region where oil production is strong, and the main symptom is scaling. Features of SD that can be observed under RCM include spongiosis, dermal inflammation and the horizontal direction of dilating blood vessels.⁷ RCM can show the characteristic high density of demodex mites in the upper part of hair follicles of GR patients.⁸ Although demodex mites

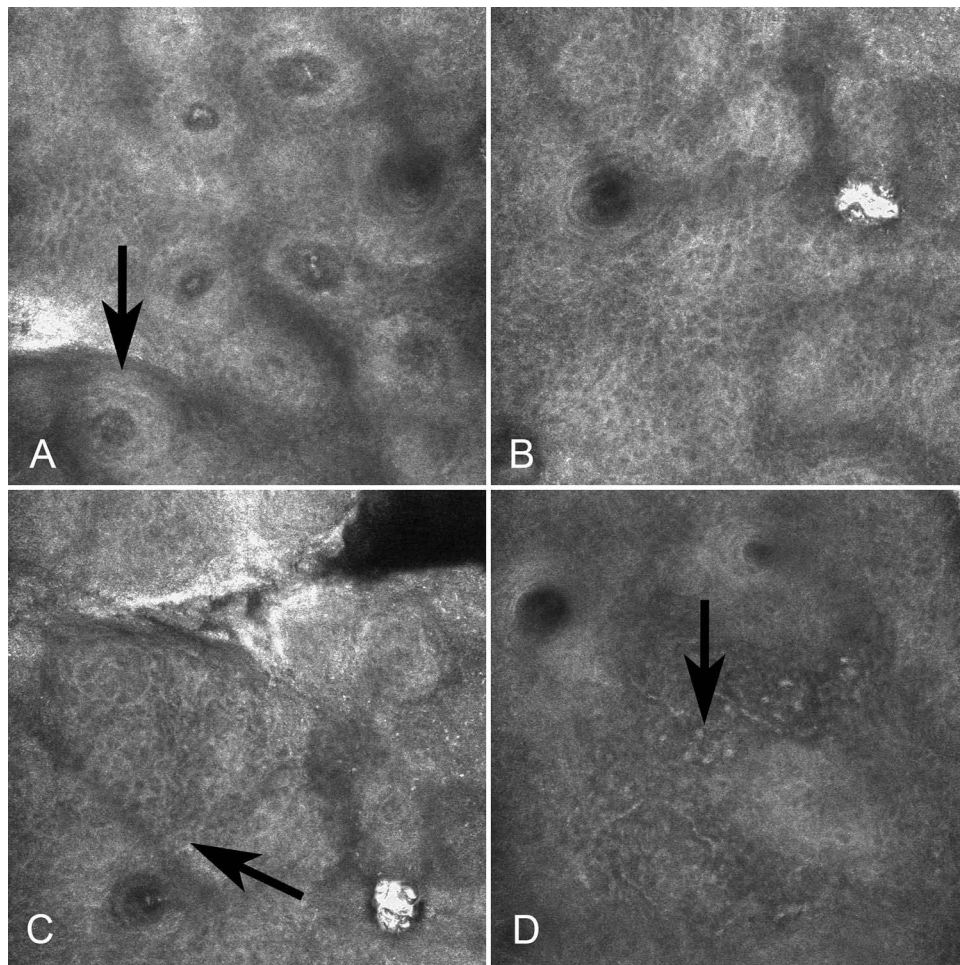


Figure 2 RCM features of PD patient (A) Dilated and congested vessels in the superficial dermis, with increased vascular density. (B) No pigmentation in the epidermis. (C) The spinous layer showed slight edema. (D) Dermis was infiltrated by inflammatory cell, without melanophages.

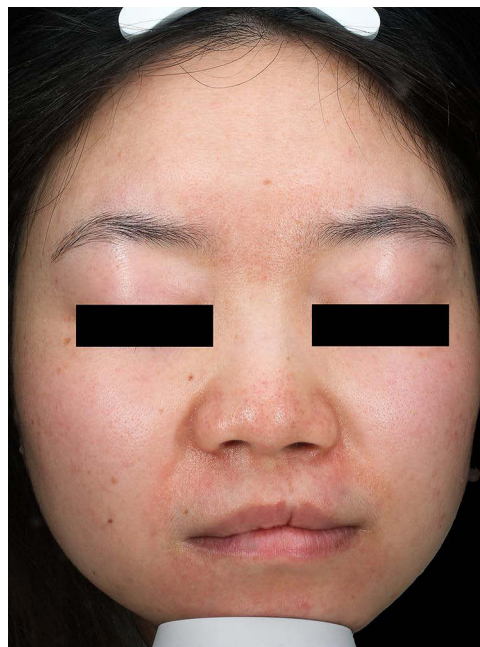

Figure 3 Facial image of the PD patient after treatment. The erythema and papules around the wing of nose and mouth were significantly improved.

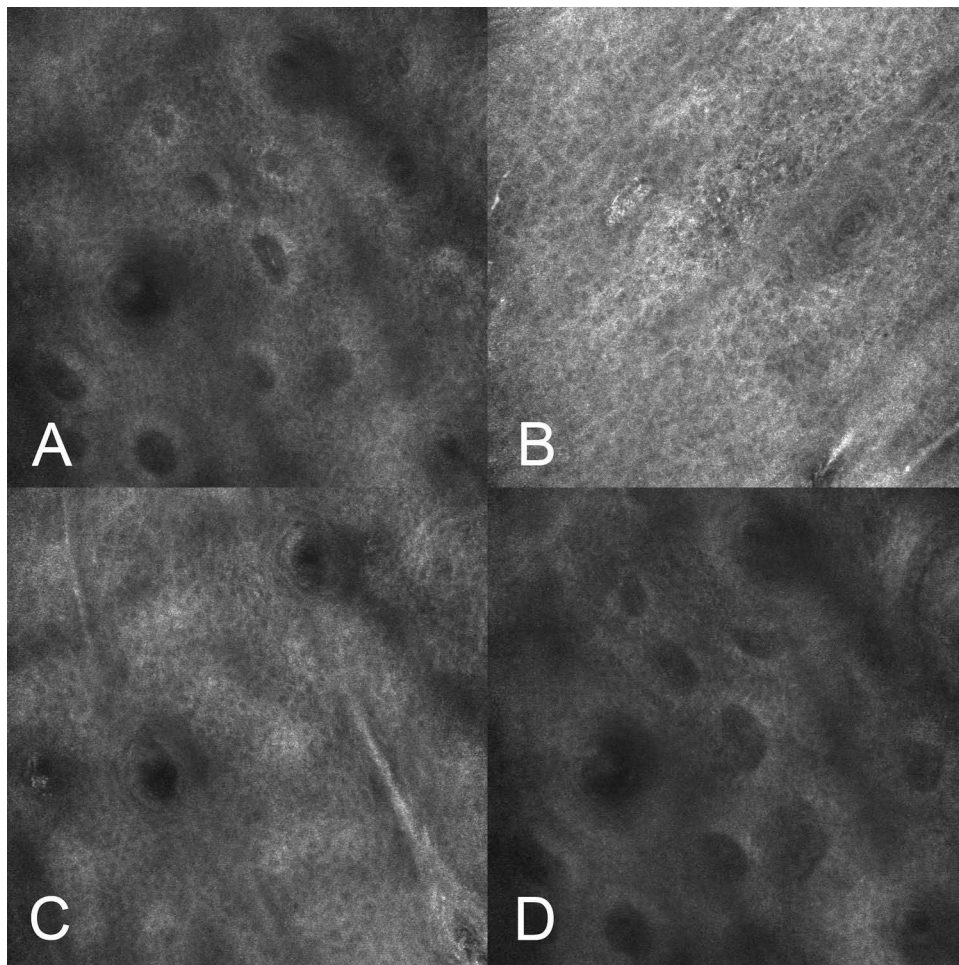


Figure 4 RCM features of PD patient after treatment (A) Vascular dilation and congestion were improved. (B) No pigmentation in the epidermis. (C) No obvious edema in the spinous layer. (D) No inflammatory cells were detected in the dermis.

can be seen in PD, they are rare. Moreover, the bright beaded-like structures observed on RCM, corresponding to reticulin fibres overlying granulomas, are effective for the diagnosis of sarcoidosis.⁹ In CGPD, dermal infiltration of epidermoid histiocytes can be observed under RCM, which, although not specific, is highly suggestive of granulomatous disease.¹⁰

Conclusion

In conclusion, we report RCM features of an adult patient with PD that, combined with clinical manifestations, can aid in differential diagnosis without the need for skin biopsy.

Consent

Written informed consent was obtained from the patient for the publication of this case report and any accompanying images. Institutional approval was not required for this case study.

Acknowledgments

We thank the patient for her permission to publish this information. This work was supported by the Hangzhou biomedical and health industry development support project (2021WJCY159), Hangzhou medical key discipline construction project (No [37]21-3) and Hangzhou health science and technology key project (No 20220054).

Disclosure

The authors report no conflicts of interest related to this work.

References

1. Nguyen V, Eichenfield LF. Periorificial dermatitis in children and adolescents. *J Am Acad Dermatol*. 2006;55(5):781–785. doi:10.1016/j.jaad.2006.05.031
2. Lipozencic J, Ljubojevic S. Perioral dermatitis. *Clin Dermatol*. 2011;29(2):157–161. doi:10.1016/j.clindermatol.2010.09.007
3. Charnowski S, Wollenberg A, Reinholz M. Perioral dermatitis successfully treated with topical ivermectin. *Ann Dermatol*. 2019;31(Suppl):S27–S28. doi:10.5021/ad.2019.31.S.S27
4. Lee GL, Zirwas MJ. Granulomatous rosacea and periorificial dermatitis: controversies and review of management and treatment. *Dermatol Clin*. 2015;33(3):447–455. doi:10.1016/j.det.2015.03.009
5. Xiang W, Xu A, Xu J, Bi Z, Shang Y, Ren Q. In vivo confocal laser scanning microscopy of hypopigmented macules: a preliminary comparison of confocal images in vitiligo, nevus depigmentosus and postinflammatory hypopigmentation. *Lasers Med Sci*. 2010;25(4):551–558. doi:10.1007/s10103-010-0764-2
6. Alma A, Sticchi A, Chello C, et al. Dermoscopy, reflectance confocal microscopy and optical coherence tomography features of acne: a systematic review. *J Clin Med*. 2022;11(7):1783. doi:10.3390/jcm11071783
7. Agozzino M, Berardesca E, Donadio C, et al. Reflectance confocal microscopy features of seborrheic dermatitis for plaque psoriasis differentiation. *Dermatology*. 2014;229(3):215–221. doi:10.1159/000363289
8. Sattler EC, Hoffmann VS, Ruzicka T, Braunmuhl TV, Berking C. Reflectance confocal microscopy for monitoring the density of Demodex mites in patients with rosacea before and after treatment. *Br J Dermatol*. 2015;173(1):69–75. doi:10.1111/bjd.13783
9. Pasquali P, Gonzalez S, Fortuno A, Freitas-Martinez A. In-vivo assessment of a case of cutaneous sarcoidosis using reflectance confocal microscopy. *An Bras Dermatol*. 2019;94(1):93–95. doi:10.1590/abd1806-4841.20197315
10. Lacarrubba F, Verzi AE, Caltabiano R, Puglisi DF, Micali G. Childhood granulomatous periorificial dermatitis: dermoscopy, reflectance confocal microscopy and histopathological correlations. *Australas J Dermatol*. 2020;61(4):e465–e467. doi:10.1111/ajd.13385

Clinical, Cosmetic and Investigational Dermatology

Dovepress

Publish your work in this journal

Clinical, Cosmetic and Investigational Dermatology is an international, peer-reviewed, open access, online journal that focuses on the latest clinical and experimental research in all aspects of skin disease and cosmetic interventions. This journal is indexed on CAS. The manuscript management system is completely online and includes a very quick and fair peer-review system, which is all easy to use. Visit <http://www.dovepress.com/testimonials.php> to read real quotes from published authors.

Submit your manuscript here: <https://www.dovepress.com/clinical-cosmetic-and-investigational-dermatology-journal>