

A Case of Secondary Syphilis with the Extragenital Chancre of the Lips and Tongue

Dan Li¹, Ming Zhang¹, Jilai Yin^{2,*}, Kai Chen^{1,*}

¹Department of Dermatology, The Fifth People's Hospital of Hainan Province, Haikou, Hainan Province, People's Republic of China; ²Department of Laboratory, The First Affiliated Hospital of Hainan Medical University, Haikou, Hainan Province, People's Republic of China

*These authors contributed equally to this work

Correspondence: Kai Chen, Department of Dermatology, The Fifth People's Hospital of Hainan Province, No. 8 Longhua Road, Longhua District, Haikou, Hainan Province, 570206, People's Republic of China, Email bladetruth@126.com; Jilai Yin, Department of Laboratory, the First Affiliated Hospital of Hainan Medical College, No. 31, Longhua Road, Haikou, Hainan Province, 570100, People's Republic of China, Email 187295067@qq.com

Abstract: A 18-year-old male presented with ulcers of lips and tongue and erythema of trunk of more than a month duration. Laboratory examinations for syphilis showed that TRUST (+) 1:32, TPPA (+), and HIV antibodies were negative. Combined with his case history and signs, he was diagnosed with secondary syphilis with chancre of lips and tongue and was cured by injecting benzathine penicillin 2.4 million U into gluteal muscles on both sides once a week for three times. After a month, the erythema and chancre disappeared. Three months later, the TRUST test was positive, the titer was 1:8, and the TPPA was positive.

Keywords: chancre, secondary syphilis

Introduction

Syphilis is a sexually transmitted disease caused by *Treponema pallidum* that affects different parts of the body. It can be divided into primary syphilis, secondary syphilis, tertiary syphilis, and neuro-syphilis. The diagnosis is based on clinical manifestations and serological methods. Bicillin L-A is the recommended treatment for syphilis.

Case Presentation

An 18-year-old male presented with four ulcers of lips and tongue, and erythema of trunk of more than a month duration. A month ago, two mung-bean sized ulcers without oozing appeared on the lower lip of the patient, and erythema appeared on the front and back of the trunk. There was no discomfort such as pain or itching in those lesions. After that, the ulcers gradually enlarged, and the patient often licked his lower lip with his tongue, and the erythema of his trunk did not fade. Three weeks ago, two new ulcers appeared on the tongue corresponding to the ulcers, with no discomfort such as pain or itching. Then, he began to go to the local hospital. After being diagnosed with cheilitis and receiving multiple treatments, the ulcers on his lip and tongue became superficial, but appeared again due to repeated scabbing and falling off. However, there was no improvement in the skin of the patient's trunk. The patient has no additional systemic sign. He denied any history of perioral herpes simplex or other diseases or any history of drug or food allergies. The patient had two unclean sexual contacts before 3 months and 2 weeks before the onset, denying any history of oral sex.

Physical Examination

The general condition was good, and the mandibular lymph nodes and inguinal lymph nodes were not touched. Specialist examination: There were two erosive surfaces in the lower lip, with central uplift distributed symmetrically left and right, same size, yellow-red oval shape, about 1 cm in diameter, no secretion on the surface, clear depression at the edge palpable hardness like cartilage (Figure 1a). Two ulcers of the same size could be seen in the anterior part of the tongue, corresponding to the lower lip, which were round with shallow funnellform, central depression, and clean surface

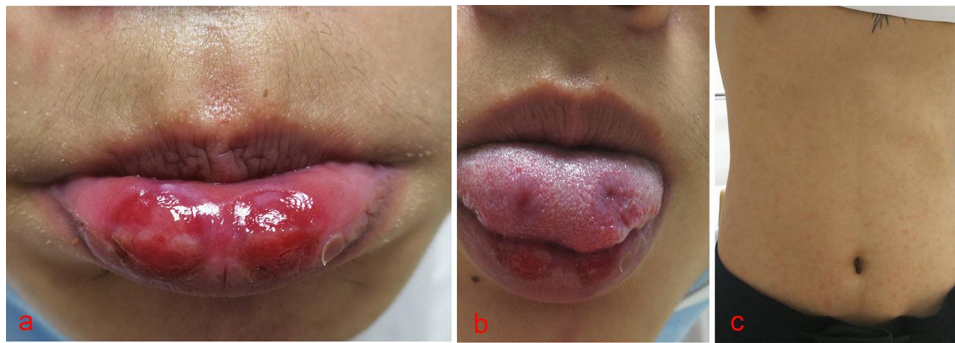


Figure 1 (a) Two erosive surfaces in the lower lip, with central uplift distributed symmetrically left and right. (b) Two ulcers of the same size could be seen at the corresponding part of the front part of the tongue. (c) Fuzzy infiltrating erythema in front and back of the trunk.

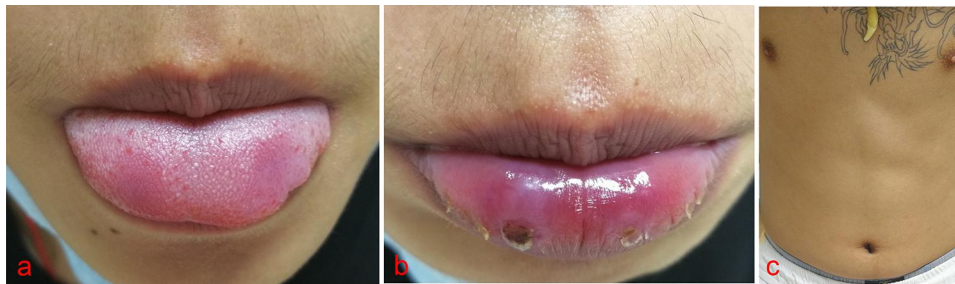

Figure 2 (a) The erosion surfaces of the patient's lips became softer, smaller and flatter obviously. (b) The erosion surfaces of the patient's tongue became softer, smaller and flatter obviously. (c) The erythema of the trunk completely subsided.

(Figure 1b). The patient had fuzzy infiltrating erythema in the front and back of the trunk, which was symmetrical distribution, about the size of soybeans (Figure 1c). A mung-bean sized erythema could be seen on the right side of the glans coronal sulcus, which was slightly hard to touch.

Ancillary Examination

Blood and urine routines were normal, TRUST test was positive, and the titer was 1:32, Treponema pallidum particle agglutination test (TPPA) was positive, anti-HIV antibody was negative, dark-field microscopy of Treponema pallidum at lips was negative, DNA of herpes simplex virus type I and type II were negative. Diagnosis: 1. Chancre 2. Secondary syphilis.

Treatment and Prognosis

Benzathine penicillin 2.4 million U was given intramuscular injection on both sides of gluteal muscles once a week for 3 times in total. On the night of the first injection, the patient developed Jarisch–Herxheimer reaction and fever. After his body temperature rose to 38°C, pruritus appeared on skin lesions on the front and back of his torso, and then the body temperature dropped to normal after a few hours. Seven days later, when the patient received the second benzathine penicillin treatment, the erosion surfaces of the patient's lips and tongue became softer, smaller and flatter obviously (Figure 2a and b), and the erythema of the trunk completely subsided (Figure 2c). After a month, the skin lesions completely subsided, and the erosion surfaces of lips and tongue completely healed.

Discussion

Syphilis is a sexually transmitted disease caused by *T. pallidum*. In the course of disease, early syphilis within 2 years can be divided into primary, secondary, and early latent syphilis. The incidence rate of syphilis is increasing worldwide, the threat to human health is also increasing.^{1,2}

Syphilis has two periods, the primary one is manifested with the chancre and its satellite adenomegaly, and the second with the systemic manifestations of the infection. There is usually a latency period with no symptoms between them, although in about 15% of the cases show the coexistence of the two periods.³ In most cases, chancre is the site of inoculation for *Treponema pallidum*. Some authors, especially the oldest, call it inoculation chancre. Relapsing secondary syphilis could be accompanied by chancre. Sometimes oral lesions of secondary syphilis manifested as chancre-ulcer lesion.⁴ Therefore, the 18-year-old male probably concealed the history of oral sex and thus developed a new syphilis infection. There is another possibility that he was only infected with syphilis once, and all the lesions were secondary syphilis recurrence.⁵ Since we did not perform a biopsy, and there was no classic or specific adenopathy at this stage of the disease, only secondary syphilis was diagnosed. Similar reports are common at home and abroad.⁶ Based on the history and signs, his tongue lesions could be defined as kissing chancre, it may also be related to self-inoculation.⁷

According to the Guideline for the diagnosis and treatment of syphilis, gonorrhea and genital chlamydia trachomatis infection (2020) issued by Chinese Center for Disease Control and Prevention (Chinese CDC). Moreover, it clinically is difficult to distinguish, whether it is early syphilis or late syphilis, Benzacilin penicillin 2.4 million U was given intramuscular injection on both sides of gluteal muscles of the patient once a week for 3 times in total.⁸

Conclusion

This is the first reported case of secondary syphilis associated with kissing chancre in Chinese and English literature on the Internet. The patient's chancre of tongue and lower lip caused by licking is kissing chancre. Considering that the patient had unclean intercourse and was mis-diagnosed by several institutions after the onset of the disease, the secondary syphilis with the extragenital chancre may be related to reinfection or therapeutic error.

Ethics Statement

The publications of images were included in the patient's consent for publication of the case. The Hospital Ethics Committees of the Fifth People's Hospital of Hainan Province approved the publication of the case details. The Hospital Ethics Committees of the First Affiliated Hospital of Hainan Medical University approved the publication of the case details.

Consent Statement

Informed consent was provided by the patient for publication of the case.

Funding

This project is supported by Hainan Province Clinical Medical Center.

Disclosure

The authors report no conflicts of interest in this work.

References

1. Bach S, Heavey E. Resurgence of syphilis in the US. *Nurse Pract.* 2021;46(10):28–35. doi:10.1097/01.NPR.0000790496.90015.74
2. Mingyan H, Qing Z, Qianqiang W. Spatial-temporal differentiation of gonorrhea and syphilis in the mainland of China from 2005 to 2020. *Chin J AIDS STD.* 2023;29(03):319–323.
3. Bian Z. *Chinese Clinical Dermatology*. Nanjing: Jiangsu Science and Technology Press; 2009:1786–1788.
4. Khan M, Sharma A, Hathorn T. et al. The mucosal manifestations of syphilis in the head and neck. *Ear Nose Throat J*;2023. 1455613231165159. doi:10.1177/01455613231165159
5. Myint M, Bashiri H, Harrington RD, et al. Relapse of secondary syphilis after benzathine penicillin G: molecular analysis. *Sex Transm Dis.* 2004;31(3):196–199. doi:10.1097/01.OLQ.0000114941.37942.4C
6. Mitra D, Singh GK, Mitra B, et al. A case of primary and secondary syphilis presenting together as immune reconstruction influenza syndrome. *Indian J Sex Transm Dis AIDS.* 2021;42(2):156–158. doi:10.4103/ijstd.IJSTD_58_20
7. Arunprasath P, Krishnaswamy M, Rai R. Synchronous primary and secondary syphilis - An uncommon presentation. *Indian J Sex Transm Dis AIDS.* 2021;42(1):85–87. doi:10.4103/ijstd.IJSTD_13_20
8. National Center for STD Control of Chinese CDC, Chinese Society of Dermatology of Chinese Medical Association, STD subspecialty Committee of Chinese Dermatologist Association. Guidelines for diagnosis and treatment of syphilis, gonorrhea and genital Chlamydia trachomatis infection (2020). *Chin J Dermatol.* 2020;53(3):168–179.

Clinical, Cosmetic and Investigational Dermatology

Dovepress

Publish your work in this journal

Clinical, Cosmetic and Investigational Dermatology is an international, peer-reviewed, open access, online journal that focuses on the latest clinical and experimental research in all aspects of skin disease and cosmetic interventions. This journal is indexed on CAS. The manuscript management system is completely online and includes a very quick and fair peer-review system, which is all easy to use. Visit <http://www.dovepress.com/testimonials.php> to read real quotes from published authors.

Submit your manuscript here: <https://www.dovepress.com/clinical-cosmetic-and-investigational-dermatology-journal>