

Management and Characteristics of Embolism and Thrombosis After COVID-19 Vaccination: Scoping Review

Lalipat Phianhasin^{1,*}, Suebsarn Ruksakulpiwat¹, Suratsawadee Kruahong¹, Premgamon Kuntajak¹, Glenda B Kelman², Chitchanok Benjasirisan^{1,*}

¹Faculty of Nursing, Mahidol University, Bangkok, Thailand; ²Department of Nursing, Russell Sage College, Troy, NY, USA

*These authors contributed equally to this work

Correspondence: Chitchanok Benjasirisan, Department of Medical Nursing, Faculty of Nursing, Mahidol University, 2 Prannok Road, Siriraj, Wanglang, Bangkoknoi, Bangkok, 10700, Thailand, Tel +66 98-272-4330, Email Chitchanok.ben@gmail.com

Abstract: This scoping review aims to 1) identify characteristics of participants who developed embolism and/or thrombotic event(s) after COVID-19 vaccination and 2) review the management during the new vaccine development of the unexpected event(s). This review was conducted following PRISMA for scoping review guidelines. Peer-reviewed articles were searched for studies involving participants with embolism and/or thrombotic event(s) after COVID-19 vaccination with the management described during the early phase after the approval of vaccines. The 12 studies involving 63 participants were included in this review. The majority of participants' ages ranged from 22 to 49 years. The embolism and/or thrombotic event(s) often occur within 30 days post-vaccination. Five of the included studies reported the event after receiving viral vector vaccines and suggested a vaccine-induced immune thrombotic thrombocytopenia as a plausible mechanism. Cerebral venous sinus thrombosis was the most frequently reported post-vaccination thrombosis complication. In summary, the most frequently reported characteristics and management from this review were consistent with international guidelines. Future studies are recommended to further investigate the incidence and additional potential complications to warrant the benefit and safety after receiving COVID-19 vaccine and other newly developed vaccines.

Keywords: COVID-19 vaccine, thromboembolism, cerebral venous sinus thrombosis, vaccine-induced immune thrombotic thrombocytopenia

Introduction

COVID-19 is an infectious disease caused by a newly discovered coronavirus, severe acute respiratory syndrome coronavirus 2 (SARS-CoV-2).¹ The vaccine breakthrough has influenced controlling the pandemic by decreasing the rate of new infections among individuals who have been vaccinated.² Generally, the development of a safe vaccine takes years of research prior to products used in clinical trials.³ For the COVID-19 vaccine. Several different types of COVID-19 vaccines have been developed with unprecedented speed and with the use of diverse technologies, including inactivated, protein-based, viral vector, and RNA and DNA vaccines.⁴

Minor side effects, like fever, fatigue, headache, and muscle pain, are normal body responses after COVID-19 vaccination, yet some side effects can cause adverse outcomes.⁵ Embolism and/or thrombotic event(s) have been reported as possible adverse events associated with some type of COVID-19 vaccination.⁵ Although the incidence is rare, it can result in life-threatening complications. Correspondingly, because several other vaccines have also reported thrombocytopenia incidents, such as active diphtheria, measles–mumps–rubella, and influenza vaccination, embolism and/or thrombotic event(s) are likely to be adverse effects of future vaccines.⁶ Consequently, this scoping review aims to identify characteristics of participants who developed embolism and/or thrombotic event(s) after COVID-19 vaccination



and review the management of unexpected event(s) during the new vaccine development in order to guide future management and prevent from life-threatening complications.

Methods

The PRISMA for scoping reviews was utilized as a review protocol to guide the review.⁷ Four electronic databases, including PubMed, MEDLINE, Web of Science, and CINAHL Plus Full-Text databases, were systematically searched from June to July 2021, representing the time of the extensive utilization of COVID-19 vaccines and right before the European Medicines Agency (EMA) announced a possible link to embolism and/or thrombotic event(s).⁸ Reference lists of the included studies were manually searched to obtain relevant studies. All references identified were stored in EndNote. The detailed search strategies are available in [Supplementary Data 1](#).

Inclusion/Exclusion Criteria

Peer-reviewed articles were included on the incident of embolism and thrombosis after COVID-19 vaccination and its management. In this scoping review, embolism and thrombosis are defined as

A collective term for pathological conditions which are caused by the formation of a blood clot (thrombus) in a blood vessel, or by blocking of a blood vessel with an embolus, undissolved materials in the bloodstream.⁹

The terms embolism and thrombosis also include thromboembolism, which is an obstruction of a blood vessel by thrombus in the bloodstream. The details of the inclusion and exclusion criteria of the review are provided in [Table 1](#).

First, titles and abstracts were screened independently by the first two authors. Then, the two authors assessed the full text to consider the relevance of the study following the inclusion and exclusion criteria. Finally, any disagreements were resolved using a third author or consensus among the authors.

Assessment of Methodological Quality

The Joanna Briggs Institute (JBI) critical appraisal tools were used as the assessment tools. The tools can assess various types of studies.^{10,11} Two independent authors performed quality control for the eligible studies. After the eligible studies were finalized, two authors evaluated the methodological quality of each eligible study independently. Any disagreements were solved by consensus or by the decision of a third author.

Table 1 Study Inclusion and Exclusion Criteria

Inclusion Criteria
<ul style="list-style-type: none"> • Human participants who are equal to or older than 12 years, which is the minimum age to be authorized for COVID-19 vaccines at the time of included studies. • Original quantitative, qualitative, mixed-methods studies, case series, or case report. • Reported the management and adverse reaction of the COVID-19 vaccine, specifically in embolism and/or thrombotic events. • This review aimed to study the characteristics and management of the embolism and/or thrombotic event(s), a collective term for pathological conditions caused by the formation of a blood clot (THROMBUS) in a blood vessel or by blocking a blood vessel with an EMBOLUS, undissolved materials in the bloodstream, after COVID-19 vaccination. • The study described the characteristics of participants, incidence, possible etiology, diagnosis, and management. • All settings are acceptable, including inpatient, outpatient, or home. • Studies published between April–July 2021. • Studies described in the English language.
Exclusion Criteria
<ul style="list-style-type: none"> • The review did not include the population of interest or concerns animal subjects. • Conference proceedings, abstracts, review articles, theoretical papers, pilot studies, dissertations, letters to the editor, opinion (viewpoint), statement papers, correspondence, perspective, government documents, news, protocol, or working papers.

Data Charting

The summary data (see Table 2) developed for the review included the following data: references, country, study type, COVID-19 vaccine information, sample size, characteristics of the patients, medical history, prescription medication, clinical presentation, embolism and/or thrombotic event(s), coexisting conditions, the potential mechanism of the incidents, and clinical management. The first two authors completed data extraction, and the data was verified by the other authors.

Data Synthesis

After the eligible studies were assessed by the JBI critical appraisal tools, the data was analyzed using a narrative approach, specifically thematic synthesis. The analysis revealed six themes; 1) Characteristics of participants; 2) Vaccine information; 3) Potential mechanism; 4) Clinical presentation, embolism and/or thrombotic event(s), and coexisting conditions and; 5) Clinical management.

The first theme includes a synthesis of gender, age, medical history, and prescription medication. Since there is no validated or standardized measure for the age range that is suitable to classify the population of COVID-19 vaccine administration's age, the preferred age range was used. In addition, the ICD10 version 2016 was utilized to describe the diagnosis, signs, and symptoms in the clinical presentation, embolism and/or thrombotic event(s), and coexisting conditions.²⁴

Results

Search Results

Among 191 initially identified articles, 12 studies fulfilled the inclusion criteria and were included in the scoping review (see Figure 1). The description of the included studies is summarized in Table 2.

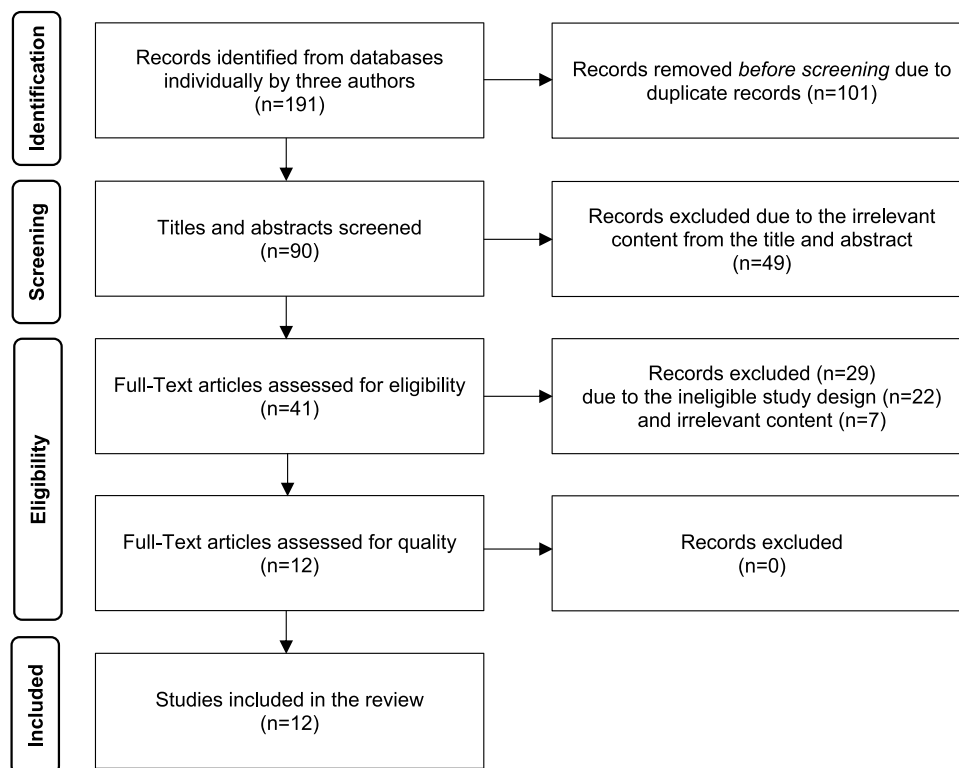


Figure 1 The figure was adapted from Moher D, Liberati A, Tetzlaff J, Altman DG, Prisma Group. Reprint—Preferred reporting items for systematic reviews and meta-analyses: the PRISMA statement. *Annals of internal medicine*. 2009;151(4):264–269.²⁵ The figure displays the selection method of qualified studies and shows the four phases of conducting a scoping review: identification, screening, eligibility, and inclusion. In each phase, the number of records or articles is reported along with the reasons for exclusion. The final phase results in a set of included studies were 12 studies that are relevant to the research question and scope of the review.

Table 2 Summary Table of Embolism and/or Thrombotic Event(s) After the COVID-19 Vaccination and Its Management

- Reference - Country - Study Design	- Brand and Type of COVID Vaccine - Dosage - Time Duration from Vaccination to the Admission of the Event	- Sample Size - Characteristics	- Medical History- Prescription Medication	- Clinical Presentation	- Embolism and/or Thrombotic Event(s) - Coexisting Condition(s)	- Potential Mechanism	Clinical Management - Laboratory and Imaging Findings - Medical Treatment - Researcher's Recommendation (If Available)
[12] - Oman - Case report	- Pfizer (mRNA) - 1st dose - 7 days	n =1 Age: 59 Gender: Female	Medical History - DM type 2 - Osteoarthritis - COVID-19 with no residual complications, 7 months before the vaccination Regular Medication - Metformin - Oral contraceptive pill	- Sudden-onset left leg pain. - The left leg was swollen and warm with calf tenderness.	Embolism and/or Thrombotic event(s) - DVT - PE	VITT	Laboratory and imaging findings - Normal Platelet - ↑D-dimer - Normal INR - Normal aPPT - Duplex ultrasonography of the lower limbs: acute DVT - CTPA: saddle thrombus in the pulmonary trunk - HIT ELISA: positive on 4 th day Medical treatment Anticoagulation treatment - Enoxaparin→rivaroxaban
[13] - Germany - Case report	- AstraZeneca (Viral vector) - 1st dose - 10 days	n=1 Age: 55 Gender: Female	Medical History - No medical history of visual problems, autoimmune disorders, stroke, thrombosis, thrombocytopenia, neurological disorders, or arterial disease risk factors	- Conjunctival congestion - Retro-orbital pain - Diplopia	Embolism and/or Thrombotic event(s) - Bilateral superior ophthalmic vein thrombosis - Ischemic stroke	ITP	Laboratory and imaging findings - (+)ve IgG antiplatelet antibodies - (+)ve platelet suspension immunofluorescence test - (+)ve monoclonal antibody-specific immobilization of platelet antigens assay - MRI: superior ophthalmic vein thrombosis - MRI: ischemic stroke after developing stroke symptoms Medical treatment Anticoagulation treatment - Heparin→phenprocoumon Other management - Intravenous dexamethasone; suspected ITP - Initial levetiracetam and lacosamide; seizures

<p>[14] - Italy - Case report</p>	<p>- AstraZeneca (Viral vector) - 12 days</p>	<p>n=1 Age: 54 Gender: Female</p>	<p>Medical History - Meniere's disease</p>	<p>- Acute CVA of the left side - The lower limbs were normothermic and normoconformed</p>	<p>Embolism and/or Thrombotic event(s) - CVST - PE - AMI - Hepatic vein thrombosis - Portal vein thrombosis Coexisting condition(s) - ICH - Adrenal hemorrhage</p>	<p>DIC</p>	<p>Laboratory and imaging findings - ↑D-dimer - Normal fibrinogen level - ECG: MI - CT scan: multiple subacute intra-axial hemorrhages - CTA: partial thrombosis of the vein of Galen, and a floating thrombus within the aortic arch - Thorax angio-CT: multiple contrasts filling defects - Brain MRI: acute basilar thrombosis. - Abdomen angio-CT: filling defects at the portal branch and the suprahepatic vein. Adrenal hemorrhage and blood in the pelvis - A brain CT performed one day later showed a diffuse ischemic hypodensity Medical treatment Other management - POBA at the right coronary artery</p>
<p>[15] - Germany and Austria - Case series</p>	<p>- AstraZeneca (Viral vector) - 5–16 days</p>	<p>n=11 Gender: 9 Females 2 Males Age: 22–49</p>	<p>Medical History - von Willebrand disease, anticardiolipin antibodies, and factor V Leiden (1/11) - None of the patients had received heparin before the onset of symptoms or the diagnosis of thrombosis (11/11)</p>	<p>- Chills, fever, nausea, and epigastric discomfort (1/11) (Index case)</p>	<p>Embolism and/or Thrombotic event(s) - CVST (9/10) - Splanchnic vein thrombosis (3/11) - PE (3/11) - Aortoiliac thrombosis (1/11) - Right intraventricular thrombosis (1/11) - Iliofemoral vein (1/11) - IVC thrombosis (1/11) - Widespread microvascular (brain, lungs, kidneys) (1/11) - Multiple organ thrombi (1/11) Coexisting condition(s) - Cerebral hemorrhage (1/11)</p>	<p>VITT due to 2 possible mechanisms 1. Adenovirus binds to platelets and causes platelet activation. 2. Free DNA in the Vaccine could be a possible trigger of these PF4-reactive antibodies.</p>	<p>Laboratory and imaging findings - ↓Platelet count (10/10) - ↑D-dimer (7/7) - Hypofibrinogenemia (4/6) - Evidence of DIC (5/11) - (+)ve reactivity on PF4–heparin ELISA (9/9) Medical treatment Anticoagulation treatment - LMWH→apixaban (Index case) - Heparin (4/8)</p>

(Continued)

Table 2 (Continued).

- Reference - Country - Study Design	- Brand and Type of COVID Vaccine - Dosage - Time Duration from Vaccination to the Admission of the Event	- Sample Size - Characteristics	- Medical History- Prescription Medication	- Clinical Presentation	- Embolism and/or Thrombotic Event(s) - Coexisting Condition(s)	- Potential Mechanism	Clinical Management - Laboratory and Imaging Findings - Medical Treatment - Researcher's Recommendation (If Available)
[16] - Norway - Case report	- AstraZeneca (Viral vector) - Sequence of dose: N/A - 27 days (1/2) - 29 days (1/2)	n=2 Gender: 1 Female, 1 Male Age: 30 (1/2) 40 (1/2)	Medical History - Hypothyreosis (1/2) - Lumbago issues (1/2) - Healthy (2/2) - No history of blood clots (1/2) Regular Medication - Levothyroxine (1/2)	- Petechiae in two fingers (1/2) - Three of the toenails turned blue and bruises (1/2) - Pain in the right popliteal fossa (1/2) - Pain in the upper leg without prior trauma. (1/2) - Slight proximal discomfort (1/2) - Slight swelling in the left lower leg (1/2)	Embolism and/or Thrombotic event(s) - DVT (2/2)	The mechanism is unclear.	Laboratory and imaging findings - Normal Platelets (2/2) - Normal D-dimer (2/2) - Wells score = 0 (2/2) - Ultrasound: right lower extremity, distal popliteal vein compression, and a sickle-shaped shadow (1/2) - MRI and platelet antibodies: no pathological findings (1/2) - Ultrasound: DVT (1/2) Medical treatment Anticoagulation treatment - Rivaroxaban (1/2) - Apixaban (1/2)
[17] - United Kingdom - Case report	- AstraZeneca (Viral vector) - 1st dose - 9 days (1/2) - 6 days (1/2)	n= 2 Gender: 2 Males Age: 32 (1/2) 25 (1/2)	Medical History - No known medical history (1/2) - Primary sclerosing cholangitis, Migraines (1/2) - No family history of autoimmune or clotting disorder (2/2) - Ex-smoker (1/2) - Smoker (1/2) Regular Medication - Ursodeoxycholic acid - Budesonide - Sumatriptan - Amitriptyline	- Thunderclap headache (1/2) - Left-sided Incoordination (1/2) - Hemiparesis (1/2) - Worsening headache (1/2) - Photophobia (1/2) - Neck stiffness (1/2) - Visual disturbances (1/2) - Non-blanching petechial rash over lower limbs (1/2) - Bleeding of the gums (1/2)	Embolism and/or Thrombotic event(s) - CVST (2/2) Coexisting condition(s) - SAH (2/2) - IPH (2/2)	- An underlying immunological mechanism similar to that of spontaneous HIT is suspected, with the identification of antibodies to platelet factor-4, but without previous heparin exposure.	Laboratory and imaging findings - ↓Platelet count (2/2) - ↓Fibrinogen level (2/2) - (-)ve SARS-CoV2 PCR (2/2) - (+)ve PF4 antibodies (1/1) - Neuroimaging: superior sagittal sinus and cortical vein thrombosis and cortical edema with parenchymal and SAH. (1/2) - Neuroimaging: superior sagittal sinus thrombosis with extension into the cortical veins, and hemorrhage in lobar and subarachnoid (1/2) Medical treatment Anticoagulation treatment - Heparin (1/2) Other management - Platelet transfusions; brain hemorrhage and thrombocytopenia (1/2) - Dexamethasone (1/2) - IVIG (1/2) - Levetiracetam; seizure (1/2)

<p>[18] - Norway - Case Report</p>	<p>- AstraZeneca (Viral vector) - 1st dose - 7–10 days</p>	<p>n=5 Gender: 4 females, 1 male Age: 32–54</p>	<p>Medical History - Pollen allergy (2/5) - Hypertension - Asthma with no preexisting conditions apart from asthma (1/5) - No underlying disease (1/5) Regular Medication - Contraceptive pill (1/5) - Contraceptive vaginal ring (1/5) - Hormone-replacement therapy (1/5) - Antihypertensive agents (1/5) - No medication (2/5)</p>	<p>- Headaches (3/5) - Fever (1/5) - Visual disturbances (1/5) - Abdominal pain (1/5) - Reduced consciousness (1/5) - Hemiparesis (1/5) - Back pain (1/5)</p>	<p>Embolism and/or Thrombotic event(s) - CVST (4/5) - Portal vein, left hepatic vein, splenic vein, azygos vein, hemiazygos vein, and several basivertebral veins thrombosis (1/5) Coexisting condition(s) - Cerebellar hemorrhage (1/5) - Cerebellar edema (1/5) - Hemorrhagic infarction (2/5) - Frontal hemorrhage (1/5)</p>	<p>VITT</p>	<p>Laboratory and imaging findings - ↓Platelet count (5/5) - ↑D-dimer (5/5) - ↓Fibrinogen level (3/5) - ↑IgG antibodies to PF4 levels (5/5) - Normal INR (5/5) - Normal aPPT (5/5) - SARS-CoV-2 antibody test (-)ve Nucleocapsid protein (5/5) (+)ve Spike protein (5/5) - CT brain: thrombosis (1/5) - CT venography: venous thrombosis (3/5) - CT venography: hemorrhagic infarction (2/5) - Thoracoabdominal CT scan: thrombosis (1/5) - MRI spine with contrast: hypointensity in thoracic vertebrae and basivertebral veins (1/5) - CT head: right frontal hemorrhage (1/5) - CT: massive cerebellar hemorrhage and edema (1/5) Medical treatment Anticoagulation treatment - Dalteparin (4/5) - Heparin (1/5) Other management - Platelet transfusions (4/5) - Methylprednisolone (2/5) - Prednisolone (2/5) - IVIG (4/5) - Venous recanalization (1/5) - Decompressive craniectomy (1/5) - Hemisectomy (2/5)</p>
--------------------------------------------	--------------------------------------------------------------------	---------------------------------------------------------	---------------------------------------------------------------------------------------------------------------------------------------------------------------------------------------------------------------------------------------------------------------------------------------------------------------------------------------------------------------------------------------------	---------------------------------------------------------------------------------------------------------------------------------------------------------------------------------------	---------------------------------------------------------------------------------------------------------------------------------------------------------------------------------------------------------------------------------------------------------------------------------------------------------------------------------------------------------------------------	-------------	-------------------------------------------------------------------------------------------------------------------------------------------------------------------------------------------------------------------------------------------------------------------------------------------------------------------------------------------------------------------------------------------------------------------------------------------------------------------------------------------------------------------------------------------------------------------------------------------------------------------------------------------------------------------------------------------------------------------------------------------------------------------------------------------------------------------------------------------------------------------------------------------------------------------------------------------------------------------------------------------------------------------------------------------------------------

(Continued)

Table 2 (Continued).

- Reference - Country - Study Design	- Brand and Type of COVID Vaccine - Dosage - Time Duration from Vaccination to the Admission of the Event	- Sample Size - Characteristics	- Medical History- Prescription Medication	- Clinical Presentation	- Embolism and/or Thrombotic Event(s) - Coexisting Condition(s)	- Potential Mechanism	Clinical Management - Laboratory and Imaging Findings - Medical Treatment - Researcher's Recommendation (If Available)
<p>[19] - United Kingdom - Case series</p>	<p>- AstraZeneca (Viral vector) - 1st dose - 6–24 days</p>	<p>n = 23 Gender: 14 Females, 9 Males Age: the median age of years (range 21–77)</p>	<p>Medical History - A history of deep venous thrombosis (1/23) Regular Medication - Combined oral contraceptive pill (1/23) - No history of a medical condition or use of medication likely to precipitate thrombosis (21/23)</p>	<p>- Mild bruising and petechiae - Secondary cerebral hemorrhage</p>	<p>Embolism and/or Thrombotic event(s) - CVST (13/23) - PE (5/23) - PVT (3/23) - MCA infarct (2/23) - Ischemic bowel with infraction (1/23) - AAT (1/23) Co-existing condition(s) - Adrenal hemorrhage (1/23) - ICH (3/23) - SAH (1/23) - Hemorrhagic symptoms only</p>	<p>VITT and thrombocytopenia</p>	<p>Laboratory and imaging findings - ↓ Platelet count (22/22) - ↑ D-dimer (21/21) - Fibrinogen level: ↓ (13/23), Normal (8/23), ↑ (2/23) - aPTT: ↓ (3/23), Normal (15/23), ↑ (5/23) - (+)ve ELISA for anti-PF4 antibodies (21/23) - (+)ve Functional HIT Assay (5/8) Researcher's Recommendation If patients present: - D-dimer level > 4000 FEU - Low or normal fibrinogen level - No evidence of an alternative diagnosis - VITT is suspected Medical treatment - Avoid platelet transfusion - Administer IVIG - Consider the use of glucocorticoids - Administer non-heparin anticoagulant - Consider treatment to increase fibrinogen level to >1.0 g/liter - Perform HIT ELISA. If positive, consider continuing treatment. If negative, review diagnosis and treatment and consider alternative or functional HIT assay If patients present: - D-dimer level < 2000 FEU - Normal results of coagulation tests and fibrinogen level - VITT is unlikely</p>

<p>[20] - The United States - Case series</p>	<p>- Janssen/Johnson & Johnson (Viral vector) - 11–25 days</p>	<p>n=12 Gender: 12 Females Age: 18–59</p>	<p>Medical History - Obesity (6/12) - Hypothyroidism (1/12) - SARS-CoV-2 infection approximately 4 months prior to vaccination (1/12) Regular medication - Oral contraceptive use (1/12) - Prior heparin exposure (0/12)</p>	<p>- Severe headache (2/12) - Headache (2/12) - Weakness (2/12) - Dry heaving (1/12) - Aphasia (2/12) - Gaze deviation (1/12) - Seizure (3/12) - Severe abdominal pain (1/12) - Loss of consciousness (2/12) - Lower extremities swelling (2/12) - Leg pain (1/12) - Neck stiffness (1/12) - Change in speech (1/12) - Fever (1/12) - Nausea (1/12) - Vomiting (2/12) - Dizziness (1/12) - Photophobia (1/12) - Neck pain (1/12)</p>	<p>Embolism and/or Thrombotic event(s) - CVST (12/12) - IJVT (6/12) - PVT (2/12) - PE (3/12) - DVT (3/12) - Splenic vein thrombosis (1/12) - Hepatic vein thrombosis (1/12) - Superior mesenteric vein thrombosis (1/12) Co-existing condition(s) - ICH (7/12)</p>	<p>Thrombosis with thrombocytopenia syndrome, an autoimmune HIT-like mechanism in which platelet-activating antibodies develop in the absence of heparin exposure</p>	<p>Laboratory and imaging findings - ↓ Platelets count (12/12) - ↑ D-dimer (12/12) - ↓ Fibrinogen level (8/12) - (+)ve PF4 HIT antibody ELISA (11/11) - (+)ve functional platelet HIT antibody (1/9) - (-)ve thrombophilia testing (11/11) - SARS-CoV-2 antibody test results (+)ve Nucleocapsid Antibody (2/4) (+)ve Spike antibody (1/4) (-)ve Antibody (unspecified either nucleocapsid or spike) (1/4) (-)ve PCR (10/11) (-)ve Antigen (1/11) - Radiographic evidence of CVST (12/12) Medical treatment Anticoagulation treatment - Heparin (6/12)→non-heparin (6/6) - Non-heparin anticoagulation (4/12) Other management - IVIG (7/12) - Systemic corticosteroids (3/7) - Platelet transfusions (4/7)</p>
<p>[21] - The United Kingdom - Case report</p>	<p>- AstraZeneca (Viral vector) - 1st dose - 48 hours</p>	<p>n=1 Gender: Male Age: 27</p>	<p>Medical History - Fit and well - No personal or family history of thromboembolic events.</p>	<p>- Intermittent headaches - Eye floaters - Vomiting</p>	<p>Embolism and/or Thrombotic event(s) - CVST Co-existing condition(s) - Parenchymal hemorrhage in the right parietal lobe</p>	<p>VITT</p>	<p>Laboratory and imaging findings - ↓ Platelets count - ↑ D-dimer - ↓ Fibrinogen level - (+)ve platelets factor 4 antibodies - CT venogram: CVST - CT head: acute parenchymal hemorrhage Medical treatment Anticoagulation treatment - Dabigatran Other management - IVIG - Idarucizumab; reverse dabigatran - Prednisolone with proton pump inhibitors. - Decompressive craniotomy with an external ventricular drain</p>

(Continued)

Table 2 (Continued).

- Reference - Country - Study Design	- Brand and Type of COVID Vaccine - Dosage - Time Duration from Vaccination to the Admission of the Event	- Sample Size - Characteristics	- Medical History- Prescription Medication	- Clinical Presentation	- Embolism and/or Thrombotic Event(s) - Coexisting Condition(s)	- Potential Mechanism	Clinical Management - Laboratory and Imaging Findings - Medical Treatment - Researcher's Recommendation (If Available)
[22] - Germany - Case reports	- AstraZeneca (Viral vector) - 1st dose - 7–17 days	n =3 Gender: 3 Females Age: 22 (1/3) 36 (1/3) 46 (1/3)	Medical history - No significant medical history (3/3) - Denies smoking (3/3) - BMI Overweight (1/3) Lean (1/3) N/A (1/3) Regular medication - Denies oral contraception (3/3)	- New frontally accentuated headaches (1/3) - A self-limited generalized epileptic seizure (1/3) - Severe headaches (2/3) - Mild aphasia (1/3) - Hemianopia to the right (1/3) - Acute somnolence (1/3) - A right-hand hemiparesis (1/3)	Embolism and/or Thrombotic event(s) - CVST (3/3)	Exposure to the “COVID-19 vaccine AstraZeneca” might trigger the expression of antiplatelet antibodies, resulting in a condition with thrombocytopenia and venous thrombotic events (eg, intracranial venous sinus thrombosis).	Laboratory and imaging findings - ↓ Platelets count (3/3) - ↑ D-dimers (3/3) - (+)ve PF4 antiplatelet antibodies (3/3) - SARS-CoV-2 antibody test (+)ve Spike protein (3/3) (-)ve PCR (3/3) - (-)ve HIPA antibody (3/3) - (-)ve Thrombophilia markers (3/3) - MRI: SAH and thrombosed at sigmoid sinus (1/3) - MRI: thrombotic occlusion of the superior sagittal sinus and an acute intracerebral hematoma in the left occipital lobe. (1/3) - MRI: thrombotic occlusion of the straight sinus, a non-occlusive thrombus in the superior sagittal sinus, and congestive edema of thalami. (1/3) - DSA: the occlusion of the ascending cerebral veins and sinuses. (1/3) - DSA: the occlusion of the sinuses (2/3) - Repeat-MRI: the intracranial venous sinuses' recanalization without new hemorrhage or edema (3/3) Medical treatment Anticoagulation treatment - Enoxaparin→dabigatran (2/3) - Enoxaparin→danaparoid (1/3) Other management - Endovascular rheolysis (2/3) - Endovascular rheolysis with balloon angioplasty (1/3) - Levetiracetam (1/3)

<p>[23] - Malaysia - Case report</p>	<p>- Pfizer (mRNA) - 1st dose - 16 days</p>	<p>n=1 Gender: Male Age: 49</p>	<p>Medical history - Healthy, BMI 22 - History of childhood asthma - Allergy to seafood and nonsteroidal medication - Three years prior, single-vessel CAD was treated with PTCA. Regular Medication - Dual antiplatelet therapy for a year - Single antiplatelet therapy for six months, then non-compliance</p>	<p>- Mild to moderate headache - Giddiness</p>	<p>Embolism and/or Thrombotic event(s) - CVST</p>	<p>The patient's allergic history, the immunological response to the mRNA vaccine, as well as the dysregulation of the surface receptor may have triggered or activated thrombosis formation.</p>	<p>Laboratory and imaging findings - Normal platelet - Normal D-dimer - Normal INR - Normal aPTT - CT brain: dense clot sign. - Repeat cerebral venography 2 days after the second dose of the vaccine showed a long segment-filling defect and empty delta sign within the superior sagittal sinus, extending into the torcula Herophili, left transverse sinus, and sigmoid sinus to the proximal internal jugular vein. - Repeated CT cerebral venogram 2 weeks post-treatment showed residual CVST. Medical treatment Anticoagulant treatment - Clexane→apixaban - Clopidogrel</p>
----------------------------------------------	-----------------------------------------------------	-----------------------------------------	-------------------------------------------------------------------------------------------------------------------------------------------------------------------------------------------------------------------------------------------------------------------------------------------------------------------------------------------------------------	----------------------------------------------------	--------------------------------------------------------------	---------------------------------------------------------------------------------------------------------------------------------------------------------------------------------------------------	---------------------------------------------------------------------------------------------------------------------------------------------------------------------------------------------------------------------------------------------------------------------------------------------------------------------------------------------------------------------------------------------------------------------------------------------------------------------------------------------------------------------------------------------------------------------------------------------------------------------------------------------------------

Notes: “↑”: High; “↓”: Low; “N”: Normal; “N/A”: Not Available; “(+ve)”: Positive; “(-)ve”: Negative, → “switch to”.

Abbreviations: AAT, Acute Aortic Thrombosis; AMI, Acute Myocardial Infarction; CAD, Coronary Artery Disease; CVA, Cerebrovascular Accident; CVST, Cerebral Venous Sinus Thrombosis; DIC, Disseminated intravascular coagulation DM, Diabetes Mellitus; DVT, Deep Vein Thrombosis; ICH, Intracerebral Hemorrhage; IJVT, Internal Jugular Vein Thrombosis; IPH, Intraparenchymal hemorrhage; ITP, Immune Thrombocytopenia; IVC thrombosis, Inferior Vena Cava thrombosis; MCA infarct, Middle Cerebral Artery infarct; PE, Pulmonary Embolism; PVT, Portal Vein Thrombosis; SAH, Subarachnoid Hemorrhage; VITT, Vaccine-induced Thrombotic Thrombocytopenia; aPPT, Activated Partial Thromboplastin Time; BMI, Body Mass Index; CTA, Computed Tomography Angiography; CTPA, Computed Pulmonary Tomography Angiography; ECG, Electrocardiogram; ELISA, Enzyme-Linked Immunosorbent Assay HIPA, Heparin-Induced Platelet Activation; HIT, Heparin-Induced Thrombocytopenia; INR, International Normalized Ratio; IVIG, Intravenous Immunoglobulin; LMWH, Low Molecular Weight Heparin; MRI, Magnetic Resonance Imaging; PF-4, Platelet Factor-4; POBA, Plain Old Balloon Angioplasty; PTCA, Percutaneous Transluminal Coronary Angioplasty; DSA, Digital Subtraction Angiography.

Quality Assessment

The assessment of the risk of bias is presented in [Supplementary Data 2](#).

Findings of the Review

Characteristics of Participants (See [Table 3](#))

Gender and Age

Twelve studies identified a total of 63 participants; 46 females (73.02%)^{12–16,18–20,22} and 17 males (26.98%)^{15–19,21,23} who experienced embolism and/or thrombotic event(s). The majority of the studies reported participants' age ranges from 22 to 49 years (n = 9 studies),^{15–23} followed by 50–65 years (n = 6 studies),^{12–14,18–20} 12–21 years (n = 2 studies),^{19,20} and older than 65 years (n = 2 studies).^{19,20}

Medical History and Prescription Medication

Medical history and prescription medication were classified as known and unknown thrombosis risk factors based on previous literature.^{26,27}

There were participants with known thrombosis risk factors shown in five studies (10 participants),^{12,18–20,23} comprising type 2 diabetes mellitus (n = 1 study; 1 participant),¹² hypertension (n = 1 study; 1 participant),¹⁸ single-vessel coronary artery disease (SVD) (n = 1 study; 1 participant),²³ previous deep venous thrombosis (DVT) (n = 1 study; 1 participant),¹⁹ and obesity (n = 1 study; 6 participants).²⁰ Other medical histories were cited in seven studies (14 participants).^{12,14–18,20}

Prescription medications known to cause thrombosis were reported as the following; contraceptive tablets or vaginal rings (n = 4 studies; 5 participants)^{12,18–20} and hormone-replacement treatment (n = 1 study; 1 participant).¹⁸ Other prescription medications are recorded in [Table 3](#) (n = 4 studies; 14 participants).^{12,16–18}

Vaccine Information

Among the 12 studies included, two types and three different brands of COVID-19 vaccines were reported being used; BNT162b2, EP2163 mRNA COVID-19 vaccine, or Pfizer (n = 2 studies; 2 participants),^{12,23} Ad26.COVS.S COVID-19 viral vector vaccine, or Janssen/Johnson & Johnson (J&J) (n = 1 study; 10 participants),²⁰ and Oxford-AstraZeneca ChAdOx1 nCoV-19, Covishield, adenoviral vector vaccine, Vaxzevria, or AstraZeneca (AZ) (n = 9 studies; 49 participants).^{13–19,21,22} Forty-seven participants of those included in the literature had embolism and/or thrombotic adverse reaction(s) after the first dose of vaccination (n = 9 studies; 47 participants)^{12,13,15,17–21,23} and four studies (16 participants)^{14–16,22} did not provide data about the sequence of dosing of the vaccination. Time duration from vaccination to the admission of embolism and/or thrombotic adverse reaction(s) ranged across studies from 0 to 28 days; 0–7 days (n = 7 studies; 11 participants),^{12,15,17–19,21,22} 8–14 days (n = 8 studies; 35 participants),^{13–20,22} 15 to 21 days (n=5 studies; 12 participants),^{15,19,20,22,23} 22–28 days (n = 3 studies; 5 participants),^{16,19,20} and 29–35 days (n = 1 study; 1 participant).¹⁶

Potential Mechanism

Potential mechanisms of embolism and/or thrombotic event(s) after the COVID-19 vaccination are reported in [Table 2](#). The review found that vaccine-induced thrombotic thrombocytopenia (VITT) was reported as the potential mechanism of embolism and/or thrombotic event(s) after the COVID-19 vaccination most frequently (n = 5 studies).^{12,15,18,19,21} Amidst these studies, one study reported that VITT occurs due to two possible mechanisms.¹⁵ First, the adenovirus binds to platelets and causes platelet activation, and free DNA in the vaccine could be a potential trigger of these Platelet Factor 4 (PF4) reactive antibodies. Another study demonstrated that exposure to AZ might trigger the expression of antiplatelet antibodies, resulting in VITT.²² Three studies reported that embolism and/or thrombotic event(s) after the COVID-19 vaccination were conceivably due to the immunological mechanism, autoimmune heparin-induced thrombocytopenia (HIT)-like mechanism in which platelet-activating antibodies develop without heparin exposure is suspected.^{13,17,20}

Other potential mechanisms were demonstrated in the included studies. One study showed that COVID-19 vaccine recipients who have a history of allergy to the immunological response to the mRNA vaccine and the dysregulation of the surface receptor may have triggered or activated thrombosis formation.²³ Another study showed that disseminated

Table 3 Characteristics of Participants in the Included Studies

Reference	[12]	[13]	[14]	[15]	[16]	[17]	[18]	[19]	[20]	[21]	[22]	[23]	Total Number of Cases	Total Number of Studies
Participants' demographic														
Gender														
Female	1	1	1	9	1		4	14	12		3		46	9
Male				2	1	2	1	9		1		1	17	7
Age*														
12–21 years								1	1				–	2
22–49 years				1	1	1	1	1	1	1	1	1	–	9
50–65 years	1	1	1				1	1	1				–	6
Older than 65 years								1	1				–	2
Medical History														
Known risk for Thrombosis**													10	5
• Type 2 diabetes mellitus	1												1	1
• Hypertension							1						1	1
• Single-vessel coronary artery disease												1	1	1
• Having deep venous thrombosis in the previous								1					1	1
• Obesity									6				6	1
Not considered a known risk for Thrombosis													14	8
• Post-COVID-19 infection	1								1				2	2
• von Willebrand disease				1									1	1
• Osteoarthritis	1												1	1
• Asthma							1					1	2	2
• Hypothyroidism					1				1				2	2

(Continued)

Table 3 (Continued).

Reference	[12]	[13]	[14]	[15]	[16]	[17]	[18]	[19]	[20]	[21]	[22]	[23]	Total Number of Cases	Total Number of Studies
• Migraines						1							1	1
• Meniere's disease			1										1	1
• Primary sclerosing cholangitis						1							1	1
• Pollen allergy							2						2	1
• Lumbago issues					1								1	1
No medical History					1	1	1	21		1	3		28	6
Not available				10									10	1
Prescription medications														
<i>Known risk for Thrombosis*</i>													6	5
• Contraceptive pill/Contraceptive vaginal ring	1						2	1	1				5	4
• Hormone-replacement therapy							1						1	1
<i>Not considered as a known risk for Thrombosis</i>													14	4
• Antihypertensive agents							1						1	1
• Metformin	1												1	1
• Levothyroxine					1								1	1
• Ursodeoxycholic acid						1							1	1
• Budesonide						1							1	1
• Sumatriptan						1							1	1
• Amitriptyline						1							1	1
• Single antiplatelet therapy												1	1	1
Reported have not had prescription medication		1	1		1	1	2	22			3		31	7
Not available				11						1			12	2

Vaccine information														
Typelbrand of vaccine														
Pfizer	1											1	2	2
Janssen/Johnson & Johnson								12					12	1
AstraZeneca		1	1	11	2	2	5	23		1	3		49	9
Dosage														
1 st dose	1	1		1		2	5	23	12	1		1	47	9
Not available			1	10	2						3		16	4
Time duration from vaccination to the admission of embolism and/or thrombotic event(s)														
0–7 days	1			4		1	2	1		1	1		11	7
8–14 days		1	1	6		1	3	18	4		1		35	8
15–21 days				1				3	6		1	1	12	5
22–28 days					1			1	2				4	3
29–35 days					1								1	1

Notes: *Some studies did not specify the individual age of the patients. Therefore, the total number of participants in each age range cannot be specified. **Medical history and regular medication were considered as a known risk for thrombosis and/or embolism events according to the previous literature.^{26,27}

intravascular coagulation (DIC) is the possible mechanism of embolism and/or thrombotic event(s) that occur with COVID-19 recipients after getting vaccinated.¹⁴ One study reported as unclear mechanism.¹⁶

Clinical Presentation, Embolism and/or Thrombotic Event(s), Coexisting Conditions

The ICD-10 WHO Version 2016 was utilized to classify as shown in [Table 4](#).

Clinical Presentation

Not all included studies provided data regarding presenting symptoms of embolism and/or thrombotic event(s). Of the 12 studies with data available, conditions related to diseases of the musculoskeletal system and connective tissue were reported in five studies (8 events),^{12,16–18,20} and conditions related to diseases of the circulatory system were reported in three studies (4 events).^{12,16,20} Other findings included conditions related to diseases of eye and adnexa (n = 6 studies; 10 events),^{13,17,18,20,22} diseases of nervous system (n = 4 studies, 7 events),^{14,17,18,22} general symptoms and signs (n = 7 studies; 26 events),^{15,17,18,20–23} and symptoms and signs involving the digestive system and abdomen (n = 4 studies; 9 events).^{15,18,20,21}

Embolism and/or Thrombotic Event(s)

Ten studies reported 49 incidents of cerebrovascular diseases.^{13–15,17–23} Other embolism and/or thrombotic events were intracardiac thrombosis (n = 2 studies; 2 events),^{15,19} ischemic heart diseases (n = 2 studies; 2 events),^{14,19} pulmonary heart disease and diseases of pulmonary circulation (n = 5 studies; 13 events),^{12,14,15,19,20} and diseases of arteries, arterioles and capillaries (n = 2 studies; 2 events).^{15,19} Also, diseases of veins, lymphatic vessels and lymph nodes were reported as embolism and/or thrombotic events, and this category included phlebitis and thrombophlebitis (n = 5 studies; 9 events),^{12,15,16,19,20} portal vein thrombosis (n = 4 studies; 7 events),^{14,18–20} and other venous embolism and thrombosis (n = 6 studies; 21 events).^{13–15,18–20}

Coexisting Conditions

Among coexisting conditions based on data available, diseases of the circulatory system were most frequently cited (n = 7 studies; 22 events).^{14,15,17–21} Subsequently, diseases of the blood and blood-forming organs and certain disorders involving the immune mechanism were reported in one study (5 events).¹⁹

Clinical Management

Details are summarized in [Figure 2](#).

Laboratory and Imaging Findings

COVID-19 and coagulation tests, including platelet, D-dimer, fibrinogen, INR, aPTT, and heparin-PF4 ELISA test, were assessed in 12 studies,^{12–23} as demonstrated in [Table 5](#). The data showed that nine studies (59 participants)^{13–15,17–22} reported thrombocytopenia. Another three studies had a normal level of platelet count.^{12,16,23} Additionally, ten studies (71.43%)^{12,14–16,18–23} assessed D-dimer levels, which showed elevated D-dimer levels in eight studies (51 participants)^{12,14,15,18–22} and normal level in two studies (3 participants).^{16,23} However, eight studies^{12,14,15,17–21} that assessed fibrinogen levels reported a variety of ranges from low (n = 6 studies, 31 participants)^{15,17–21} to normal (n = 5 studies; 16 participants),^{14,15,18–20} and high (n = 3 studies; 4 participants).^{12,15,19}

INR and aPTT were assessed in six studies.^{12,15,18–20,23} Seven participants had a normal INR level (3 studies),^{15,18,23} and one study (5 participants) had a high INR level.¹⁵ Among these five studies, the majority of those participants had a normal aPTT (n = 23 participants)^{12,15,18,19,23} followed by high (n = 2 studies, 11 participants)^{15,19} and low level of aPTT (n = 1 study; 3 participants).¹⁹

To determine the cause of bleeding disorder and embolism and/or thrombotic event(s), the heparin-PF4 ELISA test was tested in seven studies (26 participants), and the results were positive.^{12,15,17,19–21} For other bleeding disorder tests, IgG and IgM antiplatelet antibodies, platelet suspension immunofluorescence test, monoclonal antibody-specific immobilization of platelet antigens assay, and serotonin release assay (SRA) were positive in the 4 patients (n = 2 studies).^{13,20}

Table 4 Clinical Presentations, Embolism and/or Thrombotic Events, and Coexisting Conditions Classified by ICD10 (Version 2016)

Conditions Related to	References	[12]	[13]	[14]	[15]	[16]	[17]	[18]	[19]	[20]	[21]	[22]	[23]	Total Number of Events	Total Number of Events
Clinical Presentations															
Diseases of the musculoskeletal system and connective tissue														8	5
Leg pain		1				2				1				4	3
Stiff neck							1			1				2	2
Backache								1						1	1
Neck pain										1				1	1
Diseases of the circulatory system														4	3
Edema leg due to venous obstruction		1				1				2				4	3
Diseases of the eye and adnexa														10	6
Epiphora			1											1	1
Vitreous floaters											1			1	1
Ocular pain			1											1	1
Diplopia			1											1	1
Photophobia							1			1				2	2
Visual disturbances							1	1						2	2
Hemianopia												1		1	1
Eye deviation										1				1	1
Diseases of the nervous system														7	4
Hemiplegia				1			1	1				1		4	4
Other specified headache syndromes							1					1		2	2
Generalized epileptic seizure												1		1	1
Diseases of oral cavity, salivary glands, and jaws														1	1
Gingival hemorrhage							1							1	1

(Continued)

Table 4 (Continued).

Conditions Related to	References	[12]	[13]	[14]	[15]	[16]	[17]	[18]	[19]	[20]	[21]	[22]	[23]	Total Number of Events	Total Number of Events
General symptoms and signs														26	7
Chills					1									1	1
Fever					1			1		1				3	3
Headache							1	3		4	1	2	1	12	6
Lethargy								1		2				3	2
Weakness										2				2	1
Seizure										3				3	1
Dizziness and giddiness										1			1	2	2
Symptoms and signs involving the digestive system and abdomen														9	4
Nausea and vomiting					1					4	1			6	3
Epigastric pain					1			1		1				3	3
Symptoms and signs involving the nervous and musculoskeletal systems														1	1
Other and unspecified lack of coordination							1							1	1
Symptoms and signs involving speech and voice														4	2
Aphasia										2		1		3	2
Speech disturbances, not elsewhere classified										1				1	1
Symptoms and signs involving cognition, perception, emotional state and behavior														1	1
Somnolence												1		1	1
Symptoms and signs involving the skin and subcutaneous tissue														3	2
Petechiae						1	1							2	2
Cyanosis						1								1	1
Embolism and/or Thrombotic Events															
Cerebrovascular diseases														49	10
Cerebral venous sinus thrombosis				1	9		2	4	13	12	1	3	1	46	9

Middle cerebral artery infarct								2						2	1
Ischemic stroke		1												1	1
Intracardiac thrombosis, not elsewhere classified														2	2
Right intraventricular thrombosis				1				1						2	2
Ischaemic heart diseases														1	1
Myocardial Infarction			1					1						1	1
Pulmonary heart disease and diseases of pulmonary circulation														13	5
Pulmonary embolism	1		1	3				5	3					13	5
Diseases of arteries, arterioles, and capillaries														2	2
Aortoiliac thrombosis				1										1	1
Acute aortic thrombosis								1						1	1
Diseases of veins, lymphatic vessels and lymph nodes, not elsewhere classified														37	8
<i>Phlebitis and thrombophlebitis</i>														9	5
Phlebitis and thrombophlebitis of other deep vessels of lower extremities, including Deep vein thrombosis, Unspecified deep thrombophlebitis in lower limbs	1				2			2	3					8	4
Iliofemoral vein thrombosis				1										1	1
<i>Portal vein thrombosis</i>														7	4
Portal vein thrombosis			1					1	3	2				7	4
<i>Other venous embolism and thrombosis</i>														21	6
Hepatic vein thrombosis			1					1		1				3	3
Hemiazygos vein thrombosis								1						1	1
Azygos vein thrombosis								1						1	1
Superior mesenteric vein thrombosis										1				1	1
Splanchnic vein thrombosis				3				1		1				5	3
Several basivertebral veins thrombosis								1						1	1

(Continued)

Table 4 (Continued).

Conditions Related to	References	[12]	[13]	[14]	[15]	[16]	[17]	[18]	[19]	[20]	[21]	[22]	[23]	Total Number of Events	Total Number of Events
Inferior vena caval thrombosis					1									1	1
Internal jugular vein thrombosis									1	6				7	2
Bilateral superior ophthalmic vein thrombosis			1											1	1
Other														1	1
Ischemic bowel with infarctions										1				1	1
More than one embolism and/or thrombotic events		1	1	1	4									7	4
Coexisting Conditions															
Diseases of the circulatory system														22	7
Intracerebral hemorrhage				1					3	7				11	3
Cerebellar hemorrhage								1						1	1
Cerebral hemorrhage					1									1	1
Subarachnoid hemorrhage							2		1					3	2
Intraparenchymal hemorrhage							2							2	1
Parenchymal hemorrhage											1			1	1
Right frontal hemorrhage								1						1	1
Sigmoid sinuses and hemorrhagic infarction								1						1	1
Superficial cerebral veins and right cerebellar hemorrhagic infarction								1						1	1
Diseases of the nervous system														1	1
Cerebellar edema								1						1	1
Endocrine, nutritional, and metabolic diseases														1	1
Adrenal hemorrhage									1					1	1
Diseases of the blood and blood-forming organs and certain disorders involving the immune mechanism														5	1
Bleeding events/Hemorrhage symptoms only									1					5	1

Note: Items in bold and italic forms indicate section classification of the ICD10.

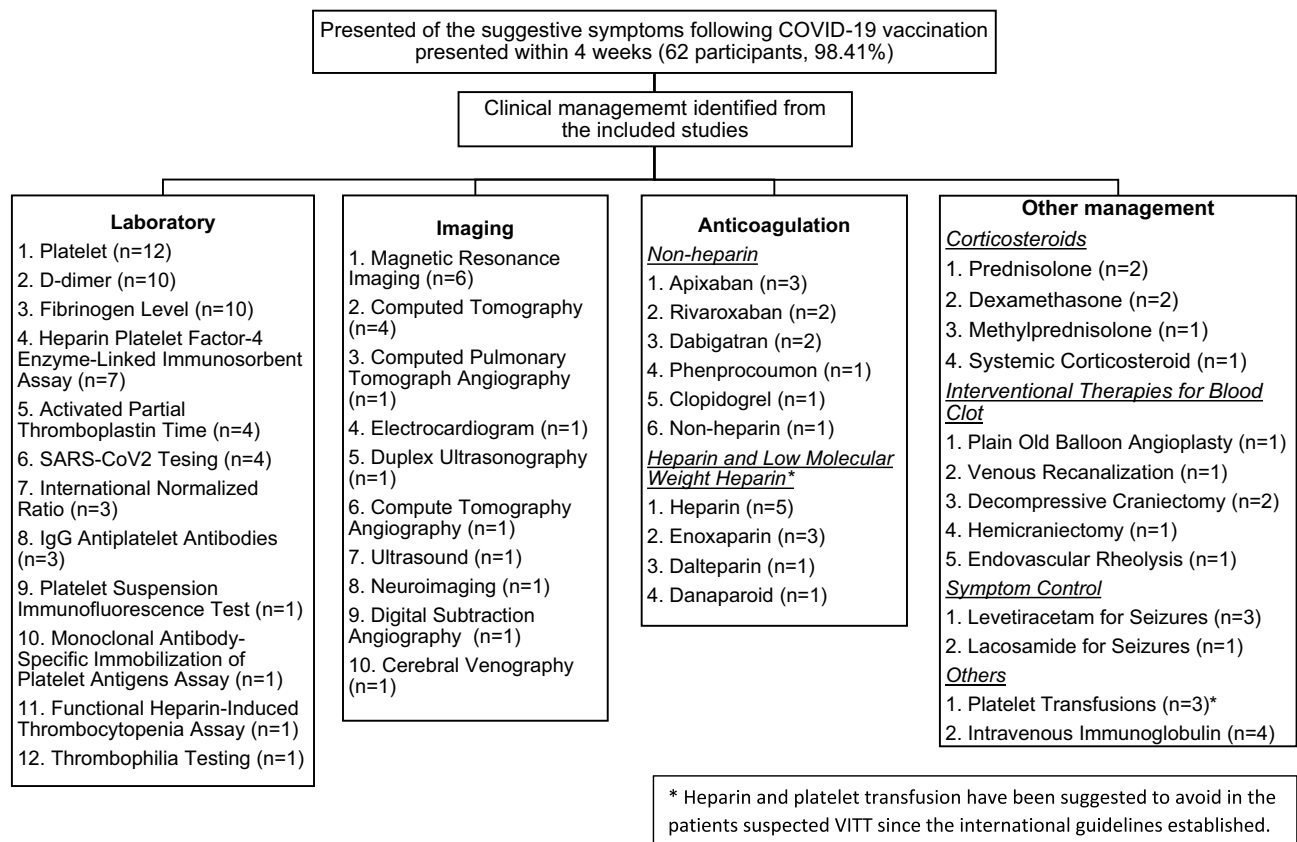


Figure 2 Clinical management of embolism and/or thrombotic event(s) after the COVID-19 vaccination identified from the included studies. This figure summarizes the clinical management reported in the majority of the included participants who had suggestive symptoms following COVID-19 vaccination. The figure shows the number of studies that reported using different laboratory and imaging to make diagnosis, and receiving different types of interventions, such as anticoagulation therapy, corticosteroids, or interventional therapies for blood clot.

Also, in some studies, the participants were further tested (n = 3 studies; 15 participants)^{13,20,22} in thrombophilia, immunologic and functional HIT assays, and IgG antibodies against PF4, which showed negative.

In addition, embolism and/or thrombotic event(s) were evaluated with imaging studies, such as positive duplex ultrasonography (n = 1 study; 1 participant)¹² and ultrasound (n = 1 study; 2 participants)¹⁶ for evidence of DVT. For those who were diagnosed with CVST after vaccination with COVID-19 vaccine, they were tested with magnetic resonance imaging (MRI) (n = 3 studies; 5 participants),^{14,20,22} computed tomography (CT) (n = 5 studies; 12 participants),^{14,18,20,21,23} and digital subtraction angiography (DSA) (n = 1 study; 3 participants).²²

Medical Treatment

Most participants were clinically managed by anticoagulation treatment and other treatments, including intravenous steroids, blood products, intravenous immunoglobulin (IVIG), thrombolysis procedures, and symptom management. Participants in eight studies (21 participants) received heparin therapy and low molecular weight heparin (LMWH).^{12,13,15,17,18,20,22,23} Of eight studies, six studies (11 participants) received heparinization therapy and LMWH as an initial treatment. Then, the participants' treatment was subsequently switched to non-heparin treatment, such as rivaroxaban, phenprocoumon, apixaban, and dabigatran.^{12,13,15,20,22,23} Some studies (n = 4 studies; 10 participants) were continued on heparin and LMWH from the beginning of treatment.^{15,17,18,22} Also, some studies (n = 4 studies; 8 participants) reported that participants were initially treated with non-heparinization treatment, such as rivaroxaban, apixaban, dabigatran, and clopidogrel after diagnosis of embolism and/or thrombosis was made.^{16,20,21,23}

Table 5 Laboratory Findings of Included Studies

References/ Sample Size (n)	Platelet	D- Dimer	Fibrinogen	Initial		SAR-CoV-2		Heparin-PF4 ELISA Test	Other Laboratory Findings Regarding the Bleeding Disorder
				INR	aPTT	Serology	Viral assay		
[12] n= 1	N (1/1)	↑ (1/1)	↑ (1/1)		N (1/1)			(+) ve (1/1)	
[13] n= 1	↓ (1/1)*								<ul style="list-style-type: none"> • (+) ve IgG antiplatelet antibodies (1/1) • Borderline IgM antiplatelet antibodies (1/1) • (+)ve platelet suspension immunofluorescence test (1/1) • (+)ve monoclonal antibody-specific immobilization of platelet antigens assay (1/1) • (-ve) IgG antibodies against PF4 (1/1)
[14] n= 1	↓ (1/1)*	↑ (1/1)	N (1/1)						
[15] n= 11	↓ (10/10)	↑ (7/7)	↑ (1/6) N (1/6) ↓ (4/6)	↑ (6/7) N (1/7)	↑ (6/7) N (1/7)			(+) ve (9/9)	
[16] n= 2	N (2/2)	N (2/2)							
[17] n= 2	↓ (2/2)		↓ (2/2)				• (-) ve PCR (2/2)	(+) ve (1/1)	
[18] n= 5	↓ (5/5)	↑ (5/5)	N (2/5) ↓ (3/5)	N (5/5)	N (5/5)	<ul style="list-style-type: none"> • (+) ve Spike protein (5/5) • (-) ve Nucleocapsid Antibody (5/5) 			
[19] n= 23	↓ (22/22)	↑ (21/21)	↑ (2/23) N (8/23) ↓ (13/23)		↑ (5/23) N (15/23) ↓ (3/23)			(+) ve (22/23)	
[20] n= 12	↓ (12/12)	↑ (12/12)	N (4/12) ↓ (8/12)	**	**	<ul style="list-style-type: none"> • (-)ve Nucleocapsid Antibody (2/2)# • (-)ve Antibody (1/1) # • - (-)ve Spike antibody (1/1) # 	<ul style="list-style-type: none"> • (-) ve PCR (10/10) • (-)ve antigen (1/1) 	(+) ve (11/11)	<ul style="list-style-type: none"> • (-)ve Thrombophilia testing (11/11) • (-)ve SRA (8/9) • (+)ve SRA (1/9) • (-)ve LIA (3/3) • (-)ve PEA (1/1)
[21] n= 1	↓ (1/1)	↑ (1/1)	↓ (1/1)					(+) ve (1/1)	
[22] n=3	↓ (3/3)	↑ (3/3)				• (+) ve Spike antibody (3/3)	• (-) ve PCR (3/3)	(+) ve (3/3)	• (-)ve Extensive tests for thrombophilia markers (3/3)
[23] n=1	N (1/1)	N (1/1)		N (1/1)	N (1/1)				

Summary of finding	N (3/62; 4.84%) ↓ (59/62; 95.16%)	↑ (51/54; 94.44%) N (3/54; 5.56%)	↑ (4/51; 7.84%) N (16/51; 31.37%) ↓ (31/51; 60.78%)	↑ (6/13; 46.15%) N (7/13; 53.84%)	↑ (11/37; 22.92%) N (23/37; 62.16%) ↓ (3/37; 8.11%)	<ul style="list-style-type: none"> ● (-)ve Nucleocapsid Antibody (7/7; 100%) ● (-)ve Antibody (1/1; 100%) ● (-)ve Spike antibody (1/9; 11.11%) ● (+)ve Spike antibody (8/9; 88.89%) 	<ul style="list-style-type: none"> ● (-) ve PCR (15/15) 100% ● (-)ve antigen (1/1) 100% 	(+) ve (48/49) 97.96%	
--------------------	--------------------------------------	--------------------------------------	-----------------------------------------------------------	--------------------------------------	-----------------------------------------------------------	-------------------------------------------------------------------------------------------------------------------------------------------------------------------------------------------------------------------------------	-----------------------------------------------------------------------------------------------------------------	-----------------------	--

Notes: Symbol: “↑”: High; “↓”: Low; “N”: Normal; “-”: Not available; “(+ ve)”: Positive; “(-)ve”: Negative. *The study indicated that patients have thrombocytopenia without revealing the platelet values. **The study did not show the interpretation or the reference range of the result, resulting in being unable to interpret. #The study indicated that Information was not available to distinguish whether antinucleocapsid or anti-spike SARS-CoV-2 antibodies were assessed.

Abbreviations: aPTT, activated partial thromboplastin time; ELISA, enzyme-linked immunosorbent assay; INR, international normalized ratio; LIA, latex immunoturbidimetric assay; PCR, polymerase chain reaction; PEA, P-selectin expression assay; PF4, platelet factor 4; SRA, serotonin release assay.

In addition to anticoagulation, other treatments were used to manage the patient with embolism and/or thrombotic event(s) after COVID-19 vaccination, indicating in some studies that additional treated with systemic corticosteroids. Moreover, immunoglobulin therapy was used in some participants (n = 4 studies; 13 participants).^{17,18,20,21}

Discussion

VITT or TTS may result in embolism and/or thrombotic event(s) after vaccine administration.⁵ Several types of vaccines were documented to develop a rare adverse effect of acute thrombocytopenia after vaccinations, such as live-attenuated (MMR and varicella-zoster), recombinant DNA (hepatitis B virus), and inactivated vaccines (influenza).⁶ In terms of COVID-19 vaccination, it is thought to be due to autoantibodies directed against PF4 that activate platelets and cause venous and arterial thromboembolism in the absence of heparin exposure, similar to other types of spontaneous HIT.²⁸ Despite unclear mechanisms of embolism and/or thrombotic event(s) following COVID-19 vaccination, thrombocytopenia is a condition reported in the majority of included studies.^{12,13,15,17–22}

Approach to the Clients

A previous study regarding the management of thrombocytopenia suggested performing a detailed history taking, including a family history of thrombocytopenia, medical history (recent viral and bacterial infections, vaccinations, malignancies, recent travels, and recent transfusions), and concomitant medications (heparin), in order to find causes and treat appropriately.²⁹ In particular COVID-19 vaccination, there are several aspects to consider VITT.

Age, Gender, and Prescription Medications

Individuals who had thromboembolic events reported following COVID-19 vaccination occurred most frequently in participants aged 22–49, followed by 50–65 years, and least frequently in participants aged 12–21 and 65 years and older.^{12,13,15,17–22} The scoping review's findings, similar to current statistics from other studies, indicated that younger individuals (18–55 years old) are more likely to develop thrombosis with thrombocytopenia syndrome (TTS) following COVID-19 adenovirus vector-based (AZ and J&J) vaccinations than older adults (56 years and older).⁵ Additionally, there are gender-specific risk factors among females, such as oral contraceptive pill usage and pregnancy/postpartum period.³⁰ To our knowledge, estrogen-containing oral contraceptive pills (EoCP) are well known for increasing the risk of VTE. The risk is greater with early usage, particularly within the first 6–12 months.¹²

Types of Vaccines

Ten of the 12 studies reviewed^{13–22} reported embolism and/or thrombotic event(s) after viral vector vaccines (AZ and J&J), while the other two included studies on mRNA vaccines (Pfizer).^{12,23} Vaccine technologies and manufacturing among these potential COVID-19 vaccines are different, suggesting that clot adverse reactions are more prevalent following one type of vaccine than any other type. Among the included studies, viral vector vaccines are the most predominant type of vaccine causing embolism and/or thrombotic event(s).^{13–22}

Sequence of Dose

In all 12 studies reviewed, embolism and/or thrombotic event(s) occurred after the first dose of the COVID-19 vaccination, consistent with other research findings. In contrast, one case report described a worsening symptom of CVST after the second dose of mRNA Pfizer vaccine.²³ In this case, the participant presented with mild to moderate headache and giddiness 16 days after the first dose but refused medical treatment due to the participant's consideration from the exertion of working. The second dose was administered, and the participant reported worsening symptoms in the following two days. The symptoms may either progress or are induced by the second dose.

In addition, as COVID-19 has constantly been evolving, the CDC encouraged to receive a booster dose.³¹ After the first, second, and booster doses of COVID-19 vaccination, individuals and health-care providers should be aware of and closely observe any adverse reactions. A further investigation comparing an individual who received the first, second, additional, and booster doses should be done.

Suggested Interval for VITT Surveillance

VITT is suspected in individuals who develop thrombocytopenia and/or thrombosis following vaccine administration.³² The suggested interval for VITT surveillance following COVID-19 vaccination recommended by Warkentin and Cuker is 5–30 days post-vaccination.³² As mentioned in previous studies reviewed of the 12, the time interval 5–30 days post-vaccination may be an appropriate surveillance period for VITT for individuals and health-care providers.^{22,33} In the studies reviewed, the most commonly reported time frame after viral vector vaccination events occurred during 8–14 days. The longest time frame found after viral vector vaccination to admission was 29 days after the first dose of the AZ.¹⁶

Among the 12 studies reviewed, individuals with VITT were likely to seek medical assistance when more aggressive symptoms developed, such as sudden onset leg pain, orbital pain, severe headache, visual disturbance, and hemiparesis. For these reasons, recent vaccination status should be assessed.

In summary, monitoring for any adverse reactions up to 30 days post-vaccination may be appropriate. Specifically, embolism and/or thrombotic event(s) may need close observation during initially 8–14 days post-vaccination. Any adverse signs and symptoms need to be reported immediately to health-care providers.

Physical Examination

General physical examination, including inspection, palpation, percussion, and auscultation, was indicated in previous management of thrombocytopenia.²⁹ Moreover, special attention for the physical examination can be performed based on different embolisms and/or thrombotic event(s) resulting from different clinical presentations and coexisting conditions. Although not all the included studies specify clinical presentations and coexisting conditions, some specific incidents can be discussed based on the data available.

CVST was reported in 9 studies (46 events),^{14,15,17–23} and the reported data shared similar clinical presentations. Headache was the most frequent symptom stated among the reported cases.^{17–23} In addition, a review of practical guidelines for CVST reported that red flags for headache from CVST included new-onset, persistent, worse with the Valsalva maneuver, and not improved with regular analgesia.³⁴

The time interval from vaccination to the presentation of CVST is also relevant to CVST which is possibly associated with the COVID-19 vaccine. A study about clinical characteristics of CVST with VITT showed that symptoms onset began 5–24 days after the first dose of COVID-19 vaccination and congruent with the review's findings that the time interval was 2–25 days after vaccination.^{14,17,18,20–23,35} Coexisting condition also consistent with a previous study demonstrated that approximately one-third of CVST patients experienced parenchymal hemorrhage along with more severe symptoms onset.³⁶

DVT was found in four studies with 8 events reported,^{12,16,19,20} but this review also notes clinical presentation and coexisting conditions in two included studies (3 events).^{12,16} General presentations indicated in included studies are leg pain and swelling as revealed in other DVT cases.^{12,16,37} Furthermore, participants developed signs and symptoms of DVT at day 7, 27, and 29 after the first dose of Pfizer and two unknown sequences of doses of AZ, respectively.^{12,16} In contrast, an article revealed a participant who experienced DVT shortly after the second dose of the mRNA vaccine.³⁸ For coexisting conditions of DVT, one study reported that a participant developed PE.¹²

Clinical Management

The previous management of thrombocytopenia indicated that one treatment approach is removing the potential cause of thrombocytopenia, such as discontinuing medication and treating infection.²⁹ This is consistent with the review's findings that management from included studies did not continue the second dose of COVID-19 vaccination.^{13,15–19,21,22} In addition, there was evidence of positive COVID-19 cases following 14–27 days after the first dose of the COVID-19 vaccine, which is difficult to determine if they were infected prior to vaccination.³⁹ Therefore, COVID-19 RT-PCR or serology testing should be considered to evaluate the potential exposure from COVID-19 virus that may cause the thrombosis complication.

Laboratory testing is essential for differential diagnosis between isolated thrombocytopenia and pancytopenia, and CBC must be taken. Apart from platelet count that can get from CBC, the review's findings reported that D-dimer concentration, fibrinogen level, and clotting time are the initial blood tests that have been used to detect abnormal clotting activity.^{13–22} Additionally, the coagulation blood tests found in the included studies were consistent with the guideline for clinical management of thrombosis with TTS following vaccination to prevent coronavirus disease from WHO.^{5,12,15,19–21}

According to the guidelines established by WHO, the recommendation has been suggested that the individual presenting with the symptoms of TTS occurred within 30 days after the COVID-19 vaccination to be referred to a tertiary-care hospital and be managed by a multidisciplinary team.⁵ Initial assessment should include a CBC before starting empiric administration of IVIG and anticoagulation. If the patient has thrombocytopenia, such patients are considered a suspect case of VITT; the patients should be further evaluated through D-dimer, fibrinogen, heparin-PF4 ELISA, and imaging for thrombosis. When the proper diagnosis has been made, or while waiting for heparin-PF4 ELISA results, non-heparin therapy and IVIG are recommended. Although there is no evidence to confirm that using heparin in the suspected VITT case will result in an aggravated condition, five included studies have been switched the treatments from heparin to non-heparin therapy after positive results of heparin-PF4 ELISA were detected.^{12,13,15,20,22} Another critical recommendation from the WHO guideline is to oppose platelet infusion for those who have VITT in all cases except that the patients have severe thrombocytopenia and were required to proceed with emergency surgery.

For patients who have incompatible initial laboratory results with VITT, the American Society of Hematology suggests continuing assessment for VITT and using non-heparin treatment since the patients might be in an early stage of VITT.⁴⁰ Once VITT has been ruled out, or a plausible alternative diagnosis has been made, the standard treatment of embolism and/or thrombotic event(s) could be consequently given.

The findings from this review are also consistent with other guidelines published during the early phase, such as the guidelines from National Institute for Health Care Excellence and the International Society on Thrombosis and Haemostasis.^{41,42} As more information became available about VITT, diagnostic guidelines would also improve. However, due to the varied and often subtle presentations of VITT, diagnostic accuracy remain limited. The help from health-care professionals undertaking the research on this topic would be crucial to ensure that the vaccine works safely to increase vaccine confidence and trustworthiness of the healthcare system.

Scoping Review Limitations

Several limitations were identified in this scoping review. This scoping review included only English-language studies, so studies reported in other languages were not included in this scoping review, which may exclude some types of vaccines. For example, Sinopharm and Sinovac (inactivated virus vaccines) were developed by China, and Sputnik V (a viral vector vaccine) was developed by Russia.⁴³ In terms of the reliability of result findings, the majority of included studies are case reports and case series due to limited information in the early stage of the COVID-19 vaccine, so the results of the review should be interpreted with caution. Additionally, the majority of included studies gathered data in Europe, so the results may not be generalizable to other countries in aspects of management and variety of vaccines. Another limitation is the limited time frame only during the early development of the vaccine, which excludes a protein-based COVID-19 vaccine type (Novavax) that develops later.⁴⁴

Conclusion

The review results suggested monitoring up to 30 days post COVID-19 vaccination, especially the first dose, would be critical to observe any adverse reactions; however, embolism and/or thrombotic event(s) can also occur after that period and requires close monitoring. These suggestions were consistent with WHO guidelines for diagnosis and management of TTS following the COVID-19 vaccination developed and other guidelines at that time.

The timely development of guidelines to manage VITT and other serious side effects from newly developed guidelines is a crucial part for vaccine safety surveillance to ensure that the health-care profession will be able to identify and adequately manage the unexpected events. Meanwhile, the health-care profession is the key person to identify the incidence of side effects and the population at risk to help refine the guideline. Then, vaccine safety

surveillance should be continued to ensure that the benefit still outweighs the risk for people receiving the vaccine and help build public trust and protect lives from serious infectious diseases.

Acknowledgments

All authors made a significant contribution to the work reported, whether that is in the conception, study design, execution, acquisition of data, analysis and interpretation, or in all these areas; took part in drafting, revising or critically reviewing the article; gave final approval of the version to be published; have agreed on the journal to which the article has been submitted; and agree to be accountable for all aspects of the work.

Funding

Mahidol University provided funding for an open-access publication fee for this review.

Disclosure

The authors report no conflicts of interest in this work.

References

1. Avila J, Long B, Holladay D, Gottlieb M. Thrombotic complications of COVID-19. *Am J Emerg Med.* 2021;39:213–218. doi:10.1016/j.ajem.2020.09.065
2. Dyer O. Covid-19: US reports low rate of new infections in people already vaccinated. *BMJ.* 2021;373:n1000. doi:10.1136/bmj.n1000
3. Shahcheraghi SH, Ayatollahi J, Aljabali AA, et al. An overview of vaccine development for COVID-19. *Ther Deliv.* 2021;12(3):235–244. doi:10.4155/tde-2020-0129
4. World Health Organization. Listings of WHO's response to COVID-19; March 26, 2023. Available from: <https://www.who.int/news/item/29-06-2020-covidtimeline>. Accessed March 26, 2023.
5. World Health Organization. Guidance for clinical case management of thrombosis with thrombocytopenia syndrome (TTS) following vaccination to prevent coronavirus disease (COVID-19); March 26, 2023. Available from: <https://apps.who.int/iris/bitstream/handle/10665/342999/WHO-2019-nCoV-TTS-2021.1-eng.pdf>. Accessed March 26, 2023.
6. Olivieri B, Betterle C, Zanoni G. Vaccinations and autoimmune diseases. *Vaccines.* 2021;9(8):815. doi:10.3390/vaccines9080815
7. Tricco AC, et al. PRISMA Extension for Scoping Reviews (PRISMA-ScR): Checklist and Explanation. *Ann Intern Med.* 2018;169(7):467–473. doi:10.7326/M18-0850
8. European Medicines Agency. AstraZeneca's COVID-19 vaccine: EMA finds possible link to very rare cases of unusual blood clots with low blood platelets; March 26, 2023. Available from: <https://www.ema.europa.eu/en/news/astrazenecas-covid-19-vaccine-ema-finds-possible-link-very-rare-cases-unusual-blood-clots-low-blood>. Accessed March 26, 2023.
9. National Center for Biotechnology Information. Embolism and thrombosis; March 26, 2023. Available from: <https://www.ncbi.nlm.nih.gov/mesh/68016769>. Accessed March 26, 2023.
10. Munn Z, Barker T, Hugh, Moola S, et al. Methodological quality of case series studies. *JBI Database of Systematic Reviews and Implementation Reports.* 2019;18(10):2127–2133. doi:10.11124/JBISRIR-D-19-00099
11. Joanna Briggs Institute. Critical appraisal tools; March 26, 2023. Available from: <https://jbi.global/critical-appraisal-tools>. Accessed March 26, 2023.
12. Al-Maqbali JS, Al Rasbi S, Kashoub MS, et al. A 59-year-old woman with extensive deep vein thrombosis and pulmonary thromboembolism 7 days following a first dose of the Pfizer-BioNTech BNT162b2 mRNA COVID-19 Vaccine. *Am J Case Rep.* 2021;22:e932946. doi:10.12659/AJCR.932946
13. Bayas A, Menacher M, Christ M, Behrens L, Rank A, Naumann M. Bilateral superior ophthalmic vein thrombosis, ischaemic stroke, and immune thrombocytopenia after ChAdOx1 nCoV-19 vaccination. *Lancet.* 2021;397(10285):e11. doi:10.1016/S0140-6736(21)00872-2
14. D'Agostino V, Caranci F, Negro A, et al. A rare case of cerebral venous thrombosis and disseminated intravascular coagulation temporally associated to the COVID-19 vaccine administration. *J Pers Med.* 2021;11(4):285. doi:10.3390/jpm11040285
15. Greinacher A, Thiele T, Warkentin TE, Weisser K, Kyrle PA, Eichinger S. Thrombotic thrombocytopenia after ChAdOx1 nCoV-19 vaccination. *N Engl J Med.* 2021;384(22):2092–2101. doi:10.1056/NEJMoa2104840
16. Haakonsen HB, Nystedt A. Deep vein thrombosis more than two weeks after vaccination against COVID-19. *Tidsskr nor Laegeforen.* 2021. 141. doi:10.4045/tidsskr.21.0274
17. Mehta PR, Apap Mangion S, Bengner M, et al. Cerebral venous sinus thrombosis and thrombocytopenia after COVID-19 vaccination - a report of two UK cases. *Brain Behav Immun.* 2021;95:514–517. doi:10.1016/j.bbi.2021.04.006
18. Schultz NH, Sørvoll IH, Michelsen AE, et al. Thrombosis and thrombocytopenia after ChAdOx1 nCoV-19 vaccination. *N Engl J Med.* 2021;384(22):2124–2130. doi:10.1056/NEJMoa2104882
19. Scully M, Singh D, Lown R, et al. Pathologic antibodies to platelet factor 4 after ChAdOx1 nCoV-19 vaccination. *N Engl J Med.* 2021;384(23):2202–2211. doi:10.1056/NEJMoa2105385
20. See I, Su JR, Lale A, et al. US case reports of cerebral venous sinus thrombosis with thrombocytopenia after Ad26.COV2.S vaccination, March 2 to April 21, 2021. *J Am Med Assoc.* 2021;325(24):2448–2456. doi:10.1001/jama.2021.7517
21. Suresh P, Petchey W. ChAdOx1 nCoV-19 vaccine-induced immune thrombotic thrombocytopenia and cerebral venous sinus thrombosis (CVST). *BMJ Case Rep.* 2021;14(6):e243931. doi:10.1136/bcr-2021-243931

22. Wolf ME, Luz B, Niehaus L, Bhogal P, Bazner H, Henkes H. Thrombocytopenia and intracranial venous sinus thrombosis after “COVID-19 vaccine AstraZeneca” exposure. *J Clin Med.* 2021;10(8):1599. doi:10.3390/jcm10081599
23. Zakaria Z, Sapiai NA, Ghani ARI. Cerebral venous sinus thrombosis 2 weeks after the first dose of mRNA SARS-CoV-2 vaccine. *Acta Neurochi.* 2021;163(8):2359–2362. doi:10.1007/s00701-021-04860-w
24. World Health Organization. ICD-10 Version: 2016; March 26, 2023. Available from: <https://icd.who.int/browse10/2016/en>. Accessed March 26, 2023.
25. Moher D. Preferred Reporting Items for Systematic Reviews and Meta-Analyses: The PRISMA Statement. *Ann Intern Med.* 2009;151(4):264. doi:10.7326/0003-4819-151-4-200908180-00135
26. Gialeraki A, Valsami S, Pittaras T, Panayiotakopoulos G, Politou M. Oral contraceptives and HRT Risk of thrombosis. *Clin Appl Thromb Hemost.* 2018;24(2):217–225. doi:10.1177/1076029616683802
27. Johns Hopkins Medicines. Thrombosis; March 26, 2023. Available from: <https://www.hopkinsmedicine.org/health/conditions-and-diseases/thrombosis>. Accessed March 26, 2023.
28. Pishko AM, Cuker A. Thrombosis after vaccination with messenger RNA-1273: is this vaccine-induced thrombosis and thrombocytopenia or thrombosis with thrombocytopenia syndrome? *Ann Intern Med.* 2021;174(10):1468–1469. doi:10.7326/m21-2680
29. Izak M, Bussel JB. Management of thrombocytopenia. *F1000Prime Rep.* 2014;6:45. doi:10.12703/p6-45
30. Martín-Martos F, Trujillo-Santos J, Del Toro J, et al. Gender differences in patients with venous thromboembolism and five common sites of cancer. *Thromb Res.* 2017;151(Suppl 1):S16–s20. doi:10.1016/s0049-3848(17)30061-0
31. Centers for Disease Control and Prevention. CDC endorses ACIP’s updated COVID-19 vaccine recommendations; March 26, 2023. Available from: <https://www.cdc.gov/media/releases/2021/s1216-covid-19-vaccines.html>. Accessed March 26, 2023.
32. Cuker TEWA COVID-19: vaccine-induced immune thrombotic thrombocytopenia (VITT). Wolters Kluwer; March 26, 2023. Available from: <https://www.uptodate.com/contents/covid-19-vaccine-induced-immune-thrombotic-thrombocytopenia-vitt>. Accessed March 26, 2023.
33. Lee EJ, Cines DB, Gernsheimer T, et al. Thrombocytopenia following Pfizer and Moderna SARS-CoV-2 vaccination. *Am J Hematol.* 2021;96(5):534–537. doi:10.1002/ajh.26132
34. Ulivi L, Squitieri M, Cohen H, Cowley P, Werring DJ. Cerebral venous thrombosis: a practical guide. *Pract Neurol.* 2020;20(5):356–367. doi:10.1136/practneurol-2019-002415
35. Furie KL, Cushman M, Elkind MSV, Lyden PD, Saposnik G. Diagnosis and management of cerebral venous sinus thrombosis with vaccine-induced immune thrombotic thrombocytopenia. *Stroke.* 2021;52(7):2478–2482. doi:10.1161/strokeaha.121.035564
36. Kraljicková D, Klzo L, Krajina A, Vyšata O, Herzig R, Vališ M. Cerebral venous sinus thrombosis: clinical characteristics and factors influencing clinical outcome. *Clin Appl Thromb Hemost.* 2016;22(7):665–672. doi:10.1177/1076029615576739
37. Mayo Clinic. Deep vein thrombosis (DVT); March 26, 2023. Available from: <https://www.mayoclinic.org/diseases-conditions/deep-vein-thrombosis/symptoms-causes/syc-20352557>. Accessed March 26, 2023.
38. Carli G, Nichele I, Ruggeri M, Barra S, Tosetto A. Deep vein thrombosis (DVT) occurring shortly after the second dose of mRNA SARS-CoV-2 vaccine. *Intern Emerg Med.* 2021;16(3):803–804. doi:10.1007/s11739-021-02685-0
39. Public Health Ontario. Severe outcomes among confirmed cases of COVID-19 following vaccination in Ontario: December 14, 2020 to February 26, 2023; March 26, 2023. Available from: <https://www.publichealthontario.ca/-/media/documents/ncov/epi/covid-19-epi-confirmed-cases-post-vaccination.pdf?la=en>. Accessed March 26, 2023.
40. Bussel JB, Connors JM, Cines DB, et al. Vaccine-induced immune thrombotic thrombocytopenia. American Society of Hematology; March 26, 2023. Available from: <https://www.hematology.org/covid-19/vaccine-induced-immune-thrombotic-thrombocytopenia>. Accessed March 26, 2023.
41. Nif H, Excellence C. COVID-19 rapid guideline: vaccine-induced immune thrombocytopenia and thrombosis (VITT); 2021.
42. Thrombosis ISo, Haemostasis. ISTH interim guidance for the diagnosis and treatment on vaccine-induced immune thrombotic thrombocytopenia; 2021.
43. World Health Organization. Interim statement of the COVID-19 subcommittee of the WHO Global Advisory Committee on vaccine safety on AstraZeneca COVID-19 vaccine. *Saudi Med J.* 2021;42(5):581–582.
44. U.S. Food and Drug Administration. Coronavirus (COVID-19) update: FDA authorizes emergency use of Novavax COVID-19 vaccine, adjuvanted; March 26, 2023. Available from: <https://www.fda.gov/news-events/press-announcements/coronavirus-covid-19-update-fda-authorizes-emergency-use-novavax-covid-19-vaccine-adjuvanted>. Accessed March 26, 2023.

The Journal of Multidisciplinary Healthcare is an international, peer-reviewed open-access journal that aims to represent and publish research in healthcare areas delivered by practitioners of different disciplines. This includes studies and reviews conducted by multidisciplinary teams as well as research which evaluates the results or conduct of such teams or healthcare processes in general. The journal covers a very wide range of areas and welcomes submissions from practitioners at all levels, from all over the world. The manuscript management system is completely online and includes a very quick and fair peer-review system. Visit <http://www.dovepress.com/testimonials.php> to read real quotes from published authors.