

A Case of Genital and Extragenital Warts Unresponsive to Immunotherapy Using Measles, Mumps, Rubella Vaccine

Pati Aji Achdiat ^{1,2}, Yunitasari ¹, Hermin Aminah Usman ³, Retno Hesty Maharani ¹

¹Department of Dermatology and Venereology, Faculty of Medicine, Universitas Padjadjaran - Dr. Hasan Sadikin Hospital, Bandung, West Java, Indonesia; ²Doctoral Study Program, Faculty of Medicine, Universitas Padjadjaran – Dr. Hasan Sadikin General Hospital, Bandung, Indonesia; ³Department of Anatomical Pathology, Faculty of Medicine, Universitas Padjadjaran – Dr. Hasan Sadikin General Hospital, Bandung, Indonesia

Correspondence: Pati Aji Achdiat, Department of Dermatology and Venereology, Faculty of Medicine, Universitas Padjadjaran - Dr. Hasan Sadikin Hospital, Jl. Pasteur 38, Bandung, West Java, 40161, Indonesia, Tel +6281225955478 ext. 3449, Fax +62222032426, Email pati.aji.achdiat@unpad.ac.id

Abstract: Anogenital warts (AGWs) are globally recognized as the most common sexually transmitted infections (STIs) caused by the human papillomavirus (HPV), particularly types 6 and 11. Meanwhile, immunotherapy is one of the treatments of choice for patients with extensive AGWs. Measles, mumps, and rubella (MMR) vaccine induce the production of various T helper 1 cytokines to elicit immune responses, resulting in the clearance of both treated and untreated warts. This study reported a case of extensive genital and extragenital warts in a 53-year-old male which had occurred for five years, with no pseudo-Koebner phenomenon. The history of MMR vaccination was uncertain but the patient received oral antibiotics for one week, one month before seeking consultation. Physical examination showed extensive verrucous and hyperkeratotic papules, plaques, and nodules in the lower abdomen, pubic, inguinal, genital, and gluteal regions. Acetowhite test results were positive, while polymerase chain reaction (PCR) results were positive for HPV types 6 and 11. The patient received an intralesional injection of 0.5 mL MMR vaccine into the largest warts with a 3-week interval. However, during the one-month follow-up after the third injection, no improvement was observed in either the size or number of warts. Based on the results, several factors must be considered to determine the best candidate for immunotherapy, particularly with MMR vaccine, to achieve an optimal outcome. These factors include the active state of diseases, duration of diseases, as well as a history of sensitization, and broad-spectrum antibiotics.

Keywords: anogenital warts, human papillomavirus, immunotherapy, MMR vaccine

Introduction

Anogenital warts (AGWs) are benign proliferative lesions known to affect the epithelium of genital, anus, or perianal region.¹ Several studies have also reported an increased risk of cervical or penile malignancies related to a history of AGWs.² The etiology is human papillomavirus (HPV), particularly types 6 and 11 in 95% of cases,¹ while HPV type 16 and 18 infection can develop into malignancies in the cervical, anal, and penile area.^{3,4} This condition has become a significant public health concern with an estimated global incidence of 160–289 cases per 100,000 persons per year.¹ Based on data from the Centers for Disease Control and Prevention (CDC), HPV infections are the most frequent sexually transmitted infections (STIs) in the United States (US) accounting for 13 million incidences in 2018 and 42.5 million prevalence.⁵ Furthermore, the vast majority of recently acquired genital HPV infections seem to be subclinical.⁶ The annual incidence rate ranges from 160 to 168 per 100,000, with cases in women ranging between 103 and 168 per 100,000.⁷ The highest prevalence of HPV infection in women was observed in sub-Saharan Africa, Eastern Europe, and Latin America, while in men, the prevalence varied, with most studies reporting estimates greater than 20%. Each year, approximately 500,000 new cancers attributed to HPV infection are diagnosed.³ Most patients only notice the presence of warts, which can be asymptomatic, or itching, bleeding, and dyspareunia.^{1,6} Morphologically, AGWs are divided into condyloma acuminata (CA) with a cauliflower-like appearance, papule, keratotic, and flat-topped.⁶ Among the four types, CA is the most predominant.⁸ The transmission of genital HPV

infection mainly occurs through sexual intercourse.⁶ However, a small proportion of cases also occur by fomites which potentially contribute to the spread of lesions to extragenital areas.⁹ Risk factors of HPV infection, both low (causing AGWs) and high (associated with penile cancer), include higher sexual activity at a young age.³ The peak prevalence of AGWs occurs before 24 years in females and between 25 and 29 years in males.⁷ Other risk factors include higher number of sexual partners,¹⁰ as well as a history of phimosis, smoking,³ and chronic inflammation.³ In a previous study, history of circumcision related to religious belief was significantly associated with lower incidence of AGWs.¹¹ This condition is also considered a risk factor for penile cancer.³

AGWs typically do not cause substantial morbidity or mortality, but the high rate of recurrence might interfere with the patient's quality of life.^{12,13} When the HPV infection leads to penile cancer, the condition can be devastating, especially in advanced stages.³ Various treatment modalities are available, but there is no clear evidence supporting the superiority of any one treatment over another.^{1,6} Size, number, location, and morphology of warts should be taken into consideration when treating AGWs, as well as patient preferences and provider experiences.¹² The currently available treatments can only remove the skin lesions, not the HPV infection.⁷ Furthermore, these treatments have variable rates of efficacy and are frequently associated with recurrences.¹⁴

Recently, immunotherapy has received a growing interest in the treatment of warts. Immunotherapy works by enhancing the cell-mediated immunity (CMI) of the host, potentially eradicating the virus instead of merely removing visible skin lesions. Several immunotherapy agents have been investigated, including *Candida albicans*, measles, mumps, and rubella (MMR) vaccine, *Trichophyton*, purified protein derivative (PPD), *Mycobacterium w (Mw)*, and Bacillus Calmette–Guerin (BCG), with varying results. This study reported a case of giant CA unresponsive to immunotherapy using MMR vaccine.

Case Study

A 53-year-old Indonesian man (Asian) of Sundanese ethnicity and Muslim faith had multiple non-itchy painless skin-colored papules on the lower abdomen, including the pubic, inguinal, genital, and gluteal regions. The lesion initially appeared five years before the first visit as a skin-colored papule in size of a pinhead on the scrotum. Given that the condition was asymptomatic, the patient did not seek treatment but in the last six months, the lesions had significantly increased in number and size. The patient visited a dermatologist one month ago and was administered three different oral medications alongside an ointment. According to the doctor, these drugs were used for eliminating pruritus, “anti-inflammation”, and “antibiotic”. After taking the medication for a week, no improvement was observed. The patient was married and admitted to having only one sexual partner, the wife. There was no history of promiscuity, and on clinical evaluation, the wife did not show any sign of AGWs. Furthermore, there was no history of other STI symptoms, and the patient did not remember exactly the type of vaccine received in childhood. Physical examination indicated extensive verrucous and hyperkeratotic papules, plaques, and nodules on the lower abdomen, pubic, inguinal, genital, and gluteal region ranging from 0.3×0.3×0.2 cm to 6×3×0.7 cm (Figure 1a). No cutaneous lesions were found in any other body region, and no lymphadenopathy was observed. The acetowhite test results were positive, while laboratory examination results for HIV, syphilis, and hepatitis B were non-reactive. Genotyping with PCR showed positive results for HPV types 6 and 11. Histopathology showed keratinized stratified squamous epithelium with hyperplastic, acanthosis, hyperkeratosis, and papillomatosis figure (Figure 2a and b). Koilocytosis (Figure 2c) was observed in some nuclei, but there were no signs of malignancy. Based on the histopathological examination results, the diagnosis was concluded as CA. The patient received an intralesional injection of 0.5 mL MMR vaccine (Merck Sharp & Dohme Corp. North Carolina, USA; distributed by Merck Sharp & Dohme, Jakarta, Indonesia) into the largest wart, with a 3-week interval. The treatment response was assessed by measuring the size and number of warts at each follow-up visit. During the one-month follow-up after the third injection, no improvement was observed in either the size or number of lesions (Figure 1b–d). Moreover, there were no local adverse effects, such as pain, itching, erythema, and swelling, or systemic adverse effects, including flu-like symptoms. The patient was scheduled for electrocautery to remove visible skin lesions.

Discussion

AGWs are the most frequent STIs found worldwide.¹⁵ Based on a previous review conducted between January 2001–2012, the regional distribution of new cases per 1000,00 population was as follows: 101 to 205 in North America, 118 to 170 in Europe, and 204 in Asia.⁷ A previous study found a significant association between a history of circumcision, often related to religious belief, and a lower incidence of AGWs.¹¹ This condition is also considered a risk factor for penile cancer.³ More than 30 types of HPV are known to infect genital tract. Based on the potential of the infected cells to progress into malignancy, HPV has been divided into high- and low-risk types.¹⁶ The high-risk HPV, including types 16, 18, 26, 31, 33, 35, 39, and 45 cause malignant lesions such as carcinoma of the cervix, vulva, vagina, anus, or penis. Meanwhile, low-risk types 6, 11, 40, 42, 44, and 54 are associated with benign lesions, such as AGWs.¹⁷ The clinical manifestations of HPV infections are somewhat correlated with epithelial tropism of different types.⁶

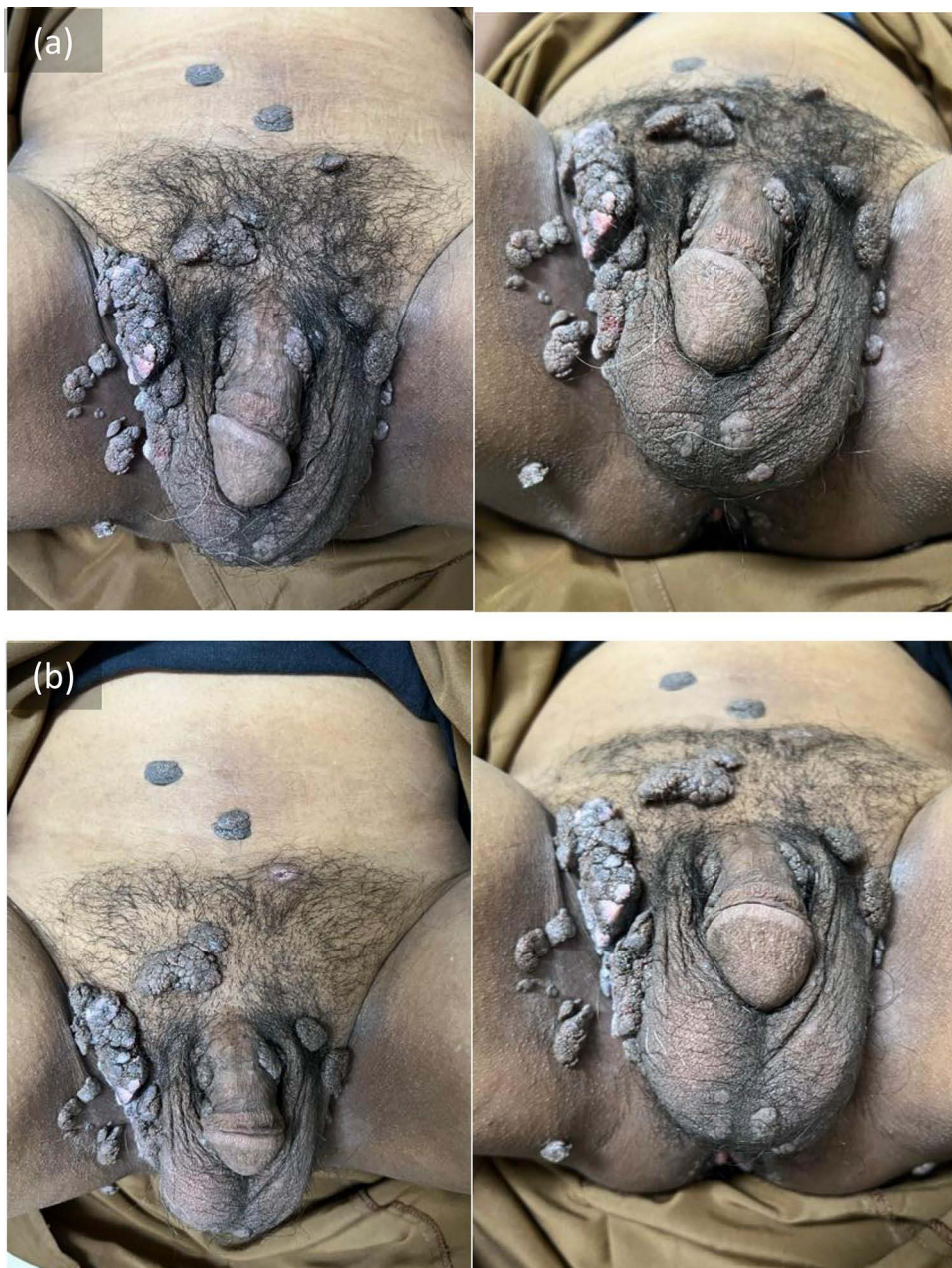

Figure 1 Continued.

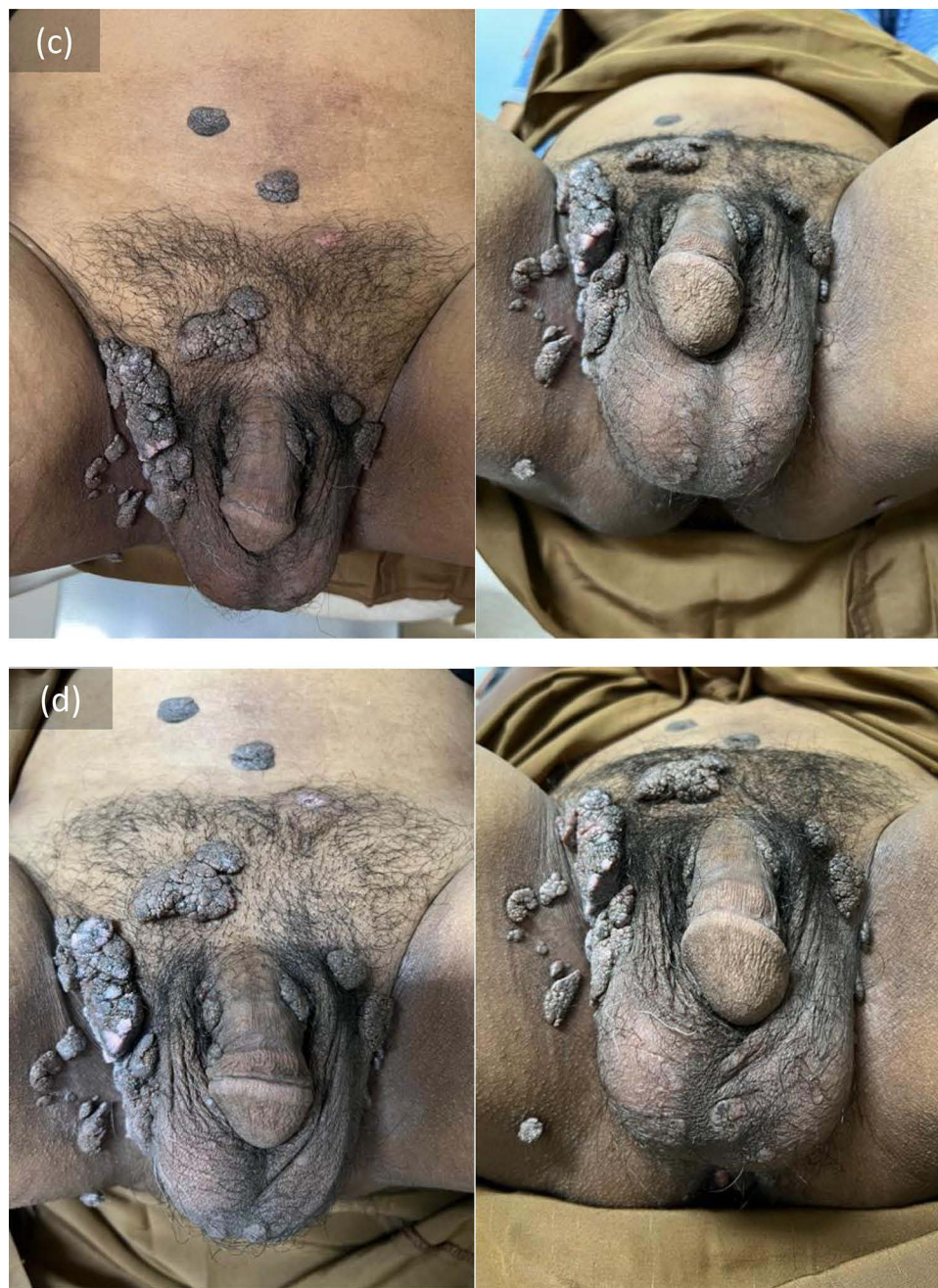

Figure 1 (a–d) Clinical manifestation before treatment (a); after first injection (b); second injection (c); and third injection (d).

The transmission of HPV mainly occurs through sexual routes, including genital, anal, or oral.⁶ During intimate contact, the basal keratinocytes, as the primary targets of HPV, are exposed through minor abrasions, providing access to infection.¹⁸ The rate of transmission between sexual partners is high and may occur without visible warts.¹ Maceration promotes infection, and it frequently results in autoinoculation to the nearby skin.¹⁸ Autoinoculation may also cause the spread of lesions to extragenital areas through contaminated objects, such as toiletries, razors, or towels.⁹ However, the occurrence of extragenital CA, in the axilla,⁹ inframammary,¹⁹ abdomen,²⁰ and pannus²¹ without associated genital infection, has been previously reported. An immunocompromised state can serve as a favorable environment for HPV infection with subsequent epidermal transformation. In cases of CA in extragenital areas, it is crucial to investigate the patient immunological status.⁹ In immunocompromised patients, AGWs can appear more extensive, multifocal, and less

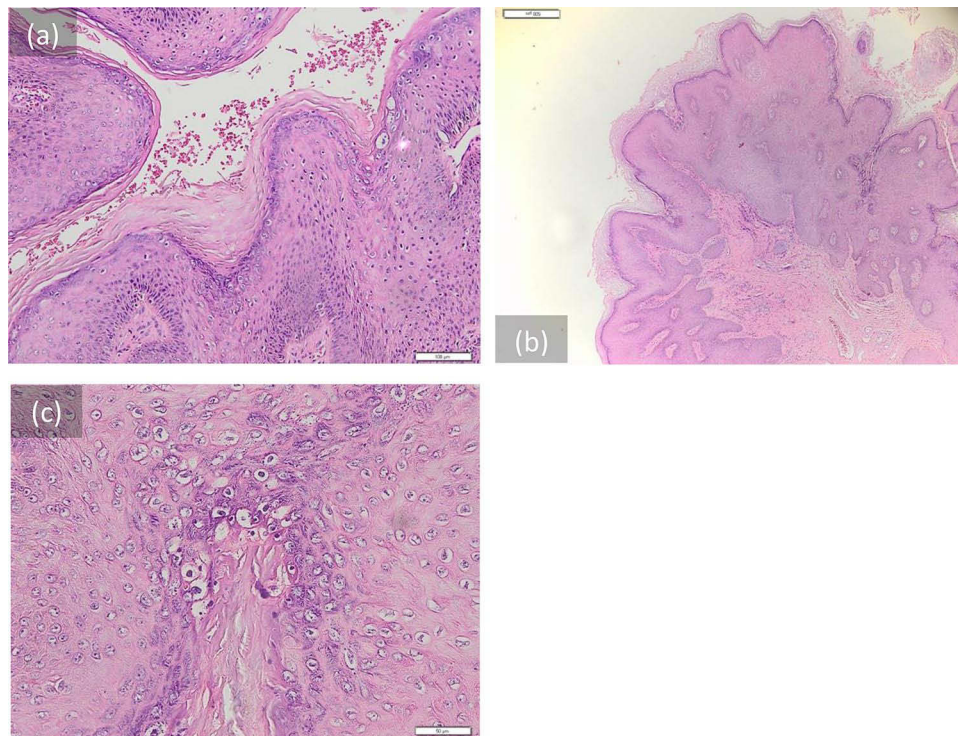


Figure 2 (a–c) Histopathological features of the lesions showed; keratinized stratified squamous epithelium with hyperplastic, acanthosis, hyperkeratosis (a); papillomatosis (b); and koilocytosis (c). No signs of malignancy were found.

responsive to treatment.⁶ The extensive lesions observed in some patients might explain the long duration of the disease and subsequent autoinoculation to extragenital areas.

The diagnosis of AGWs is established from the history and physical examination of the patient.²² Additional diagnostic tools include acetowhite test, histopathology, and HPV genotyping. Histopathology investigation is usually performed only in cases that are present with atypical features or high susceptibility to malignancy.²³ These features include acanthosis, papillomatosis, elongation and thickened rete ridges, hyperkeratosis, parakeratosis, hypergranulosis, basal cell hyperplasia, and koilocytosis.⁶ Acetowhite test in this patient showed a positive result and histopathology presented stratified squamous epithelium with hyperplastic, papillomatosis, and acanthosis, supporting the diagnosis of CA. PCR examination is used to determine the type of HPV and is only performed on lesions suspected to be malignant.⁶ In approximately 95% of cases, AGWs are usually caused by types 6 and 11.¹ Furthermore, high-risk HPV places the patient at greater risk for persistent AGWs compared to the low-risk types.⁶ PCR examination in this patient was positive for HPV types 6 and 11, but negative for 16 and 18, suggesting a lower likelihood of malignant transformation.

Several treatment options are available for AGWs, but none have proven to be superior to the others.²³ The choice of treatment is guided by location, number of lesions, size, morphology, patient preference, and provider experience. According to its mechanism of action, AGWs treatments are divided into antitumor agents, antiviral, and immunotherapy.⁶ Immunotherapy uses biological agents to enhance or suppress immune system responses against infection, disease, and malignancy,²⁴ such as penile cancer which can be treated with adoptive T-cell therapy.³ This method is considered as an alternative for cases not responding to standard treatment, recurrent cases, extensive lesions, or those in difficult-to-reach areas.²⁴ Various antigens, including *Trichophyton*, imiquimod, mumps, measles, and rubella (MMR), candida antigen, cimetidine, zinc sulfate, BCG, and topical allergens are used to stimulate immune response in AGW immunotherapy.²⁵ As a preventive measure against infection and clinical disease including AGWs and penile cancer, the quadrivalent HPV vaccine directed against types 6, 11, 16, and 18 has shown to be highly efficacious.³

Measles, mumps, and rubella vaccine contains live, attenuated forms of measles, mumps, and rubella virus.²⁶ Combining three antigens results in a stronger immune response against HPV through the production of various T

helper 1 (Th1) cytokines, such as IL-2, IL-4, and TNF- α .²⁷ It also activates the delayed-type hypersensitivity reaction to both injected antigens and the viruses causing warts. Consequently, the elicited immune responses eliminate both the treated and untreated lesions.^{26,27} In immunocompetent patients, Th1 CD4+ release different types of cytokines, including IFN- γ , IL-2, and IL-12. Interleukin-2 stimulates the maturation of cytotoxic T cells and enhances natural killer (NK) cells. One of the main functions of these cells is cytotoxicity, which refers to the ability to recognize and eliminate virus-infected cells, as well as fight against intracellular bacteria and certain types of malignancy.²⁸

Several studies have investigated the efficacy of MMR vaccine in the treatment of AGWs. An open-label study by Sharma and Agarwal²⁹ on 35 AGW patients using 0.5 mL MMR vaccine, with a 3-week interval, reported a 98% response rate after three sessions of treatment. A case report of two patients by Meena et al³⁰ also used a similar protocol and recorded complete clearance in one patient after two sessions. Meanwhile, significant improvement was found in the other patient after a single session. The same dose of MMR was used with a shorter interval (two weeks) in a randomized clinical trial on 122 patients with extragenital warts. Complete response was achieved in 68%, and a statistically significant difference compared to the control group was observed ($p < 0.00001$).³¹ Al-Qassabi et al conducted a two-case study of genital warts using higher doses of MMR vaccine, with one case receiving 0.6 mL on two lesions and the other receiving 1.2 mL on four lesions due to the extensive condition.³² Injections were performed every 2 weeks, and cryotherapy was also used in combination with immunotherapy to enhance efficacy and prevent recurrences after the third session of intralesional MMR. Rezai et al²⁸ achieved complete clearance after four sessions in case 1 and seven sessions in case 2.³² Another study performed an immunocompetence test before intervention using intradermal injection of 0.1 mL MMR vaccine on the forearm. The size of skin test reactivity was used to guide the volume of vaccine injected, including 0.3, 0.2, and 0.1 mL for indurations < 20 , 20–40, and > 40 mm, respectively. Treatment was given at a 2-week interval, and complete clearance was reported in 60.86% of patients.²⁸ In contrast, Mohta et al did not perform a pre-sensitization test, and patients were administered an intralesional injection of 0.2–0.3 mL MMR vaccine in the largest warts, with a 2-week interval and a maximum of four sessions. Complete clearance was observed in 87.8% of the patients.²⁶

In this study, the patient was administered an intralesional injection of 0.5 mL MMR vaccine into the largest warts every 3 weeks. This protocol was adapted from Sharma and Agarwal,²⁹ due to the similarity in the type of warts treated and the highest efficacy reported in their study compared to others. In addition, MMR vaccine is available in Indonesia as a 0.5 mL preparation per vial after reconstitution with the diluent. Based on the results, no response in either the size or number of lesions was observed after three treatment sessions. Although investigations on the dose, interval, and session of MMR for AGWs have not been previously conducted, the possibility of achieving better results with higher doses and more sessions, in combination with cryotherapy as previously used by Al-Qassabi et al³² cannot be excluded. In this patient, the treatment method used by Al-Qassabi et al was not used because the report aimed to evaluate the efficacy of MMR, and previous studies could not distinguish whether the response was due to MMR or cryotherapy.

The outcome of MMR vaccine as immunotherapy for AGWs can be affected by several factors including the active state of diseases, duration, and the history of sensitization, which includes but is not limited to previous vaccination, and broad-spectrum antibiotics. In a recent study by Mohta et al,²⁶ the complete response rate was significantly higher among subjects with the pseudo-Koebner phenomenon. A total of 13 out of 14 patients with this phenomenon showed a complete response, reflecting the active state of the disease. In patients with localized recalcitrant warts, only the local immune response is suppressed, while the levels of circulating antibodies against viral coat proteins are already in substantial amounts. Over time, such warts eventually develop resistance to these immune mechanisms and in this case, immunotherapy may not provide additional benefits. In contrast, individuals with actively disseminated warts have low levels of circulating antibodies, and the administration of immunotherapy may offer the immune response the necessary boost for clearance.²⁶ Based on the results, there was no pseudo-Koebner phenomenon observed in this patient. This might explain the less responsive lesions with a long-standing duration of five years. Sharma and Agarwal also reported a statistically significant difference across treatment responses in relation to the duration of the disease. In patients with complete clearance, the mean duration of disease was 4.7 ± 2.6 weeks, compared to 8.8 ± 4.6 weeks in those showing relative responses ($p = 0.014$).²⁹ Despite the insignificant association between treatment response and the baseline characteristics of participants observed across studies, increasing age was found to be associated with a weaker immunological response.³³ Successful intralesional antigen immunotherapy usually requires a strong host CMI.³⁰ In immunotherapy, the injection of antigen to which the patient was previously sensitized induced the elicitation phase of the immune response to recognize HPV antigens.³⁴ Although the previous vaccination status was not confirmed, evidence showed that the

patient was not previously sensitized to MMR. Investigations focused specifically on how individual race might affect the treatment outcome of MMR to AGWs have not been conducted. Lee et al reported that despite differences in epidemiology, genetics, and susceptibility, the treatment response rate of immunotherapy against cancer was comparable between Western and Asian patients.³⁵ According to Elkrief et al, a history of using broad-spectrum antibiotics can negatively impact the outcome of immunotherapy, through dysbiosis of gut microbiome, which alters systemic immune response. One study showed that a three-day course of broad-spectrum antibiotics led to a tenfold decrease in bacterial load and phylotype, with only partial recovery observed after four months.³⁶ The long-term use of non-steroid anti-inflammatory drugs has potentially positive effects on cancer, including those caused by HPV.^{37,38} The patient in this case had a history of “anti-inflammation” and “antibiotic”, for a week, one month ago. Although the anti-inflammation was less likely to affect the treatment outcome, the history of antibiotic use may have contributed to the results of immunotherapy.

Conclusion

In conclusion, immunotherapy using the MMR vaccine for AGWs treatment showed promising results in various studies. However, several factors should be considered when selecting the best candidate for this treatment to achieve optimal results.

Ethics Statement

The patient consented to the publication of images for this case study. Additionally, institutional approval was obtained for the publication of case details.

Consent Statement

The authors certify that they have obtained all appropriate patient consent forms. The patient signed a consent form for the publication of case details and images.

Acknowledgments

The authors are grateful to the staff of the Department of Dermatology and Venereology, Faculty of Medicine, Universitas Padjadjaran, Bandung, West Java, Indonesia.

Funding

There is no funding to report.

Disclosure

The authors declare that there are no conflicts of interest in this work.

References

1. Gilson R, Nugent D, Werner RN, Ballesteros J, Ross J. 2019 IUSTI-Europe guideline for the management of anogenital warts. *J Eur Acad Dermatol Venereol*. 2020;34(8):1644–1653. doi:10.1111/jdv.16522
2. Tyros G, Mastrafsi S, Gregoriou S, Nicolaidou E. Incidence of anogenital warts: epidemiological risk factors and real-life impact of human papillomavirus vaccination. *Int J STD AIDS*. 2021;32(1):4–13. doi:10.1177/0956462420958577
3. Diorio GJ, Giulano AR. The role of human papillomavirus in penile carcinogenesis and preneoplastic lesions a potential target for vaccination and treatment strategies. *Uro Clin North Am*. 2016;43(4):419–425. doi:10.1016/j.ucl.2016.06.003
4. Dillner J, Mijer CJ, Von Krogh G, Horenblas S. Epidemiology of human papillomavirus infection. *Scand J Urol Nephrol Suppl*. 2000;205:194–200. doi:10.1080/003655900750016580
5. Centers for Disease Control and Prevention. Sexually transmitted infections at a glance; 2021. Available from: <https://www.cdc.gov/std/statistics/prevalence-2020-at-a-glance.htm>. Accessed September 6, 2023.
6. Winer R, Koutsky L. Genital human papillomavirus infection. In: Dalam Holmes K, Sparling P, Stamm W, Piot P, Wasserheit J, Corey L, editors. *Sexually Transmitted Diseases*. New York: McGraw-Hill; 2008:489–501.
7. Patel H, Wagner M, Singhal P, Kothari S. Systematic review of the incidence and prevalence of genital warts. *BMC Infect Dis*. 2013;13:39. doi:10.1186/1471-2334-13-39
8. Vela S, Videla S, Ornelas A, et al. Effectiveness of physically ablative and pharmacological treatments for anal condyloma in HIV-infected men. *PLoS One*. 2018;13(8):e0199033. doi:10.1371/journal.pone.0199033
9. Hsu T, Nahmias ZP, Rosman IS, Sheinbein D. Extragenital condyloma acuminatum in the left axillary vault. *JAAD Case Rep*. 2018;4(9):947–949. doi:10.1016/j.jdcr.2018.07.022

10. Chen W, Sun H, Molijn A, et al. The variable characteristics of human papillomavirus in squamous cell carcinoma and adenocarcinoma of cervix in China. *J Low Genit Tract Dis*. 2018;22(4):355–361. doi:10.1097/LGT.0000000000000408
11. Kumar SD. Circumcision in genital warts—let us not forget. *Sex Transm Infect*. 2003;79(3):265. doi:10.1136/sti.79.3.265
12. Warkowski KA, Bolan GA. Sexually transmitted diseases treatment guidelines, 2015. *MMWR Recomm Rep*. 2015;64(RR-03):1–137.
13. Akhavan S, Mousavi A, Modaresgilani M, Alibakhshi A. Genital warts. *J Obstet Gynecol Cancer Res*. 2017;2(1):10–13.
14. Ju HJ, Park HR, Kim JY, Kim GM, Bae JM, Lee JH. Intralesional immunotherapy for non-genital warts: a systematic review and meta-analysis. *Indian J Dermatol Venereol Leprol*. 2022;88(6):724–737. doi:10.25259/IJDVL_1369_20
15. Freire MP, Pires D, Forjaz R, et al. Genital prevalence of HPV types and co-infection in men. *Int Braz J Urol*. 2014;40(1):67–71. doi:10.1590/S1677-5538.IBJU.2014.01.10
16. Egelkrout E, Galloway D. The biology of genital human papillomaviruses. In: Holmes K, Sparling P, Stamm W, Piot P, Wasserheit J, Corey L, editors. *Sexually Transmitted Diseases*. 4th ed. New York: McGraw-Hill; 2008:463–487.
17. Al-azmi H, Hanafy H. Human papillomavirus: manifestations, prevention and treatment: an overview. *Gulf J Dermatology Venereol*. 2012;19(1):1–28.
18. Fathi R, Tsoukas MM. Genital warts and other HPV infections: established and novel therapies. *Clin Dermatol*. 2014;32(2):299–306. doi:10.1016/j.clindermatol.2013.08.014
19. Googe P, Chung SJ, Simmons J, King R. Giant-sized condyloma of the breast with focal acantholytic changes. *J Cutan Pathol*. 2000;27(6):319–322. doi:10.1034/j.1600-0560.2000.027006319.x
20. Jovic A, Kocic H, Damiani G, et al. Unusual clinical presentation of giant extragenital condyloma. *Acta Dermatovenerologica Croat*. 2020;28(4):240–241.
21. Staples CG, Henderson D, Tsongalis GJ, Fernandez M, Krejci-Manwaring J. Condylomata of the pannus on 3 obese patients: a new location for a common disease. *Arch Dermatol*. 2010;146(5):572–574. doi:10.1001/archdermatol.2010.74
22. Workowski KA, Bachmann LH, Chan PA, et al. Sexually transmitted infections treatment guidelines, 2021. *MMWR Recomm Reports*. 2021;70(4):1.
23. Yanofsky VR, Patel RV, Goldenberg G. Genital warts: a comprehensive review. *J Clin Aesthet Dermatol*. 2012;5(6):25.
24. Thappa D, Chiramel M. Evolving role of immunotherapy in the treatment of refractory warts. *Indian Dermatol Online J*. 2016;7(5):364. doi:10.4103/2229-5178.190487
25. Sefcik RS, Burkhardt CG. Wart immunotherapies: a short review. *Open Dermatol J*. 2017;11(1):30–34. doi:10.2174/1874372201711010030
26. Mohta A, Kushwana R, Agrawal A, Sharma MK, Gautam U, Jain SK. Evaluation of the efficacy of intralesional measles, mumps, and rubella vaccine with intralesional vitamin D3 as immunotherapies in the treatment of recalcitrant cutaneous warts in adult - a randomized placebo-controlled study. *Indian Dermatol Online J*. 2022;12(6):879–887.
27. Rezk S, Alkady O, Farag R. The effect of intralesional injection of MMR in treatment of viral warts. *Benha J App Sci*. 2021;6(1):223–226. doi:10.21608/bjas.2021.169112
28. Sadegh Rezaei M, Ghasempouri H, Asqary Marzidareh O, Yazdani Cherati J, Rahmatpour Rokni G. Intralesional injection of the measles–mumps–rubella vaccine into resistant palmoplantar warts: a randomized controlled trial. *Iran J Med Sci*. 2019;44(1):10–17. doi:10.1002/path.4496
29. Sharma S, Agarwal S. Intralesional immunotherapy with measles mumps rubella vaccine for the treatment of anogenital warts: an open-label study. *J Clin Aesthet Dermatol*. 2020;13(8):40–44.
30. Meena D, Sharma S, Chauhan P. Measles, mumps, and rubella vaccine in genital warts: a case report of two patients. *Indian J Sex Transm Dis AIDS*. 2018;39(2):133–135. doi:10.4103/ijstd.IJSTD_44_16
31. Awal G, Kaur S. Therapeutic outcome of intralesional immunotherapy in cutaneous warts using the mumps, measles, rubella vaccine: a randomized, placebo-controlled trial. *J Clin Aesthet Dermatol*. 2018;11(5):15–20.
32. Al-Qassabi A-M, Al-Farsi F. Intralesional measles-mumps-rubella vaccine for genital warts. *Sultan Qaboos Univ Med J*. 2022;22(3):413–416. doi:10.18295/squmj.6.2021.093
33. Amiria M, Khodaeiani E, Fouladi DF, Masoudnia S. Intralesional immunotherapy with tuberculin purified protein derivative (PPD) in recalcitrant wart: a randomized, placebo-controlled, double-blind clinical trial including an extra group of candidates for cryotherapy. *J Dermatolog Treat*. 2016;27(2):173–178. doi:10.3109/09546634.2015.1078871
34. Mishra A, Shrestha SK, Karn D, Karn D. A prospective clinical study for safety and efficacy of intralesional tuberculin purified protein derivative in the treatment of palmoplantar verruca. *J Nobel Med Coll*. 2022;11(1):12–16. doi:10.3126/jonmc.v11i1.45720
35. Lee J, Sun JM, Lee SH, Ahn JS, Park K, Ahn MJ. Are there any ethnic differences in the efficacy and safety of immune checkpoint inhibitors for the treatment of lung cancer? *J Thorac Dis*. 2020;12(7):3796–3803. doi:10.21037/jtd.2019.08.29
36. Elkrief A, Derosa L, Kroemer G, Zitvogel L, Routy B. The negative impact of antibiotic on outcomes in cancer patients treated with immunotherapy: a new independent prognostic factor. *Ann Oncol*. 2019;30(10):1572–1579. doi:10.1093/annonc/mdz206
37. Rayburn ER, Ezell SJ, Zhang R. Anti-Inflammatory Agents for Cancer Therapy. *Mol Cell Pharmacol*. 2009;1(1):29–43. doi:10.4255/mcpharmacol.09.05
38. Garcia-Quiroz J, Vazquez-Almazan B, Garcia-Berrecia R, Diaz L, Avila E. The interaction of human papillomavirus infection and prostaglandin E2 signaling in carcinogenesis: a focus on cervical cancer therapeutic. *Cells*. 2002;11:2528. doi:10.3390/cells11162528

International Medical Case Reports Journal

Dovepress

Publish your work in this journal

The International Medical Case Reports Journal is an international, peer-reviewed open-access journal publishing original case reports from all medical specialties. Previously unpublished medical posters are also accepted relating to any area of clinical or preclinical science. Submissions should not normally exceed 2,000 words or 4 published pages including figures, diagrams and references. The manuscript management system is completely online and includes a very quick and fair peer-review system, which is all easy to use. Visit <http://www.dovepress.com/testimonials.php> to read real quotes from published authors.

Submit your manuscript here: <https://www.dovepress.com/international-medical-case-reports-journal-journal>