







Congenital Triangular Alopecia: A Case of Effective Response with 5% Topical Minoxidil in a Male Adolescent

Frizam Dwindamuldan Sutisna , Srie Prihianti Gondokaryono , Reiva Farah Dwiyanita ,
Raden Mohamad Rendy Ariezal Effendi , Nisrina Tache , Rafithia Anandita 

Department of Dermatology and Venereology, Faculty of Medicine, Universitas Padjadjaran, Hasan Sadikin Hospital, Bandung, Indonesia

Correspondence: Srie Prihianti Gondokaryono, Department of Dermatology and Venereology, Faculty of Medicine, Universitas Padjadjaran - Hasan Sadikin Hospital, Jl. Pasteur 38, Bandung, West Java, 40161, Indonesia, Tel +62 817114116, Email prihianti@gmail.com

Abstract: Congenital triangular alopecia (CTA) is a rare entity of non-cicatricial alopecia characterized by triangular or oval-shaped alopecia patches on the frontotemporal region of the scalp. Few therapeutic options exist, and there is currently no effective treatment except for hair transplantation. We report the case of an adolescent boy with CTA who was treated with 5% topical minoxidil solution. During therapy, the patient showed improvement in the form of the appearance of terminal hairs, which started to show after two months of treatment. After eight months of treatment, the affected area was fully covered with dense terminal hairs. The patient did not report any adverse reactions/side effects.

Keywords: Congenital triangular alopecia, minoxidil, trichoscopy

Introduction

Congenital triangular alopecia (CTA) is a rare disease characterized by the presence of a triangle or lancet-shaped area of hair loss.¹⁻⁴ The prevalence is 0.11% worldwide.^{1,4,5} In a 2020 report of 53 cases, most cases (58.8%) were detected in children between two and nine years old. About one-third of cases (36.5%) were detected at birth, while 3.8% were seen in adults.⁶ Currently, there is no effective treatment options for CTA.¹ However, one reported case of CTA successfully treated with 3% topical minoxidil in a 1-year-old child.⁷ This report will illustrate a case of CTA that gave a successful response with 5% topical minoxidil.

Case Report

A male adolescent aged 14 visited the Pediatric Dermatology Clinic in the Department of Dermatology and Venereology at Dr. Hasan Sadikin Hospital Bandung. He had a patch of alopecia on the right side of his scalp that had not progressed since birth. The patient's parents are opposed to their child receiving medical intervention. There was no evidence of perinatal injury or visible skin defects. The patient's parents were non-consanguineous with no family history of alopecia. The patient perceived that his grievances were only addressed throughout his adolescence. He had previously been diagnosed with alopecia areata (AA) by a dermatovenereologist and had received corticosteroid ointment therapy but with no improvement. As a result, he was referred to our hospital for further evaluation and management.

During the patient's physical examination, a well-defined triangular patch of alopecia was observed on the right frontotemporal scalp region, measuring 9 cm x 6 cm, with sparse hair growth. However, there was no evidence of inflammation, induration, or atrophy in the lesion (as depicted in [Figure 1A](#)). The trichoscopy examination indicated the existence of typical follicular openings with vellus hairs and the absence of exclamation mark hairs, broken hairs, tapering hairs, black dots, yellow dots, or orifice loss (as demonstrated in [Figure 2A](#)). According to the dermatology examination, the diagnosis of CTA was established.

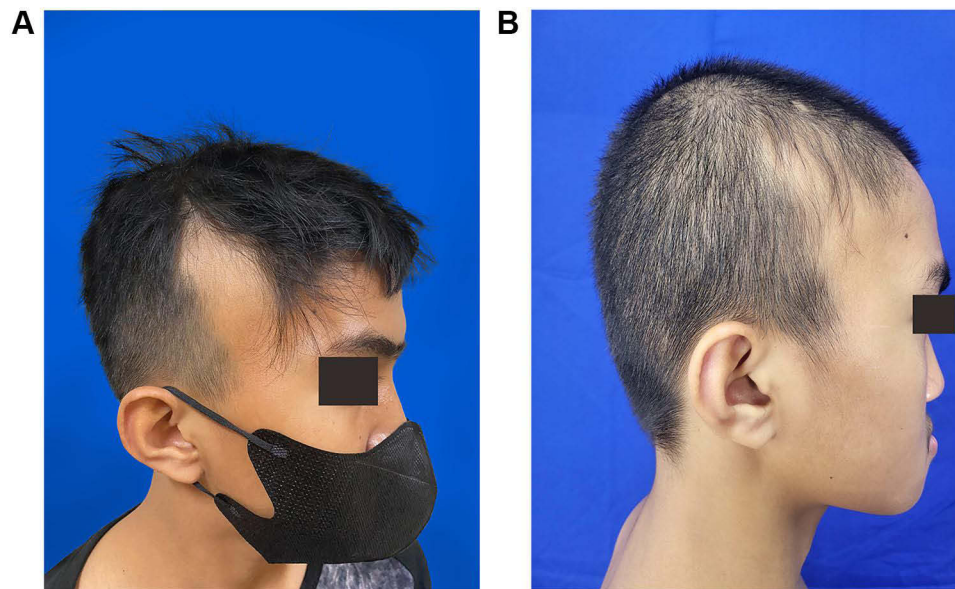


Figure 1 (A) Triangular patch of noncicatrical alopecia 9 cm x 6 cm over right frontotemporal scalp. (B) Growth of terminal hair in the lesion after 8th month of therapy.

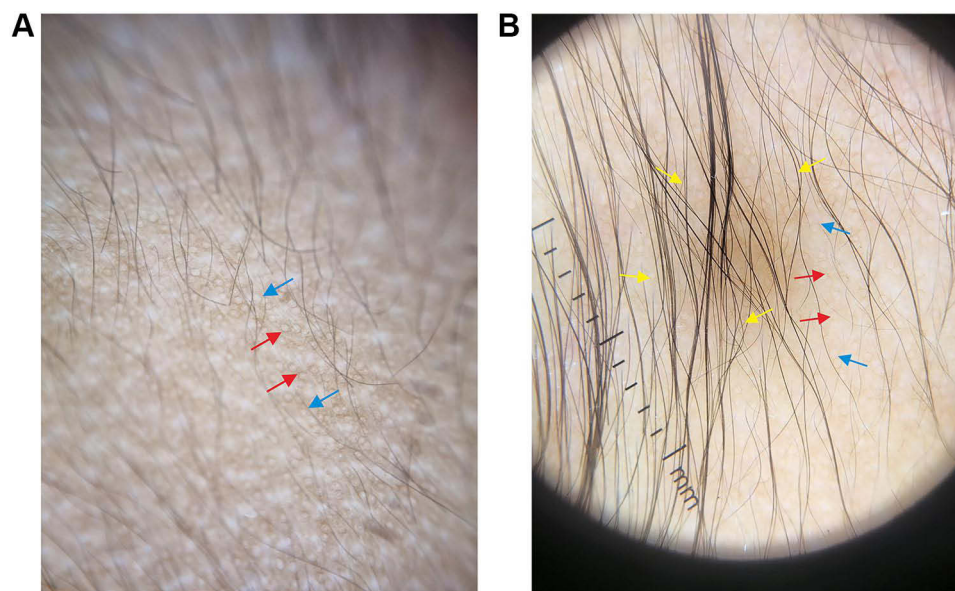


Figure 2 Trichoscopy finding (A) Short and thin vellus hair (blue arrow), and empty follicles (red arrow). (B) Vellus hair (blue arrow) surrounded by terminal hair (yellow arrow) and empty follicle (red arrow) after 8th month of therapy.

The patient was administered a 5% topical minoxidil solution as a monotherapy twice daily. After two months of therapy, terminal hairs began to appear. Additionally, after eight months, it was observed that the lesion had become covered with dense terminal hairs (as shown in Figure 1B). This observation was further supported by a trichoscopy examination, which indicated the presence of numerous new terminal hairs (as depicted in Figure 2B). Notably, the patient did not report experiencing any irritation or other adverse effects during the treatment.

Discussion

Congenital Triangular Alopecia is a relatively uncommon type of non-scarring hair loss that manifests as a triangular or lancet-shaped area of hair loss.^{1,2} Although the term “congenital” suggests that CTA is present at birth, most cases are not

apparent until later in childhood, typically between two and nine years of age. However, CTA can also manifest in adults. Diagnosis of CTA can be challenging, particularly in cases where the lesion is smaller or less distinct.^{1,5} In this particular case, the patient presented with CTA at birth, but the condition was not diagnosed until adolescence.

CTA is an uncommon condition that results in the loss of hair follicles and their replacement with scar tissue. It is known to be a stable condition throughout life,² with a prevalence of 0.11%.^{1,4,5} Unilateral hair loss is the most common presentation among CTA patients, while bilateral involvement is observed in several cases.¹ The frontotemporal and temporoparietal regions are the most commonly affected areas of CTA, although they can also occur in the occipital regions in 2.5% of cases. There is no gender preponderance.¹ In the current case, the clinical presentation of CTA exhibits the typical characteristics of a triangular shape, with it being unilateral and usually found in the frontotemporal region.

The etiology of CTA remains unclear; however, recent studies have provided compelling evidence for a process of miniaturization of the hair follicles resulting in the transformation of terminal hair into vellus hair, particularly in the affected region of the scalp during the initial year of a patient's life. The causative factor behind this permanent regression remains unidentified.^{1,8} Although CTA usually occurs sporadically, there have been some cases where it occurs in families, which could indicate mosaicism and inheritance as a predominant trait. This is because CTA is linked to postzygotic loss of the wild-type allele in a heterozygote state, which leads to the disease. Moreover, CTA has been found to be associated with several other conditions, including phakomatosis pigmentovascularis, Down Syndrome, Dandy–Walker malformation, intellectual disability, seizures, heart diseases, bone and tooth abnormalities, and multiple lentiginos.^{9,10} It is important to note that the patient in this report has no other diseases associated with CTA.

Clinical and trichoscopic characteristics of the condition can be used to establish the diagnosis of CTA, without the need for histopathologic examination.¹ Patients with CTA typically present with triangular or lancet-shaped temporal hair loss without any skin lesions or scarring, indicating an absence of identifiable etiological factors for hair loss in the affected region.¹ Trichoscopy is a useful diagnostic tool that can provide significant insights into the condition of hair follicles, including the presence of vellus hairs covering the area of alopecia and terminal hairs on the periphery of the lesion.^{1,5} The characteristic features observed in CTA under the microscope are the lack of fully developed hair follicles and the presence of vellus hairs, which can make the follicles appear smaller in size. Additionally, there are sporadic occurrences of terminal hair in the top layer of the skin but no indications of inflammation or scarring.^{2,6} The differential diagnosis of CTA includes AA, androgenetic alopecia (AGA), aplasia cutis, tinea capitis, tractional alopecia, and trichotillomania.^{1,6,10} It is worth noting that patients with a previous diagnosis and treatment for AA may show similar clinical symptoms to those with CTA and should be carefully evaluated.^{1,5,10} Overall, the combination of clinical and trichoscopic features can aid in the accurate diagnosis of CTA, leading to appropriate treatment and management of this condition.

Congenital triangular alopecia is diagnosed based on several criteria. These include the presence of a patch of hair loss on the frontotemporal region of the scalp, which has a triangular or lancet shape. On trichoscopic examination, there should be normal follicular openings with vellus hair surrounded by normal terminal hairs. Dermoscopy should not reveal any broken hair, yellow and black spots, dystrophic hair, or decreased follicular openings. Additionally, the condition should persist without significant hair regrowth for at least six months after confirming the presence of vellus hairs through a clinical assessment or trichoscopy. These criteria enable the diagnosis of CTA to be made without histopathological examination.^{1,11} In this instance, the individual being treated met the previously stated diagnostic criteria, which included the presence of a triangular-shaped alopecia patch located on the right frontotemporal region of the scalp. Upon examination using trichoscopy techniques, it was revealed that the follicular openings were normal, and there was the presence of vellus hair, an absence of broken hairs, and no yellow or black dots or dystrophic hair.

Congenital triangular alopecia is often asymptomatic and persistent throughout life.¹² It is considered a permanent condition that does not require treatment other than for cosmetic purposes.¹ There is no effective medical treatment for CTA, and patients should be informed of the benign nature of the disease.⁴ The cosmetic outcome of hair restoration surgery involving follicular unit transplantation or surgical excision may be satisfactory for some patients.^{1,4} In only a few instances is surgical excision of a tiny, localized region of alopecia feasible.^{1,4} Hair transplantation is an option for

psychologically distressed patients.^{1,4} The use of topical or intralesional corticosteroids to treat CTA has proven ineffective.^{1,13}

There are very few reports on the topical application of minoxidil for treating CTA.⁴ Bang et al reported a compelling case of transient improvement in a 1-year-old child treated with 3% topical minoxidil. The proliferation of terminal hair was observed. Unfortunately, hair regrowth was not sustained after treatment was discontinued.⁷ Pathania reported a 16-year-old boy with CTA who responded to 5% topical minoxidil.¹⁴ The patient had terminal hair growth in an alopecia region on the left frontotemporal scalp after four weeks of treatment. The effectiveness of 5% topical minoxidil solution was also seen in our patient, with initial hair growth after two months and new terminal hairs almost covering the lesion after eight months. This was confirmed further through trichoscopy assessment, which revealed an abundance of newly formed terminal hairs. The observation of new vellus and terminal hair in the CTA zone from minoxidil use corroborates it with the case of Bang et al,⁷ which supports the presence of medically salvageable hair follicles on the CTA.

Conclusion

Congenital triangular alopecia is a rare condition that may not be properly diagnosed or reported due to difficulties in differentiating it from other forms of nonscarring alopecia. Including CTA as a potential diagnosis may contribute to the avoidance of unnecessary therapy. This case suggests that topical administration of 5% minoxidil solution might potentially be an effective treatment for CTA in male adolescents, however, longer term treatment is required to indicate normalization of the alopecia area.

Ethics Statement

The publication of images were included in the patient's consent for publication of the case. Institutional approval has been obtained to publish the case details.

Consent Statement

The authors certify that they have obtained all appropriate patient consent forms. His parent provided written informed consent for the case details and images to be published.

Acknowledgments

The authors would like to thank the staff of the Department of Dermatology and Venereology, Faculty of Medicine, Universitas Padjadjaran, Bandung, West Java, Indonesia.

Funding

The authors declare that this study has received no financial support.

Disclosure

The authors report no conflicts of interest in this work.

References

1. Yin Li V, Yesudian P. Congenital triangular alopecia. *Int J Trichol.* 2015;7(2):48. doi:10.4103/0974-7753.160089
2. Jain SP, Bansode DS, Deshmukh A. Temporal triangular alopecia: a rare entity. *Clin Dermatol Rev.* 2023;7(1):87–88. doi:10.4103/cdr.cdr_51_21
3. Abuawad YG. Triangular temporal alopecia - Two Case reports, dermoscopy and review. *J Dermatol Cosmetol.* 2018;2(1):34–36. doi:10.15406/jdc.2018.02.00034
4. Viswanath V, Kalambe V, Sanap D. Congenital triangular alopecia: clinical and dermoscopic differentials. *Indian J Paediatr Dermatol.* 2019;20(1):75. doi:10.4103/ijpd.IJPD_57_18
5. Patel D, Tandel J, Nair P. Congenital triangular alopecia - A case report. *Int J Trichol.* 2020;12(2):89. doi:10.4103/ijt.ijt_4_20
6. Yamazaki M, Irisawa R, Tsuboi R. Temporal triangular alopecia and a review of 52 past cases. *J Dermatol.* 2010;37(4):360–362. doi:10.1111/j.1346-8138.2010.00817.x
7. Bang CY, Byun JW, Kang MJ, et al. Successful treatment of temporal triangular alopecia with topical minoxidil. *Ann Dermatol.* 2013;25(3):387. doi:10.5021/ad.2013.25.3.387
8. Gupta A, Khurana A, Malhotra P, Sardana K. Congenital triangular alopecia associated with phakomatosis pigmentovascularis type ii along with Klippel Trenaunay syndrome. *Indian Dermatol Online J.* 2020;11(1):91. doi:10.4103/idoj.IDOJ_112_19

9. Seol J, Jin W, Yun J, Kim H. An unusual case of congenital triangular alopecia on frontal area successfully treated by surgery. *Int J Trichol.* 2020;12(1):32. doi:10.4103/ijt.ijt_87_19
10. Starace M, Carpanese MA, Abbenante D, Bruni F, Piraccini BM, Alessandrini A. Atypical presentation of congenital triangular alopecia: a case series in Italy. *Dermatol Pract Concept.* 2020;e2020122. doi:10.5826/dpc.1004a122
11. Inui S, Nakajima T, Itami S. Temporal triangular alopecia: trichoscopic diagnosis. *J Dermatol.* 2012;39(6):572–574. doi:10.1111/j.1346-8138.2011.01348.x
12. Liang N, Cao Y. A case of temporal triangular alopecia in a Chinese child misdiagnosed with alopecia areata. *Int J Dermatol Venereol.* 2021;1. doi:10.1097/JD9.0000000000000210
13. Goldust M, Rahmatpour Rokni G, Sadr S, et al. Anterior, frontal congenital triangular alopecia, redundancy in therapy without improvement. *Dermatol Ther.* 2018;31(6):e12698. doi:10.1111/dth.12698
14. Pathania YS. Rapid response of topical minoxidil in congenital triangular alopecia. *Dermatol Ther.* 2020;33(3):e13371. doi:10.1111/dth.13371

Clinical, Cosmetic and Investigational Dermatology

Dovepress

Publish your work in this journal

Clinical, Cosmetic and Investigational Dermatology is an international, peer-reviewed, open access, online journal that focuses on the latest clinical and experimental research in all aspects of skin disease and cosmetic interventions. This journal is indexed on CAS. The manuscript management system is completely online and includes a very quick and fair peer-review system, which is all easy to use. Visit <http://www.dovepress.com/testimonials.php> to read real quotes from published authors.

Submit your manuscript here: <https://www.dovepress.com/clinical-cosmetic-and-investigational-dermatology-journal>