




# Infective Endocarditis Due to High-Level Gentamicin-Resistant *Enterococcus faecalis* Complicated Multisystemic Complications in an Elderly Patient

Kexin Tong <sup>1,\*</sup>, Huating Luo <sup>1,\*</sup>, Haifeng Dai<sup>2</sup>, Wenxiang Huang <sup>1</sup>

<sup>1</sup>Department of Geriatrics, The First Affiliated Hospital of Chongqing Medical University, Chongqing, 400016, People's Republic of China;

<sup>2</sup>Department of Infectious Diseases, The First Affiliated Hospital of Chongqing Medical University, Chongqing, 400016, People's Republic of China

\*These authors contributed equally to this work

Correspondence: Haifeng Dai, Department of Infectious Diseases, The First Affiliated Hospital of Chongqing Medical University, No. 1 Youyi Road, Yuzhong District, Chongqing, 400016, People's Republic of China, Tel +86 15123192435, Email [cqmudaihaifeng@163.com](mailto:cqmudaihaifeng@163.com); Wenxiang Huang, Department of Geriatrics, The First Affiliated Hospital of Chongqing Medical University, No. 1 Youyi Road, Yuzhong District, Chongqing, 400016, People's Republic of China, Tel +86 13883533808, Email [wenxiang\\_huang@163.com](mailto:wenxiang_huang@163.com)

**Abstract:** The escalating incidence of infective endocarditis (IE) caused by aminoglycoside-resistant *Enterococcus* is a growing concern for clinicians. This issue is particularly pronounced in elderly patients, who face an elevated risk of renal damage during antibiotic treatment, thereby limiting available pharmacological options. Furthermore, elderly patients often present with multiple comorbidities, leading to heightened mortality rates. In this article, we present a case involving an elderly male patient who sought medical attention on two separate occasions due to inflammation of the lower extremities and lumbosacral pain. Subsequent diagnosis revealed infective endocarditis (IE) caused by high-level gentamicin-resistant *Enterococcus faecalis* through blood culture and echocardiography. The patient also experienced peripheral and cerebral arterial embolism, secondary spine infection, and subsequent heart failure, highlighting the severity of the clinical situation. Following an initial 10-day course of vancomycin and ceftriaxone therapy, the patient developed renal impairment, necessitating a switch to bactericidal therapy with ampicillin in combination with ceftriaxone. Additionally, aortic valve replacement was performed during this period. Ultimately, the patient achieved clinical remission. This case underscores the critical importance of prompt and accurate diagnosis, appropriate antibiotic selection, and timely surgical intervention in enhancing the prognosis of elderly patients with IE.

**Keywords:** endocarditis, bacterial, *Enterococcus faecalis*, aminoglycoside resistance, ampicillin plus ceftriaxone, geriatrics

## Introduction

Infective endocarditis (IE) is a serious inflammatory condition that affects cardiac valves or endocardium, triggered by the invasion of pathogens such as bacteria, fungi, and atypical microorganisms like viruses and chlamydia. This disease is characterized by high mortality rates, the potential for complications affecting multiple systems, and generally carries a poor prognosis.<sup>1</sup> *Enterococcus faecalis*, a Gram-positive coccus that thrives in the human gut under anaerobic conditions, is the primary cause of enterococcal IE, particularly prevalent in the elderly population.<sup>2,3</sup> Traditionally, aminoglycoside-based therapies have been a mainstay in treating enterococcal IE. However, the rise of *Enterococcus faecalis* strains resistant to these antibiotics and the emergence of alternative agents with lower nephrotoxicity profiles have necessitated the development of new treatment strategies.<sup>3</sup> This article details the treatment journey of an elderly patient with IE infected with high-level gentamicin-resistant *Enterococcus faecalis*, who experienced complications including peripheral and cerebral arterial embolism, spinal infection, and heart failure. The aim is to offer valuable insights for managing IE caused by drug-resistant bacteria.

## Case Presentation

An 80-year-old patient was admitted to the First affiliated Hospital of Chongqing Medical University on May 10, 2023. The patient had been experiencing intermittent fever for the past 2 months, accompanied by chills, with a peak temperature reaching approximately 38°C. About a month prior to admission, the patient developed acute swelling in the left ankle, accompanied by persistent pain at rest. Upon evaluation, the patient was diagnosed with embolic occlusion of the posterior tibial artery along with cellulitis following comprehensive blood routine and lower limb ultrasound examinations. Subsequently, a regimen of ceftriaxone and benzylpenicillin anti-infective treatments was initiated to address the lower limb swelling, albeit with limited success in alleviating the intermittent fever. Four days prior to admission, the patient experienced sudden-onset pain in the lumbosacral region, although no sensory or motor abnormalities were noted. The patient's medical history revealed a longstanding hypertension condition spanning over 30 years, which had been effectively managed with appropriate antihypertensive medications, maintaining blood pressure consistently within the target range. There were no significant personal or familial medical histories reported.

On the day of admission, the patient presented with acute fine motor deficits affecting the right upper extremity along with speech impairment. Despite these neurological symptoms, vital signs remained stable, with a heart rate of 61 beats per minute. Upon physical examination, mitral systolic and aortic diastolic murmurs were detected. Notably, percussion of the lumbosacral spine elicited significant pain. Additionally, mild erythema and swelling were noted in the left ankle. Skin examination revealed an absence of petechiae, linear hemorrhage under the nails, or Janeway lesions. The neurological assessment indicated clear consciousness with mild motor aphasia. Facial and nasolabial folds appeared symmetrically intact, and the tongue position was centralized. Limb muscle strength was graded as V, with symmetrical injury perception and negative pathological reflexes. The National Institutes of Health Stroke Scale (NIHSS) score was calculated at one.

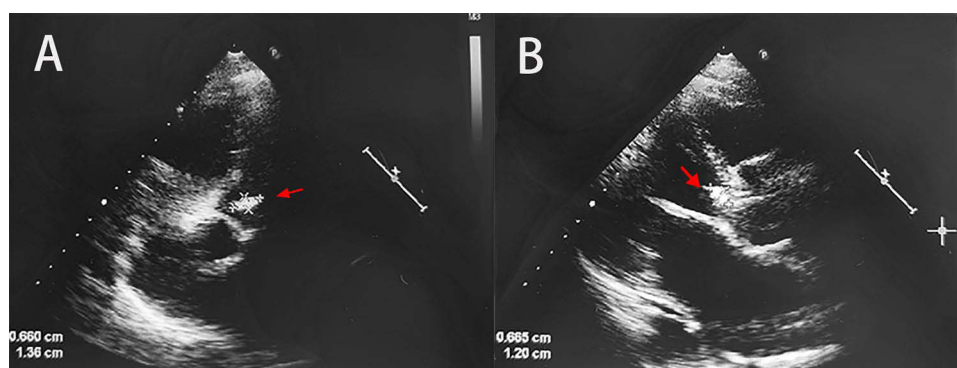
Laboratory tests and imaging results revealed pertinent findings: the blood routine indicated a decreased hemoglobin level of 73.0g/L, an elevated total leukocyte count of  $7.45 \times 10^9/L$ , and an increased neutrophil percentage of 82.5%. C-reactive protein levels were notably elevated at 103.00mg/L, alongside an accelerated hematological sedimentation rate of 81mm/h. Droplet Digital PCR (ddPCR) testing unveiled elevated counts of *Enterococcus* spp. at 3151.75 Copies/mL and *Streptococcus* spp. at 209.00 Copies/mL (Table 1). The cardiac ultrasound examination revealed a moderately echogenic mass measuring approximately 1.38 cm  $\times$  0.6 cm on the aortic valve, suggestive of vegetation. There was a prolapse on the right coronary surface of the aortic valve with perforation (measuring approximately 2.5 mm) and severe aortic valve regurgitation. The anterior portion of the mitral valve was rough (indicating vegetation), and there was severe mitral valve regurgitation. Left atrial and left ventricular enlargement were observed (LA 40 mm, LV 60 mm, LVEF 52%) (Figure 1). Lower limb arterial ultrasound confirmed occlusion of the posterior tibial artery. However, chest CT plain scan did not reveal any significant abnormalities. Cephalic Diffusion Weighted Imaging (DWI) demonstrated left acute cerebral infarction. MRI scan of the lumbar spine indicated slight herniation of the lumbar 2–3 and 3–4 discs, inflammation of the lumbar interspinous ligament, and mild swelling of the erector spinae muscle.

Combined with the patient's recurrent fever, blood ddPCR test and blood culture suggesting *Enterococcus faecalis* infection, cardiac ultrasound suggesting valvular vegetation and perforation, as well as lower limb and cerebral vascular embolism phenomenon, according to Duke diagnostic criteria (2023),<sup>4</sup> it can be diagnosed as infective endocarditis (IE).

**Table 1** Droplet Digital PCR\*

Time	Pathogen	Results (Copies/mL)	Reference Range
2023-05-11	<i>Enterococcus</i> spp.	3151.75	<45
	<i>Streptococcus</i> spp.	209.00	<45
2023-05-20	<i>Enterococcus</i> spp.	429.70	<45
2023-06-11	Negative	<45	<45
2023-06-19	Negative	<45	<45

**Notes:** \*Including *Pseudomonas aeruginosa*, *Enterobacter cloacae*, *Klebsiella*, *Escherichia coli*, *Acinetobacter baumannii*, *Staphylococcus aureus*, Coagulase-negative staphylococci (CoNS), *Enterococcus* spp., *Streptococcus*, and *Candida* spp.



**Figure 1** Cardiac Ultrasound imaging. An echogenic mass measuring approximately 1.38 cm × 0.6 cm with moderate to strong echogenicity was identified on the left ventricular aspect of the right coronary cusp of the aortic valve (arrow). (A) Still frame of two dimensional echocardiogram in parasternal long axis view showing a vegetation on aortic valve (arrow) (B).

Considering that the patient was a senior with severe sepsis and suspected intracranial infection, vancomycin 1g q12h combined with ceftriaxone 2g q12h was selected for intravenous drip anti-infection, and vancomycin blood concentration was monitored at the same time. After 10 days of anti-infective treatment, the patient developed renal impairment (Serum creatinine increased from the normal value on admission to 132  $\mu\text{mol/L}$ ) and vancomycin blood concentration exceeded the standard (peak concentration: 27.02 mg/L). It suggested an adverse reaction of renal impairment of vancomycin, so in combination with the patient's blood culture suggesting high levels of gentamicin-resistant *Enterococcus faecalis* infection (Table 2), the anti-infective regimen was adjusted to ampicillin 3g q6h in combination with ceftriaxone 2g q12h for anti-infective treatment according to drug sensitivity tests and clinical guidelines.<sup>5</sup>

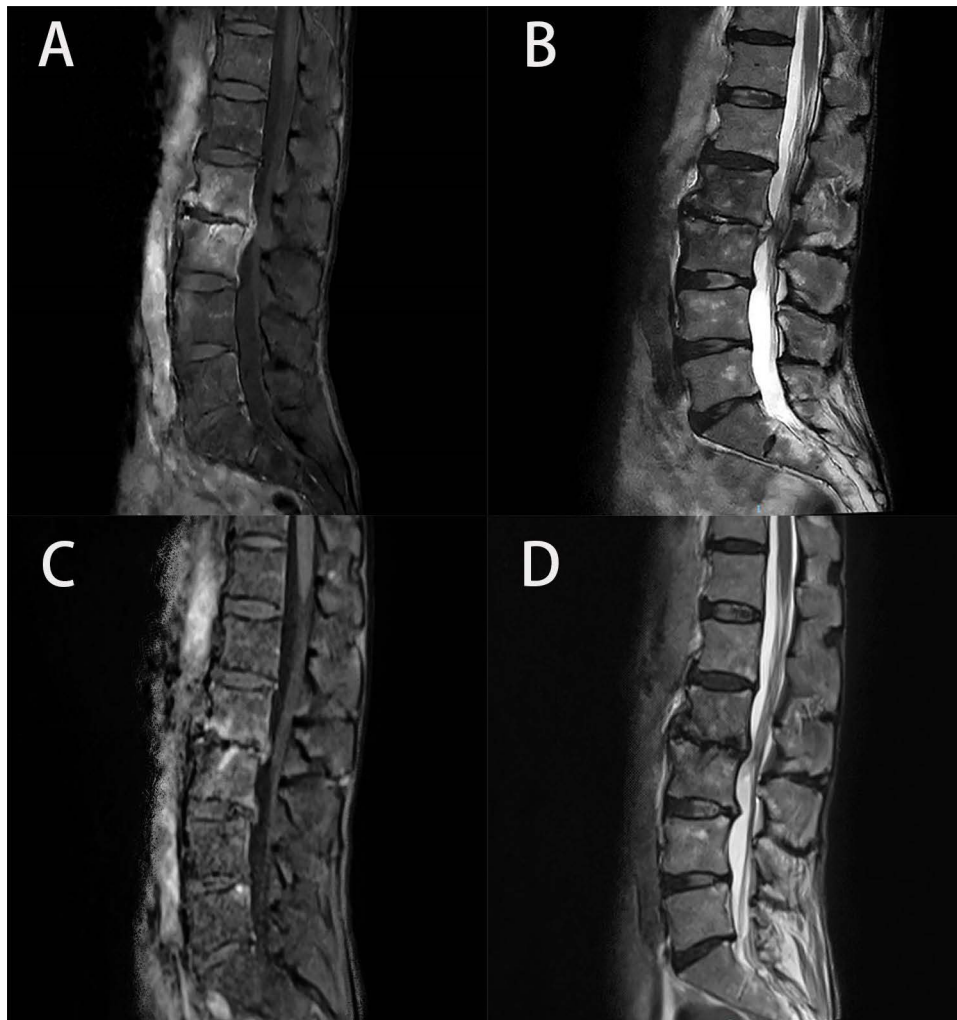
During the course of the illness, the patient experienced dyspnea and respiratory distress, accompanied by wet rales detected in both lung fields. An acute episode of heart failure was diagnosed, prompting initiation of treatment with recombinant human brain natriuretic peptide via micro-pump infusion, along with oral administration of sacubitril valsartan, furosemide, and spironolactone, effectively resolving the symptoms of heart failure.<sup>6</sup> Given the presence of significant vegetation in heart valves and recurrent acute heart failure episodes warranting surgical intervention, the patient underwent aortic valve replacement, mitral valvuloplasty, and temporary epicardial pacemaker placement under

**Table 2** Culture Results

Time	Samples	Pathogen	Antibiotics	MIC	Antibiotic Sensitivity Testing
2023-05-11	Blood	<i>Enterococcus faecalis</i>	Ampicillin Clindamycin Daptomycin Erythromycin Gentamycin Linezolid Levofloxacin Moxifloxacin Penicillin Cotrimoxazole Ticoranic Tigecycline Vancomycin	$\leq 2$ – 4 $\geq 8$ SYN-R 2 1 $\leq 0.25$ 2 – $\leq 0.5$ $\leq 0.12$ 1	Susceptible Resistant Intermediate Resistant High-level gentamicin resistant Susceptible Susceptible Susceptible Susceptible Resistant Susceptible Susceptible Susceptible
2023-05-30	Tissue samples excised of cardiac valves	<i>Enterococcus faecalis</i>	Drug sensitivity test result was the same as 2023-05-11 blood culture		
2023-06-06	Blood	Negative	–	–	–
2023-06-11	Blood	Negative	–	–	–

extracorporeal circulation, following a 3-week course of anti-infective therapy. Postoperative assessment revealed a reduction in valve vegetation, and subsequent cardiac ultrasound examination indicated satisfactory bioprosthetic valve function, with tissue culture confirming *Enterococcus faecalis* infection (Table 2). Anti-infective therapy with ampicillin in combination with ceftriaxone was continued at the same dosage postoperatively to address the infection. The patient's cerebral arterial embolus was identified as small, with mild neurological symptoms. Following evaluation by a neurologist, it was determined that thrombolytic therapy was unnecessary. Guided by recommendations advocating anti-infective therapy in cases of infective endocarditis (IE) accompanied by embolism,<sup>1</sup> the patient received solely anti-infective treatment, leading to subsequent improvement in neurological symptoms.

After a month of uninterrupted antimicrobial therapy, the patient reported exacerbating low back pain without accompanying fever. Magnetic resonance imaging (MRI) of the lumbar spine revealed potential infection involving the L2 and L3 vertebral bodies and discs (Figure 2), indicative of infectious spondylitis attributed to bacterial embolic dissemination. Therapy comprising ampicillin and ceftriaxone was continued to address the infection. By day 75 of antimicrobial treatment, which marked 8 weeks postoperatively, the patient experienced significant alleviation of lumbar discomfort. Concurrently, inflammatory markers normalized, and both blood cultures and ddPCR tests returned negative



**Figure 2** Comparison of lumbar spine MRI enhancement before and after treatment. The lumbar spine MRI at admission: The L2 and L3 vertebrae exhibit high signal intensity on T1WI fat-suppressed sequences and mixed signal intensity on T2WI, predominantly isointense to slightly hyperintense, with localized erosion and destruction of the bone margin. The post-contrast scan shows significant enhancement, with a few increased strip-like isointense signal abnormalities on the posterior margin, markedly enhanced, suggesting the possibility of an infectious lesion (A and B). The lumbar spine MRI one month post-treatment: The L2 and L3 vertebrae show patchy high signal intensity on T1WI fat-suppressed sequences, and mixed high and low signal intensity on T2WI, with localized erosion and destruction of the bone margin. The post-contrast scan reveals heterogeneous enhancement (C and D).

results, signifying successful eradication of the infection (as illustrated in Tables 1 and 2). Follow-up imaging corroborated clinical improvement, demonstrating substantial resolution of vertebral body and disc infection (Figure 2). Consequently, owing to the favorable response to treatment, the patient was discharged with notable improvement. During a subsequent clinic visit one month post-discharge, the patient remained afebrile, and lumbar MRI exhibited a marked reduction in the previously identified spinal lesion.

## Discussion

Elderly patients with IE often exhibit atypical clinical presentations and frequently yield negative blood cultures, complicating early detection and portending a heightened risk of complications and a grim prognosis.<sup>7</sup> Advanced age and comorbidities serve as significant predictors of mortality in individuals afflicted with infective endocarditis (IE).<sup>8</sup> Clinical manifestations of IE vary widely, with approximately 83.9% of patients experiencing fever, and 27.1% suffering embolic events upon diagnosis.<sup>9</sup> Arterial embolism resulting from bacterial vegetation detachment poses a grave hazard for IE patients,<sup>1</sup> thereby necessitating a high index of suspicion in individuals presenting with fever and signs suggestive of peripheral arterial embolism. Spinal infection, though rare, represents a severe complication of IE. The presence of a spinal abscess can significantly protract the requisite treatment duration,<sup>10</sup> underscoring the importance of considering IE in patients presenting with fever and back pain, particularly when imaging studies hint at spinal involvement. In this instance, the patient—an elderly individual—exhibited atypical clinical features, and IE was not initially considered when presenting with lower limb cellulitis. Consequently, further investigations such as echocardiography and blood cultures were deferred, leading to delayed diagnosis and treatment initiation. Subsequent hospitalization occurred only when the patient suffered low back pain caused by a spinal infection. Upon admission, a heart valve murmur was detected during examination, prompting further refinement of cardiac echocardiography and blood culture analysis, ultimately confirming the diagnosis of IE. Additionally, heightened levels of gentamicin-resistant *Enterococcus faecalis* infection and multisystem complications exacerbated the patient's critical condition, rendering treatment more challenging. Nevertheless, clinical recovery was achieved through timely and appropriate antibiotic therapy coupled with heart valve surgery. This underscores the imperative of early diagnosis and intervention to ameliorate the prognosis of elderly patients with IE.

*Enterococcus faecalis*, a facultatively anaerobic Gram-positive coccus, is a common inhabitant of the human gastrointestinal flora and is implicated in over 90% of enterococcal IE cases, predominantly afflicting the geriatric population.<sup>2,3</sup> The management of IE attributed to high-level aminoglycoside-resistant strains of *Enterococcus faecalis* poses a significant clinical challenge. The 2015 guidelines from the European Society of Cardiology (ESC) advocate for an extended duration of anti-infective treatment for enterococcal IE, typically six weeks. Recommended therapeutic approaches include dual cell wall inhibitor combinations, such as ampicillin plus ceftriaxone (AC), which exhibit synergistic inhibition of penicillin-binding proteins, or a cell wall inhibitor paired with an aminoglycoside, exemplified by ampicillin plus gentamicin (AG), to achieve synergistic bactericidal activity.<sup>1</sup> It is important to note that while AC and AG regimens demonstrate similar efficacy against *E. faecalis*-induced IE, the former is associated with a significantly lower risk of inducing renal impairment.<sup>11</sup> Consequently, the AC regimen has gained prominence as an optimal treatment strategy for *E. faecalis* strains exhibiting high-level gentamicin resistance and is favored for patients with compromised renal function. In the present case, the isolated *Enterococcus faecalis* strain exhibited high-level resistance to gentamicin. Therefore, in light of the patient's renal dysfunction post-vancomycin treatment and elevated drug serum levels, a bactericidal combination of ampicillin and ceftriaxone was employed.

Valve replacement surgery constitutes a pivotal therapeutic approach for managing IE, with the timing of surgical intervention remaining a critical clinical decision. The guidelines from 2015 ESC and 2016 The American Association for Thoracic Surgery (AATS) cite several indications for valve replacement surgery: (1) Heart failure, significant regurgitation or obstruction leading to cardiogenic shock; (2) Infections that are difficult to control with appropriate antibiotic therapy, secondary infections at other sites, or valves with perforative lesions; (3) Valvular vegetations exceeding 10mm in diameter, with recurrent embolic events and persistent vegetations despite antimicrobial treatment.<sup>1,12</sup> Valve replacement has been demonstrably associated with a reduction in mortality rates among patients with IE,<sup>13</sup> and barring severe concurrent complications, surgical indications persist even in cases presenting with cardiogenic shock.<sup>1</sup> In the case under discussion, the patient presented with arterial embolism, an episode of acute



heart failure, and an infection attributable to a strain of drug-resistant *Enterococcus faecalis*, collectively signifying the need for early surgical resolution. Nevertheless, the patient's advanced age and suboptimal physical condition elevated the risk associated with surgical procedures. Consequently, after a three-week course of antimicrobial therapy and supportive care that resulted in a downward trend in infection markers and an improvement in anemia, a decision was made to proceed with heart valve replacement. This strategic approach culminated in a favorable clinical outcome.

## Conclusion

In summary, the utilization of ampicillin in conjunction with ceftriaxone for the treatment of high-level Gentamicin-resistant *Enterococcus faecalis* infections in the elderly can yield favorable antimicrobial outcomes while mitigating the risk of renal damage. Elderly patients with IE often exhibit atypical clinical presentations, are susceptible to multi-systemic complications, and are at an elevated risk for misdiagnosis or underdiagnosis. The presence of fever accompanied by arterial embolism or systemic infections should prompt consideration of IE, necessitating the timely completion of blood cultures and echocardiographic evaluations to facilitate the early diagnosis of IE. Timely and accurate diagnosis, coupled with the selection of appropriate antibiotics and surgical interventions, is essential to prevent the progression to unmanageable embolic events and extracardiac infections, thereby improving patient prognosis.

## Ethics Approval and Consent to Participate

The study was conducted according to the guidelines of the Declaration of Helsinki and approved by The First Affiliated Hospital of Chongqing Medical University.

## Informed Consent Statement

Written informed consent was obtained from the individual for the publication of any potentially identifiable images or data included in this article.

## Author Contributions

All authors made a significant contribution to the work reported, whether that is in the conception, study design, execution, acquisition of data, analysis and interpretation, or in all these areas; took part in drafting, revising or critically reviewing the article; gave final approval of the version to be published; have agreed on the journal to which the article has been submitted; and agree to be accountable for all aspects of the work.

## Funding

This study was supported by Chongqing Medical Key Discipline and Regional Medical Key Discipline Development Project (No. 0201(2023) No.160 202412).

## Disclosure

The authors declare no conflict of interest.

---

## References

1. Habib G, Lancellotti P, Antunes MJ, The 2015 ESC guidelines for the management of infective endocarditis. *Eur Heart J*. 2015;36(44):3036–3037. doi:10.1093/eurheartj/ehv488
2. Chirouze C, Athan E, Alla F, et al. Enterococcal endocarditis in the beginning of the 21st century: analysis from the international collaboration on endocarditis-prospective cohort study. *Clin Microbiol Infect*. 2013;19(12):1140–1147. doi:10.1111/1469-0691.12166
3. Baddour LM, Wilson WR, Bayer AS, et al. Infective endocarditis in adults: diagnosis, antimicrobial therapy, and management of complications: a scientific statement for healthcare professionals from the American Heart Association. *Circulation*. 2015;132(15):1435–1486. doi:10.1161/CIR.0000000000000296
4. Fowler VG, Durack DT, Selton-Suty C, et al. The 2023 duke-international society for cardiovascular infectious diseases criteria for infective endocarditis: updating the modified duke criteria. *Clin Infect Dis*. 2023;77(4):518–526. doi:10.1093/cid/ciad271
5. Leone S, Noviello S, Esposito S. Combination antibiotic therapy for the treatment of infective endocarditis due to enterococci. *Infection*. 2016;44(3):273–281. doi:10.1007/s15010-015-0836-0

6. Heart Failure Group of Chinese Society of Cardiology of Chinese Medical Association, Chinese Heart Failure Association of Chinese Medical Doctor Association, Editorial Board of Chinese Journal of Cardiology [Chinese guidelines for the diagnosis and treatment of heart failure 2018]. *Zhonghua xin xue guan bing za zhi*. 2018, ;46(10):760–789. Chinese. doi:10.3760/cma.j.issn.0253-3758.2018.10.004
7. Bea C, Vela S, Garcia-Blas S, et al. Infective endocarditis in the elderly: challenges and strategies. *J Cardiovasc Develop Dis*. 2022;9(6). doi:10.3390/jcdd9060192
8. Li HL, Tromp J, Teramoto K, et al. Temporal trends and patterns of infective endocarditis in a Chinese population: a territory-wide study in Hong Kong (2002–2019). *Lancet Region Health Western Pacific*. 2022;22:100417. doi:10.1016/j.lanwpc.2022.100417
9. Urina-Jassir M, Jaimes-Reyes MA, Martinez-Vernaza S, et al. Clinical, microbiological, and imaging characteristics of infective endocarditis in latin america: a systematic review. *Inter J Infect Dis*. 2022;117:312–321. doi:10.1016/j.ijid.2022.02.022
10. Oh JS, Shim JJ, Lee KS, et al. Cervical epidural abscess: rare complication of bacterial endocarditis with streptococcus viridans: a case report. *Korean J Spine*. 2015;12(1):22–25. doi:10.14245/kjs.2015.12.1.22
11. Fernández-Hidalgo N, Almirante B, Gavalda J, et al. Ampicillin plus ceftriaxone is as effective as ampicillin plus gentamicin for treating enterococcus faecalis infective endocarditis. *Clin Infect Dis*. 2013;56(9):1261–1268. doi:10.1093/cid/cit052
12. Pettersson GB, Coselli JS, Pettersson GB, et al. 2016 The American Association for Thoracic Surgery (AATS) consensus guidelines: surgical treatment of infective endocarditis: executive summary. *J Thoracic Cardiovasc Surg*. 2017;153(6):1241–1258.e1229. doi:10.1016/j.jtcvs.2016.09.093
13. Kiefer T, Park L, Tribouilloy C, et al. Association between valvular surgery and mortality among patients with infective endocarditis complicated by heart failure. *JAMA*. 2011;306(20):2239–2247. doi:10.1001/jama.2011.1701

## Infection and Drug Resistance

Dovepress

### Publish your work in this journal

Infection and Drug Resistance is an international, peer-reviewed open-access journal that focuses on the optimal treatment of infection (bacterial, fungal and viral) and the development and institution of preventive strategies to minimize the development and spread of resistance. The journal is specifically concerned with the epidemiology of antibiotic resistance and the mechanisms of resistance development and diffusion in both hospitals and the community. The manuscript management system is completely online and includes a very quick and fair peer-review system, which is all easy to use. Visit <http://www.dovepress.com/testimonials.php> to read real quotes from published authors.

Submit your manuscript here: <https://www.dovepress.com/infection-and-drug-resistance-journal>